

# **Internal Trapping Following Proximal Clipping for a Ruptured Partially Thrombosed Giant Aneurysm of the Vertebral Artery**

## **—Case Report—**

Yuzo TERAOKAWA, Akinori YAMAMURA\*, Naoaki MURAYAMA\*,  
Hitomi KIMURA\*\*, Toshio NAKAGAWA\*, Masahito FUJISHIGE\*,  
Katsuyuki NUNOMURA\*, Daisuke OGAWA\*\*\*, and Kazuo HASHI\*

*Department of Neurosurgery, Osaka City University Graduate School of Medicine, Osaka;*

*Departments of \*Neurosurgery and \*\*Anesthesiology,*

*Shinsapporo Neurosurgical Hospital, Sapporo, Hokkaido;*

*\*\*\*Department of Neurological Surgery, Faculty of Medicine, Kagawa University, Kagawa*

### **Abstract**

**A 52-year-old woman presented with a partially thrombosed giant aneurysm of the vertebral artery (VA) manifesting as a 3-month history of left hemiparesis. She developed subarachnoid hemorrhage during hospitalization and underwent emergency surgery for surgical proximal clipping and ventricular drainage with decompressive suboccipital craniectomy. She underwent additional surgery for endovascular coil embolization of the aneurysm and the affected distal VA on the 7th postoperative day. Although she suffered transient lower cranial nerve pareses and respiratory failure, her neurological condition improved gradually and she returned home with only slight ataxia and hoarseness 3 months after surgery. Magnetic resonance imaging obtained 28 months postoperatively revealed a remarkable decrease in the size of the aneurysm as well as reduction of the mass effect on the brainstem. Combined proximal clipping and internal trapping can solve the problems associated with treatment of giant aneurysms of VA by either direct surgery or endovascular surgery, and should be considered as a therapeutic option for giant aneurysms of the VA.**

Key words: giant aneurysm, vertebral artery, proximal clipping, endovascular trapping, subarachnoid hemorrhage

### **Introduction**

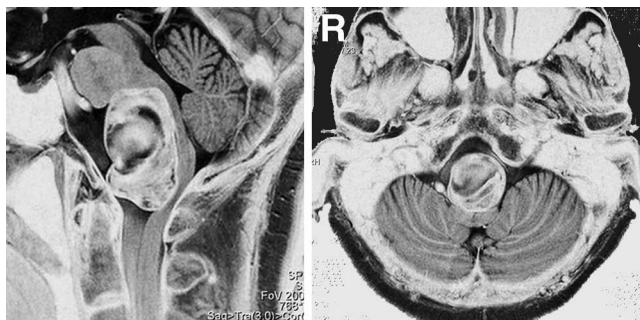
Symptomatic giant cerebral aneurysms tend to have extremely grave clinical presentations<sup>2-4</sup> and are candidates for aggressive neurosurgical treatment. However, direct surgery for a giant aneurysm of the vertebral artery (VA) remains challenging, because of a number of factors, such as size and location of the aneurysm, the presence of calcification or atherosclerosis within the neck of the aneurysm, the coexistence of intraaneurysmal thrombosis, and the necessity for bypass surgery. Recently, endovascular surgery has been used as an alternative form of treatment for giant aneurysms, but high rates of incomplete occlusion or recanalization of aneurysms have been reported with only endosaccular emboli-

zation<sup>3,5,14</sup> or proximal coiling of the parent artery.<sup>10</sup>

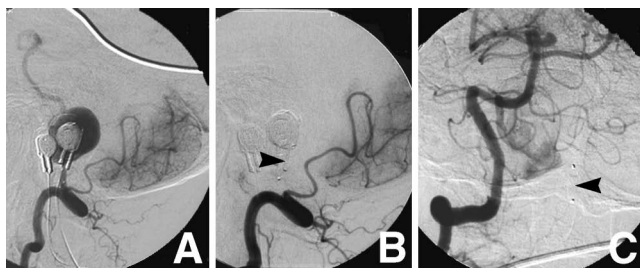
Here we present a case of a partially thrombosed giant VA aneurysm manifesting as a mass effect on the brainstem followed by subarachnoid hemorrhage, which was treated successfully by combined surgical proximal clipping and internal trapping of the VA.

### **Case Report**

A 52-year-old woman presented at our outpatient department with a 3-month history of left hemiparesis. Her past history was unremarkable. Neurological examination on admission revealed slight left hemiparesis (manual muscle test 4/5) and truncal ataxia. Magnetic resonance (MR) imaging on admission indicated a huge mass lesion, 44 mm in maximum diameter, in the posterior fossa compressing

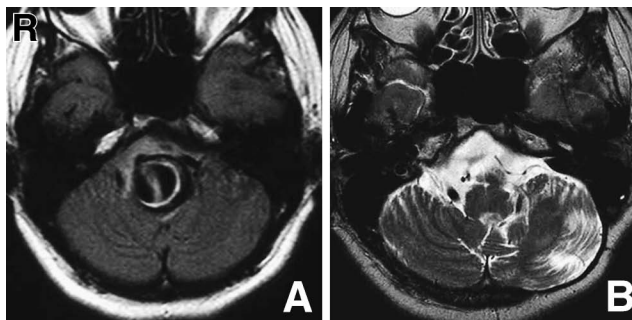


**Fig. 1** Sagittal (left) and axial (right) T<sub>2</sub>-weighted reverse magnetic resonance images obtained on admission demonstrating a huge mass lesion compressing the brainstem posteriorly. This mass lesion was largely thrombosed but incorporated flow void signals.



**Fig. 2** **A:** Left vertebral angiogram demonstrating a giant aneurysm located distal to the posterior inferior cerebellar artery (PICA). Much of the aneurysm was not visualized due to intraaneurysmal thrombosis. **B:** Left vertebral angiogram during balloon test occlusion (BTO) under neurological monitoring and auditory brainstem response recording showing the balloon (arrowhead) inflated at the distal site of the PICA. **C:** Right vertebral angiogram obtained during the BTO showing retrograde filling of the aneurysm through the distal side of the vertebral artery, and the inflated balloon (arrowhead) in the left vertebral artery.

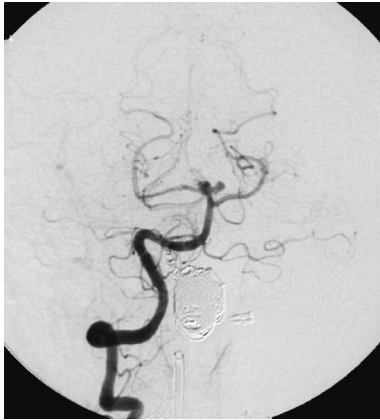the brainstem posteriorly. Both T<sub>1</sub>- and T<sub>2</sub>-weighted MR imaging showed the mass lesion as mixed intensity with an internal flow void, suggestive of a partially thrombosed aneurysm. T<sub>2</sub>-weighted reverse MR imaging clearly demonstrated the contents of the aneurysm, and the relationship between the aneurysm and the adjacent neural structures (Fig. 1). Diagnostic cerebral angiography demonstrated a giant aneurysm of the left VA located distal to the posterior inferior cerebellar artery (PICA) (Fig. 2A) as well as two small aneurysms of the basilar artery.



**Fig. 3** **A:** Fluid-attenuated inversion recovery magnetic resonance (MR) image obtained immediately after deterioration demonstrating subarachnoid hemorrhage localized in the cerebellomedullary cistern. **B:** T<sub>2</sub>-weighted MR image obtained about 28 months after endovascular surgery showing a remarkable decrease in the size of the aneurysm as well as reduction of the mass effect on the brainstem.

Balloon test occlusion (BTO) with neurological monitoring and auditory brainstem response recording was performed for 20 minutes with the patient conscious. The BTO was tolerated if the balloon was preferably positioned distal to the PICA, but right vertebral angiography obtained during inflation of the balloon showed weak retrograde filling of the aneurysm via the VA union (Fig. 2B, C).

Direct surgery including trapping of the aneurysm and aneurysmectomy was scheduled under a diagnosis of partially thrombosed giant aneurysm of the left VA. However, 5 days prior to surgery, the patient suffered sudden onset of severe headache followed by consciousness disturbance (Japan Coma Scale II-10, Glasgow Coma Scale 14) and deterioration of the preexisting left hemiparesis (manual muscle test 2/5). Fluid-attenuated inversion recovery MR imaging obtained immediately after the onset of these symptoms demonstrated subarachnoid hemorrhage localized in the cerebellomedullary cistern (Fig. 3A) associated with hydrocephalus. Accordingly, the patient underwent emergency surgery for proximal clipping of the left VA just distal to the PICA through a lateral suboccipital retrosigmoid approach and ventricular drainage via the posterior horn. Decompressive suboccipital craniectomy was also performed, because the posterior fossa was found to be tense and tight intraoperatively even after ventricular drainage. Five days later, the patient underwent tracheostomy as she had developed lower cranial nerve pareses and respiratory failure after the onset of subarachnoid hemorrhage. On the 7th day, the patient underwent second sur-



**Fig. 4** Follow-up right vertebral angiogram obtained 6 weeks after surgery demonstrating complete obliteration of the aneurysm and the left distal vertebral artery. The small basilar artery aneurysms remained untreated.

gery under general anesthesia for internal trapping of the VA including intraaneurysmal coil embolization via the contralateral VA. The aneurysm and the left distal VA were successfully obliterated using Guglielmi detachable coils (Boston Scientific Corporation, Fremont, Calif., U.S.A.).

Postoperatively, the patient's neurological condition improved gradually, despite transient deterioration of the lower cranial nerve pareses and respiratory failure that required tracheal cannulation and pressure support ventilation for several weeks. Approximately 3 months after the endovascular surgery, she still had slight ataxia and hoarseness but was discharged home, walking unaided, with the tracheostomy closed. Follow-up angiography obtained 6 weeks after the endovascular surgery demonstrated persistent complete obliteration of the aneurysm and the left distal VA (Fig. 4). MR imaging obtained about 28 months postoperatively revealed a remarkable decrease in the size of the aneurysm and reduction of mass effect on the brainstem (Fig. 3B).

## Discussion

Cure of giant aneurysm can be achieved by complete obliteration of the aneurysm from the intracranial circulation and by mass reduction if any mass effect is present. Therefore, aneurysm neck clipping or trapping of the parent artery, ideally combined with aneurysmectomy, is the optimal treatment for partially thrombosed giant aneurysms.<sup>1,9,12,17</sup> However, direct surgery is generally difficult and is associated with high surgical morbidity and mortality rates. Nine of 24 patients treated by direct surgery attempt-

ing primarily neck clipping and excision of the aneurysms suffered morbidity or mortality.<sup>13</sup> Morbidity and mortality rates were 14% and 4%, respectively, in a series of 80 surgical cases of giant aneurysms.<sup>16</sup> Poor outcomes in 5% with a mortality rate of 15% occurred in another surgical series of 40 patients with giant aneurysms.<sup>6</sup> Such surgical results reported by expert neurosurgeons are not satisfactory, with various numbers of patients with poor outcomes, although most patients had favorable outcomes. Therefore, some neurosurgeons have tried to perform endovascular surgery rather than direct surgery to treat giant aneurysms.

Endovascular surgery has recently been used as a therapeutic alternative for giant VA aneurysms,<sup>10,15</sup> but its efficacy remains uncertain. Treatment of a partially thrombosed aneurysm by endosaccular coil embolization resulted in a high rate of recanalization of the aneurysm at follow-up angiography due to either thrombus resolution or coil migration into the thrombus.<sup>14</sup> Thus, endovascular coil embolization of the parent artery, i.e., internal trapping, appears to be preferable for some giant aneurysms if the trapping can be tolerated.<sup>15</sup> However, a partially thrombosed giant VA aneurysm continued to enlarge even after complete internal trapping of the VA had been angiographically confirmed. Intraoperatively, markedly developed vasa vasorum was found on the proximal VA and aneurysm neck as well as retarded blood flow by coils in the occluded VA, suggesting that the vasa vasorum may be involved in the persistent enlargement of partially thrombosed aneurysms of the VA.<sup>7</sup>

The exact mechanism of the persistent growth of thrombosed aneurysms is not fully understood, but histopathological examinations suggested that an increase in the number and size of the capillary channels in the thrombus within the aneurysm, associated with repeated hemorrhage into the thrombus or new thrombus formation, may be involved in the growth of the aneurysm.<sup>11,12</sup> The pressure in these vascular channels that receive blood inflow directly from the parent artery is considered high enough to cause a separation of the old organized thrombus from the aneurysm wall.<sup>12</sup> Considering these histopathological evidences, treatment of partially thrombosed giant aneurysms by only endovascular surgery such as proximal coiling or internal trapping may be incomplete to control the pressure in the lumen of the VA and to restrain the aneurysm from growing.

In the present case, we had initially planned direct surgery but emergent proximal clipping was performed as a primary treatment, because we considered that surgical trapping would be too difficult

and invasive after subarachnoid hemorrhage had occurred, when increased intracranial pressure and acute brain swelling were expected. Proximal clipping was also favorable in that ventricular drainage for hydrocephalus and decompressive craniotomy can be done at once. Consequently, proximal clipping of the VA followed by internal trapping including coil embolization of the aneurysm and distal site of the VA were accomplished, which resulted in reduction in size as well as angiographically complete obliteration of the aneurysm. A similar case of a partially thrombosed aneurysm of VA was treated successfully by internal trapping 2 years after surgical proximal clipping of the parent VA, with gradually decreased mass effect and size of the aneurysm, as seen in our case.<sup>8)</sup> This combined use of proximal clipping and internal trapping for partially thrombosed giant aneurysms of VA appears to have some advantages. First, the vasa vasorum running around the proximal VA as well as anterograde flow to the aneurysm from the VA can be obliterated, although the possibility of recanalization or enlargement of the aneurysm through the vasa vasorum around the distal VA to the aneurysm cannot be completely eliminated. Second, the procedure is less invasive than direct surgery. Therefore, we consider that this combined method should be considered as a therapeutic option for patients with giant aneurysms of VA who are poor candidates for surgical neck clipping or surgical trapping, as the problems presented by direct surgery or endovascular surgery can be avoided.

### Acknowledgment

The authors thank Drs. A. Nishio and T. Kawakami at the Department of Neurosurgery, Osaka City University Graduate School of Medicine, for their valuable comments in preparing this manuscript.

### References

- 1) Aoki N, Sakai T, Oikawa A, Takizawa T: Giant unruptured aneurysm of the vertebral artery presenting with rapidly progressing bulbar compression — case report. *Neurol Med Chir (Tokyo)* 37: 907–910, 1997
- 2) Barrow DL, Alleyne C: Natural history of giant intracranial aneurysms and indications for intervention. *Clin Neurosurg* 42: 214–244, 1995
- 3) Choi IS, David C: Giant intracranial aneurysms: development, clinical presentation and treatment. *Eur J Radiol* 46: 178–194, 2003
- 4) Fujita K, Yamashita H, Masumura M, Nishizaki T, Tamaki N, Matsumoto S: [Natural history of giant intracranial aneurysms]. *No Shinkei Geka* 16: 225–231, 1988 (Jpn, with Eng abstract)

- 5) Gruber A, Killer M, Bavinski G, Richling B: Clinical and angiographic results of endosaccular coiling treatment of giant and very large intracranial aneurysms: a 7-year, single-center experience. *Neurosurgery* 45: 793–804, 1999
- 6) Hosobuchi Y: Direct surgical treatment of giant intracranial aneurysms. *J Neurosurg* 51: 743–756, 1979
- 7) Iihara K, Murao K, Sakai N, Soeda A, Ishibashi-Ueda H, Yutani C, Yamada N, Nagata I: Continued growth of and increased symptoms from a thrombosed giant aneurysm of the vertebral artery after complete endovascular occlusion and trapping: the role of vasa vasorum. Case report. *J Neurosurg* 98: 407–413, 2003
- 8) Kato N, Ezura M, Takahashi A, Yoshimoto T: [Intraaneurysmal embolization and parent artery trapping to treat a giant partial thrombosed vertebral artery aneurysm after surgical proximal clipping]. *No Shinkei Geka* 28: 817–822, 2000 (Jpn, with Eng abstract)
- 9) Lawton MT, Spetzler RF: Surgical management of giant intracranial aneurysms: experience with 171 patients. *Clin Neurosurg* 42: 245–266, 1995
- 10) Lubicz B, Leclerc X, Gauvrit JY, Lejeune JP, Pruvo JP: Giant vertebrobasilar aneurysms: endovascular treatment and long-term follow-up. *Neurosurgery* 55: 316–326, 2004
- 11) Mizutani T: A fatal, chronically growing basilar artery: a new type of dissecting aneurysm. *J Neurosurg* 84: 962–971, 1996
- 12) Nagahiro S, Takada A, Goto S, Kai Y, Ushio Y: Thrombosed growing giant aneurysms of the vertebral artery: growth mechanism and management. *J Neurosurg* 82: 796–801, 1995
- 13) Onuma T, Suzuki J: Surgical treatment of giant intracranial aneurysms. *J Neurosurg* 51: 33–36, 1979
- 14) Sluzewski M, Menovsky T, van Rooij WJ, Wijnalda D: Coiling of very large or giant cerebral aneurysms: long-term clinical and serial angiographic results. *AJNR Am J Neuroradiol* 24: 257–262, 2003
- 15) Standard SC, Guterman LR, Chavis TD, Fronckowiak MD, Gibbons KJ, Hopkins LN: Endovascular management of giant intracranial aneurysms. *Clin Neurosurg* 42: 267–293, 1995
- 16) Sundt TM, Piepgras DG: Surgical approach to giant intracranial aneurysms. Operative experience with 80 cases. *J Neurosurg* 51: 731–742, 1979
- 17) Wakui K, Kobayashi S, Takemae T, Kamijoh Y, Nagashima H, Muraoka S: Giant thrombosed vertebral artery aneurysm managed with extracranial-intracranial bypass surgery and aneurysmectomy. Case report. *J Neurosurg* 77: 624–627, 1992

---

Address reprint requests to: Yuzo Terakawa, M.D., Department of Neurosurgery, Osaka City University Graduate School of Medicine, 1-4-3 Asahi-machi, Abeno-ku, Osaka 545-8585, Japan.  
e-mail: terakawa@msic.med.osaka-cu.ac.jp