

## Transient global amnesia during transoesophageal echocardiogram

Paolo Profice · Vittoria Rizzello · Faustino Pennestrì · Fabio Pilato  
Giacomo Della Marca · Alfonso Sestito · Filippo Crea  
Pietro A. Tonali · Vincenzo Di Lazzaro

Received: 22 April 2008 / Accepted: in revised form: 10 October 2008 / Published online: 24 November 2008  
© Springer-Verlag 2008

**Abstract** Transient global amnesia (TGA) is a common paroxysmal disorder of episodic memory. The aetiology of TGA is still unknown. Brain ischaemia, migraine, epileptic seizure, venous congestion and psychological disturbances have been proposed as pathological mechanisms. Moreover, different precipitating events are recognised in most TGA patients including physical activity, severe emotional stress, painful experiences, immersion in cold water and sexual intercourse. We describe a 54-year-old woman who presented a TGA immediately after right–left shunt of saline contrast during the execution of transoesophageal echocardiography. Aetiopathological considerations for this uncommon presentation are discussed.

Transient global amnesia (TGA) is a paroxysmal disorder of episodic memory, consisting of anterograde amnesia with time disorientation, perplexity and variable retrograde amnesia. The aetiology and pathophysiological mechanisms of TGA are still unknown. Proposed mechanisms include hippocampal ischaemic events, epilepsy, migraine and psychogenic origin [1]. Moreover, several precipitating events have been described in TGA, the most common events include physical exertion, severe emotional stress, painful experiences, immersion in cold water and sexual intercourse [2, 3].

We describe a 54-year-old woman who presented a TGA immediately after right–left shunt of saline contrast during the execution of transoesophageal echocardiography (TEE).

### Case report

A 54-year-old woman with unremarkable medical history was diagnosed with a TGA episode 6 months before our observation. The episode was characterised by acute onset of anterograde amnesia, nausea and time disorientation. Nine hours after the onset of the disturbance a complete recovery of time disorientation and anterograde amnesia was observed but a lacunar amnesia about the onset of symptoms was still present.

About 48 h after the onset of symptoms the patient underwent MRI scan of the brain (GE 1.5 T) with diffusion-weighted images (DWI), EEG, doppler scan of the supra-aortic vessels, blood count, prothrombin time, activated thromboplastin time, ionogram, CRP, troponin Ic, ECG and chest radiography. A thrombophilia screening was also performed, including tests for the factor V Leiden mutation, the prothrombin G20210A mutation,

P. Profice · F. Pilato · G. Della Marca · P.A. Tonali · V. Di Lazzaro (✉)  
Institute of Neurology  
Università Cattolica  
L.go A. Gemelli 8  
00168 Rome, Italy  
e-mail: vdilazzaro@rm.unicatt.it

V. Rizzello · F. Pennestrì · A. Sestito · F. Crea  
Cardiology Department  
Università Cattolica  
Rome, Italy

P.A. Tonali · V. Di Lazzaro  
Fondazione Don C Gnocchi  
Rome, Italy

antiphospholipid antibodies and factor VIII, protein C, protein S and antithrombin activities. All these tests were completely normal.

A transthoracic echocardiography performed about two months after the episode showed interatrial septum bulging. TEE with agitated saline medium was prescribed and performed a few months later. Contrast study TEE by agitated saline medium was performed during normal respiration, at rest and during Valsalva manoeuvre. No sedation of the patient was used. The procedure showed the presence of patent foramen ovale with right–left shunt during Valsalva manoeuvre (Fig. 1) and was promptly interrupted immediately after Valsalva manoeuvre because the patient appeared confused. On neurological examination, the patient was disoriented in time, but not in place, and showed complete anterograde amnesia. No other neurological signs could be elicited. Blood count, prothrombin time, activated thromboplastin time, ionogram, CRP, troponin Ic and creatine kinase were normal. ECG, chest radiography, cerebral CT, EEG and MRI scan of the brain (GE 1.5 T) with DWI performed 48 h after the onset of the event showed no abnormalities.

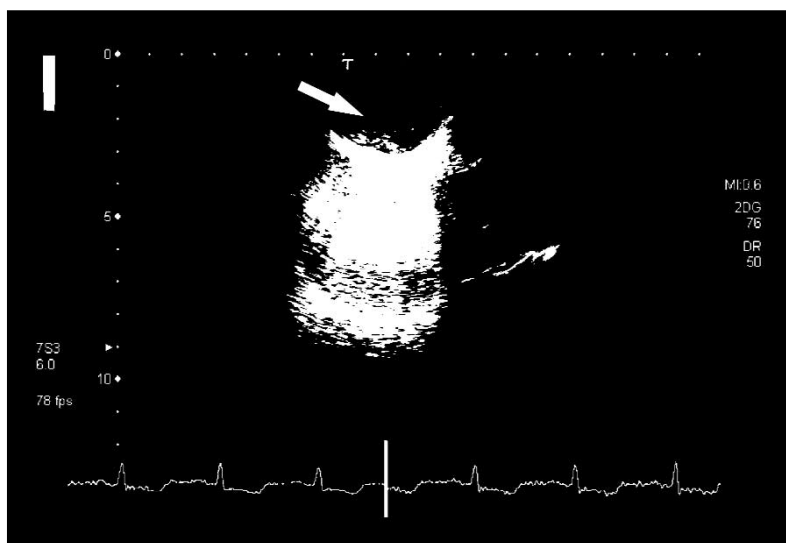
The anterograde amnesia completely resolved spontaneously in 24 h, leaving a memory gap corresponding to the episode. One month after the event percutaneous transcatheter closure of PFO was successfully performed. No further episode of TGA occurred in the following 6 months.

The aetiology of TGA is still debated and it has been hypothesised that superior vena cava and cerebral venous congestion leading to hippocampal venous ischaemia can result from the Valsalva manoeuvre [1]. It has also been reported that, in some patients, TGA is started by a Valsalva-like manoeuvre with transient increase in intrathoracic pressure, like coughing, straining to defecate and sexual intercourse, as well as heavy lifting, sawing or pumping [4].

This hypothesis was supported by the finding of a higher incidence of a retrograde flow pattern in the internal jugular vein in TGA [5, 6]. Positron emission tomography suggests dysfunction in the amygdala [7] and several reports described DWI signal intensity changes of mesial structures in most patients with TGA [8–12]. A transient, punctate lesion visible in DWI in the lateral aspect of the hippocampal formation (pes, fimbria hippocampi) or parahippocampal gyrus is often detected on either side or bilaterally. Lesions are rarely noted in the hyperacute phase but become visible regularly at about 48 h [13].

Indeed, DWI is highly sensitive for ischaemia but is not specific. Cytotoxic oedema has been found in other disorders such as hypoglycaemia, cortical spreading depression or epileptic seizure. Thus, these DWI findings are far from conclusive for the nature of the physiopathological mechanism of TGA [14]. TEE with performance of a Valsalva manoeuvre following the intravenous injection of agitated saline medium is commonly used for the detection of PFO in patients with cryptogenic stroke. The increase of right atrial pressure associated with a Valsalva manoeuvre allows a right-to-left inter-atrial shunt through a PFO to be detected.

In our patient the Valsalva manoeuvre caused right–left shunt of agitated saline medium immediately after she developed TGA. The temporal relationships between diagnostic procedure and the amnesic symptoms strongly suggest that TEE triggered the amnesia in our patient. However the pathophysiological mechanism is unclear. Several hypotheses can be made: the strict temporal relationship between right–left shunt of contrast medium and TGA onset could suggest that, in the present patient, TGA may have an arterial embolic origin, thus representing a form of ischaemic event due to paradoxical embolism caused by Valsalva manoeuvre. Therefore we cannot exclude that the presence of PFO in



**Fig. 1** TEE during Valsalva manoeuvre following the intravenous injection of agitated saline medium, immediately before the onset of TGA in this patient. White arrow shows right–left atrial shunt

this patient was just a coincidence because of high prevalence in the general population of this condition [15], even though Klotzsch et al. [4] reported an increased frequency of patent foramen ovale in patients with TGA. In this case TGA could be simply triggered by Valsalva manoeuvre, which, as previously mentioned, was recognised as a trigger event. It is also possible that symptoms were related to emotional stress linked to the procedure but TGA has never been reported during endoscopic oesophageal procedure; a vagal response induced by TEE is unlikely because ECG was monitored during the procedure and did not show any abnormality.

In conclusion, this unusual trigger event for TGA suggests an embolic origin of this disorder. However, it could also be explained in different ways and it is impossible draw any definite aetiopathological conclusion from this case report. Therefore, despite the large number of TEE performed worldwide, this is the first reported association of this procedure with TGA. It is therefore conceivable that different factors may lie behind the development of TGA in this patient; in our opinion it is worth noting.

**Conflict of Interest statement** The Authors certify that there is no actual or potential conflict of interest in relation to this article.

## References

- Lewis SL (1998) Aetiology of transient global amnesia. *Lancet* 352:397–399
- Fisher CM (1982) Transient global amnesia. Precipitating activities and other observations. *Arch Neurol* 39:605–608
- Richardson RS, Leek BT, Wagner PD, Kritchevsky M (1998) Transient global amnesia: a complication of incremental exercise testing. *Med Sci Sports Exerc* 30[10 Suppl]:S403–S405
- Klotzsch C, Sliwka U, Berlit P, Noth J (1996) An increased frequency of patent foramen ovale in patients with transient global amnesia. Analysis of 53 consecutive patients. *Arch Neurol* 53:504–508
- Sander D, Winbeck K, Etgen T et al (2000) Disturbance of venous flow patterns in patients with transient global amnesia. *Lancet* 356:1982–1984
- Akkawi NM, Agosti C, Rozzini L et al (2001) Transient global amnesia and disturbance of venous flow patterns. *Lancet* 357:957
- Guillery B, Desgranges B, de la Sayette V et al (2002) Transient global amnesia: concomitant episodic memory and positron emission tomography assessment in two additional patients. *Neurosci Lett* 325:62–66
- Strupp M, Bruning R, Wu RH et al (1998) Diffusion-weighted MRI in transient global amnesia: elevated signal intensity in the left mesial temporal lobe in 7 of 10 patients. *Ann Neurol* 43:164–170
- Sedlaczek O, Hirsch JG, Grips E et al (2004) Detection of delayed focal MR changes in the lateral hippocampus in transient global amnesia. *Neurology* 62:2165–2167
- Winbeck K, Etgen T, von Einsiedel HG et al (2005) DWI in transient global amnesia and TIA: proposal for an ischaemic origin of TGA. *J Neurol Neurosurg Psychiatry* 76:438–441
- Nakada T, Kwee IL, Fujii Y, Knight RT (2005) High-field, T2 reversed MRI of the hippocampus in transient global amnesia. *Neurology* 64:1170–1174
- Cianfoni A, Tartaglione T, Gaudino S et al (2005) Hippocampal magnetic resonance imaging abnormalities in transient global amnesia. *Arch Neurol* 62:1468–1469
- Menéndez González M, Rivera MM (2006) Transient global amnesia: increasing evidence of a venous etiology. *Arch Neurol* 63:1334–1336
- Quinette P, Guillery-Girard B, Dayan J et al (2006) What does transient global amnesia really mean? Review of the literature and thorough study of 142 cases. *Brain* 129:1640–1658
- Meissner I, Whisnant JP, Khandheria BK et al (1999) Prevalence of potential risk factors for stroke assessed by transesophageal echocardiography and carotid ultrasonography: the SPARC study. Stroke prevention: assessment of risk in a community. *Mayo Clin Proc* 74:862–869