

# Brain Lesions Manifesting as Psychiatric Disorders: Eight Cases

By Adomas Bunevicius, MD, Vytenis Pranas Deltuva, MD, PhD, Daiva Deltuviene, MD, Arimantas Tamasauskas, MD, PhD, and Robertas Bunevicius, MD, PhD

## ABSTRACT

Sometimes patients with organic brain lesions in neurologically silent brain areas might present only with psychiatric symptoms, such as depression, anxiety disorders, schizophrenia, anorexia nervosa, or cognitive dysfunction. This study presents eight cases of patients with brain lesions (four cases of meningiomas, one case of intracerebral cysts, one case of anaplastic oligodendroglioma, one case of multiform glioblastoma, and one case of occlusive hydrocephalus) who, for a significant period of time, were diagnosed and treated for psychiatric disorders (three cases of Alzheimer's disease, two cases of schizoaffective disorder, one case of schizophrenia, one case of depression, and one case of organic emotional lability disorder). When neurologic symptoms developed, they underwent neuroimaging studies and organic brain lesions were diagnosed. Further treatment required neurosurgical interventions. These cases show that brain tumors can be neurologically silent for a sufficient period of time and manifest as psychiatric disorders.

## FOCUS POINTS

- Patients with organic brain lesions might present with a variety of psychiatric symptoms for a sufficient period of time in the absence of neurologic symptoms and signs.
- Delay to perform brain imaging might have a direct negative effect on treatment options and quality of life of such patients.
- Brain imaging should be considered not only for psychiatric patients with neurologic symptoms and signs, but for all psychiatric patients who present with atypical psychiatric symptoms, with late onset of psychiatric symptoms (>50 years of age), or there is a change in clinical presentation of psychiatric symptoms.

Therefore, neuroimaging studies are needed when atypical changes in mental status or neurologic symptoms and signs develop.

*CNS Spectr.* 2008;13(11):950-958

## INTRODUCTION

Association of intracranial tumors and other organic brain lesions with high incidence of psychiatric symptoms has been known for a long time.<sup>1-3</sup> In patients with organic brain lesions,

Dr. A. Bunevicius is research fellow at the Institute of Psychophysiology and Rehabilitation of the Kaunas University of Medicine in Palanga, Lithuania. Dr. Deltuva is neurosurgeon-research scientist in the Laboratory of Neuroscience at the Institute of Biomedical Research at the Kaunas University of Medicine. Dr. Deltuviene is psychiatrist at the Institute of Neuromedicine. Dr. Tamasauskas is neurosurgeon-senior research scientist in the at Laboratory of Neuroscience at the Institute of Biomedical Research of the Kaunas University of Medicine. Dr. R. Bunevicius is director of the Institute of Psychophysiology and Rehabilitation at the Kaunas University of Medicine.

Faculty Disclosures: The authors do not have an affiliation with or financial interest in any organization that might pose a conflict of interest.

Submitted for publication: February 2, 2008; Accepted for publication: October 1, 2008.

Please direct all correspondence to: Adomas Bunevicius, MD, Vyduno al. 4, LT-00135, Palanga, Lithuania; Tel: 37-068-62-0682; E-mail: a.bunevicius@yahoo.com.

a great variety of psychiatric disorders, including depression, anxiety disorders, personality changes, mania, psychosis, cognitive deterioration, and anorexia nervosa, is reported.<sup>1,4-7</sup>

Kocher and colleagues<sup>8</sup> reported that 1/1,000 of hospitalized psychiatric patients have brain tumors. This rate is ~20-times higher than in general population. Gupta and Kumar<sup>4</sup> found that 21% of patients with benign meningiomas presented with psychiatric symptoms, such as depression, anxiety disorders, or personality changes, in the absence of neurologic signs. It indicates that, in some cases, brain tumors can be associated with psychiatric symptoms only, in the absence of neurological or physical signs, making diagnostic of a brain tumor extremely difficult. Moreover, a recent review<sup>9</sup> shows that there is no association between tumor location or histological type and psychiatric symptoms.

Despite the fact that brain tumors and other organic brain lesions are frequent in psychiatric patients, it is unlikely for a psychiatrist to diagnose brain lesion without a routine use of brain imaging techniques. It is recommended to perform brain imaging for all patients who present with initial psychiatric symptoms, such as psychotic break or personality change, after 50 years of age or there is a change in patients' symptoms or patient develops suggestive neurological symptoms and signs.<sup>7,10</sup> In the prospective study aiming to examine frequency of undiagnosed conditions in 337 psychiatric patients, Hollister and Boutros<sup>10</sup> found that only two patients had brain tumors and due to that their treatment was changed from psychiatric to neurosurgical.

The aim of this study was to describe patients who had initial psychiatric diagnosis, but were eventually diagnosed to have an organic brain lesion that led to neurosurgical intervention.

## METHODS

We performed retrospective qualitative analysis of medical records of patients admitted to the Department of Neurosurgery of the Kaunas Medical University Hospital from 2003–2007. Only cases when patients had psychiatric diagnosis and were treated by a psychiatrist from several weeks to a few years before admitting to Department of Neurosurgery and psychiatric diagnosis antedated diagnosis of structural brain lesion were included to the analysis. Patients for

whom psychiatric disorders were diagnosed after admission to the Department of Neurosurgery or after surgical treatment of the organic brain lesion were excluded from the study. Data on psychiatric diagnoses and treatment were collected from the records in medical documentation.

The diagnoses of organic brain lesions were based on the record of final diagnoses in medical case record confirmed by computed tomography (CT) or magnetic resonance imaging (MRI) scans. In case of brain tumors, histological findings were taken into consideration.

Analysis of medical case records that matched inclusion criteria was performed together with psychiatrists (R.B. and D.D.) and neurosurgeons (V.P.D. and A.T.). Analyses of medical records included evaluation of the history of the psychiatric disorder; manifestation of the psychiatric symptoms; history of psychiatric treatment, evaluation of the history of structural brain disease; manifestation of neurological symptoms; diagnostic procedures performed; and diagnosis established before and after admission to the Department of Neurosurgery as well as neurosurgical interventions. In medical records, all diagnoses of psychiatric disorders were established according to the *International Classification of Disease, 10th Edition* classification.<sup>11</sup> We also analyzed initial results of neurosurgical treatment based on the records in medical documentation.

## RESULTS

Eight patients matched inclusion criteria and their cases are presented in this report. All eight patients were women between 38–75 years of age (Table).

### Patient 1

During past 10 years, a 57-year-old woman was treated in psychiatric departments for schizophrenia several times. When epileptic seizures developed, MRIs were performed. MRIs of the brain revealed glial tumor in the left temporal lobe involving limbic structures and anterior part of corpus callosum (Figure 1) and she was transferred to the Department of Neurosurgery. The patient underwent osteoplastic craniotomy with partial resection of the mass. Histopathology revealed anaplastic oligodendroglioma grade III. She underwent radiation therapy and her condition improved. Six months later, her psychi-

cal condition started to deteriorate and she developed aphasia. Neurological examination revealed sensomotoric aphasia, nystagmus to the left side, and right hemiparesis. MRIs of the brain revealed recurrence and malignant transformation of oligodendroglioma in the left temporal lobe. The patient underwent osteoplastic craniotomy with partial resection of the mass. After treatment, she improved, but a few days later she started to run a fever and died of infectious complications.

### Patient 2

A 57-year-old female was presented to psychiatric department with complaints of anxiety, depression, feelings of pressure in her chest, feeling like "she has hairs in her mouth", general weakness, 6-month history of weakness in her right arm, and 3-month history of headaches. Complaints of depression began 8 years ago when her husband died. Since then, she was several times consulted by psychiatrist who diagnosed her with generalized anxiety disorder. Her symptoms did not improve. Later, her diagnosis was changed to recurrent depressive disorder with symptoms of psychosis and was treated in psychiatric hospital. Three years ago, her daughter left the house and since then the patient's complaints of depression deteriorated, she started complaining of anxiety, sleeping disorders, irritability, unpleasant sensations in her

mouth, and loss of appetite. She was treated for schizoaffective disorder in psychiatric hospital. During her last admission to the Department of Psychiatry, she was diagnosed with organic mood disorder. She was consulted by a neurologist. Neurologic examination revealed hyperesthesia in the right side of her body. CT scans (Figure 2) of the brain revealed intra-cerebral cyst in the left temporal lobe with no signs of tumor.

### Patient 3

A 38-year-old female patient 5 years ago, 2 years ago, and 3 weeks ago was treated in the psychiatric hospital for schizoaffective disorder. She used to have feelings that she was being persecuted and had complaints of insomnia. These symptoms used to improve after inpatient treatment. Three months before reference to neurosurgeon she began to have difficulty speaking. One week later she developed inconsistent headaches in the left temporal side. A psychiatrist suspected organic brain lesion and the patient was admitted to the Department of Neurosurgery. Neurologic evaluation revealed partial sensomotoric aphasia and positive and inconsistent Babinski reflex in the right side. A contrast-enhanced MRIs of the brain revealed 4.7X5.3X4.9 cm tumor in the left temporal lobe with signs of perifocal edema and compression of the left ventricle (Figure 3). Glioblastoma was suspected. The patient underwent surgery

**TABLE.**

### Clinical Data of Eight Female Psychiatric Patients with Psychiatric Disorders and Organic Brain Lesion

No.	Age (years)	Psychiatric Diagnosis	Neurologic Diagnosis	Location of Organic Brain Lesion
1	57	Schizophrenia	Anaplastic oligodendroglioma III <sup>0</sup>	Left temporal lobe
2	57	Schizoaffective disorder	Intra-cerebral cyst	Left temporal lobe
3	38	Schizoaffective disorder	Multiform glioblastoma IV <sup>0</sup>	Left temporal lobe
4	62	Depression, Parkinson's disease	Meningioma	Left frontotemporal
5	64	Dementia, Alzheimer's disease	Occlusive hydrocephalus	Secondary stenosis of aqueductus
6	75	Dementia, Alzheimer's disease	Meningioma	Posterior fossa
7	65	Dementia, Alzheimer's disease	Meningioma	Bifrontal
8	71	Organic emotional lability [mood] disorder	Meningioma	Right temporal side

Bunevicius A, Deltuva VP, Deltuviene D, Tamasauskas A, Bunevicius R. *CNS Spectr*. Vol 13, No 11. 2008.



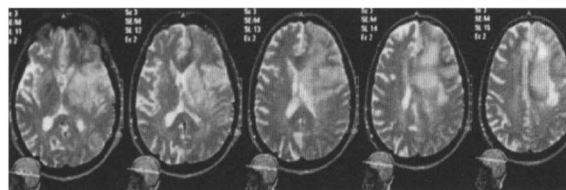
with extirpation of the tumor. Histopathology revealed multiform glioblastoma grade IV.

#### Patient 4

A 62-year-old female teacher presented to an outpatient department of the university clinic complaining of headaches, inability to sleep, depression, and weakness of the left side of the body. Several years ago, she was diagnosed with depression and was treated with antidepressants. Six months ago, she developed walking disorders and was suspected to have Parkinson's disease. She started receiving treatment for Parkinson's disease.

**FIGURE 1.**

**MRIs showing a 3X3.5X4 cm tumor in the left temporal lobe involving limbic structures and anterior of corpus callosum**

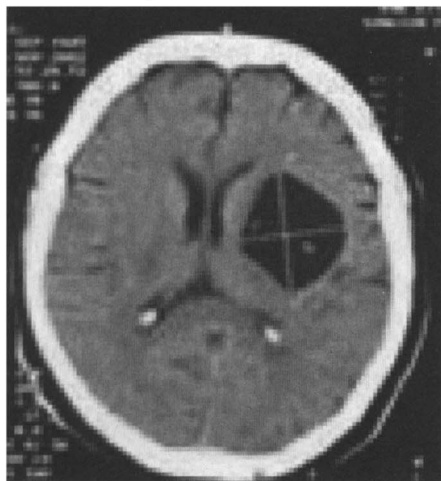


MRI=magnetic resonance imaging.

Bunevicius A, Deltuva VP, Deltuviene D, Tamasauskas A, Bunevicius R. *CNS Spectr.* Vol 13, No 11. 2008.

**FIGURE 2.**

**A CT scan of the brain showing cyst in the insulo-temporal lobe**



CT=computed tomography.

Bunevicius A, Deltuva VP, Deltuviene D, Tamasauskas A, Bunevicius R. *CNS Spectr.* Vol 13, No 11. 2008.

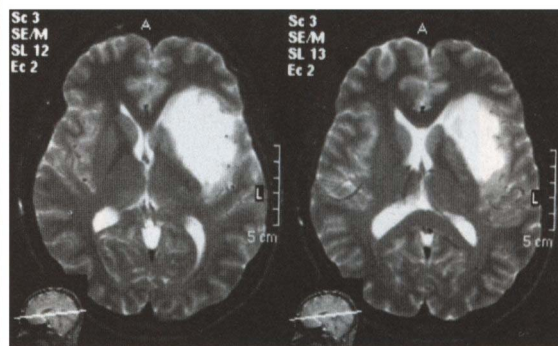
Neurologic examination revealed left hemiparesis. MRIs of the brain were performed and right fronto-temporal tumor compressing basal ganglia was found (Figure 4). Meningioma was suspected. The patient underwent osteoplastic craniotomy with extirpation of the tumor. Histopathology revealed fibrous meningioma. After treatment, the patient's neurologic symptoms remained stable and she underwent rehabilitation program.

#### Patient 5

A 64-year-old female patient presented with complains of memory disorder, walking disorder, and urine incontinence. She had a few years' history of memory disorder and was treated for dementia and Alzheimer's disease. Walking disorder and urine incontinence developed in a period of 1.5 years. From medical history, it is known that, several years ago, the patient was diagnosed with arachnoiditis. Neurologic examination revealed right hemiparesis. CT scans of the brain showed enlargement of the third ventricle up to 2 cm in width. It also showed symmetric enlargement in width of the lateral ventricles (Figure 5). Internal occlusive hydrocephalus due to secondary stenosis of aqueductus was diagnosed. The patient underwent endoscopic surgery. After the procedure, all neurologic symptoms disappeared.

**FIGURE 3.**

**Contrast enhanced MRIs of the brain revealed 4.7X5.3X4.9 cm tumor in the left temporal lobe with signs of perifocal edema and compression of the left ventricle**



MRI=magnetic resonance imaging.

Bunevicius A, Deltuva VP, Deltuviene D, Tamasauskas A, Bunevicius R. *CNS Spectr.* Vol 13, No 11. 2008.

**Patient 6**

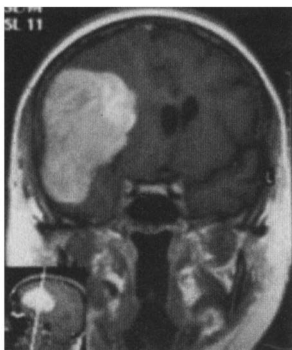
A 75-year-old female presented with complaints of memory disorder, urine incontinence, headache, and dizziness. She had a 10-year history of walking disorder and was receiving treatment for Alzheimer's disease. In the last 2 years, she was not able to walk and was suspected to have circulation disorder of vertebrobasilar arteries. Several months ago, the palsy of the X cranial nerve appeared and she was unable to swallow. General physical and neurologic examination revealed paraparesis of legs. CT scans of the brain revealed huge mass in the posterior fossa with signs of occlusive hydrocephalus (Figure 6). Meningioma was suspected. The patient underwent trepanation of posterior fossa with total resection of the tumor. Histopathology revealed fibrous meningioma. After surgery, walking disorder improved and urine incontinence disappeared. No data on cognitive functioning after surgery.

**Patient 7**

A 65-year-old female retired math teacher presented to the Department of Neurosurgery with complains of headache and urine incontinence. She had a 1-year history of memory loss and was receiving treatment for Alzheimer's disease. Urine incontinence was suspected to be caused by gynecological problems. MRIs of the

**FIGURE 4.**

**Coronal MRI showing supratentorial frontotemporal meningioma 6X8 cm in size on the right side, obtained after the administration of gadolinium**



CT=computed tomography.

Bunevicius A, Deltuva VP, Deltuviene D, Tamasauskas A, Bunevicius R. *CNS Spectr.* Vol 13, No 11. 2008.

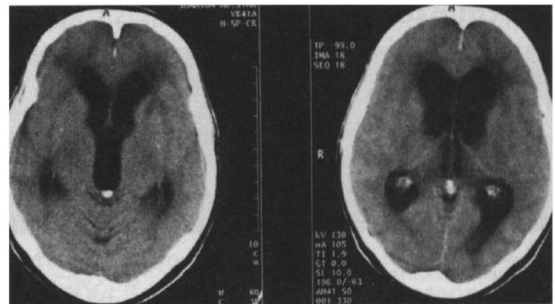
brain revealed big bifrontal meningioma compressing corpus callosum (Figure 7). The patient underwent resection of the tumor. All symptoms resolved 6 months after the surgery.

**Patient 8**

A 71-year-old female presented with complaints of headache, dizziness, memory disorder, orientation disorder, and numbness in her left leg. She also had 6-month history of complaints of anxiety, fear, increased sensibility, and irritability. She was consulted by a psychiatrist and

**FIGURE 5.**

**CT scans showing third ventricle up to 2 cm in width, symmetric increase in width of the lateral ventricles and signs of periventricular edema**

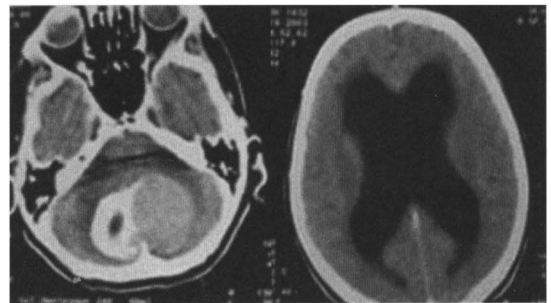


CT=computed tomography.

Bunevicius A, Deltuva VP, Deltuviene D, Tamasauskas A, Bunevicius R. *CNS Spectr.* Vol 13, No 11. 2008.

**FIGURE 6.**

**Contrast enhanced brain CT scans showing fibrous meningioma of tentorium cerebelli 6.5X4.5X3.5 cm in size in posterior fossa**



CT=computed tomography.

Bunevicius A, Deltuva VP, Deltuviene D, Tamasauskas A, Bunevicius R. *CNS Spectr.* Vol 13, No 11. 2008.

organic emotional lability disorder was diagnosed. Neurologic examination performed by a neurosurgeon revealed horizontal nystagmus, positive Bare sign in the right side and positive Babinski reflexes. MRIs of the brain revealed 4.5X3.8X4.1 cm tumor in the right temporal area (Figure 8). The patient underwent craniotomy with complete extirpation of the tumor. Histopathology revealed meningioma grade II. After treatment, the patient's orientation improved. No data on emotional status after surgery.

## DISCUSSION

These cases illustrate that sometimes patients with organic brain lesions for a moderate period of time might present with psychiatric symptoms only, have an established psychiatric diagnosis and receive treatment for psychiatric disease. In reported cases, manifestation of local or generalized neurologic symptoms led on to performing brain imaging and diagnosing organic brain lesions. In all eight cases, further treatment required neurosurgical interventions.

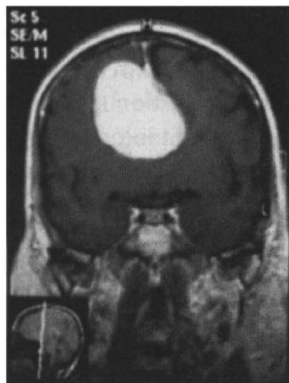
In typical cases patients with organic brain lesions develop focal and/or generalized neurologic symptoms and signs.<sup>12</sup> Focal neurologic symptoms and signs depend on the location of the brain tumor and include hemiparesis, hemianopsia, aphasia, and other. These symptoms develop in many patients with primary or metastatic intracranial tumors and usually have subacute and

progressive development. Generalized neurologic symptoms are caused by increased intracranial pressure caused by mass effect and disruption of blood-brain barrier, causing diffusion of water, electrolytes, and proteins into neural tissue.<sup>13</sup> The most common generalized symptom is headache, which occurs in half of all patients with gliomas and in one third of all patients with meningiomas.<sup>12</sup> Other generalized symptoms include nausea, vomiting, and mental-status abnormalities.<sup>12</sup> Sometimes, brain lesions are neurologically silent and patients present with psychiatric symptoms only. The psychiatrist must be suspicious of organic brain lesion and look for neurologic symptoms and signs or have his patient consulted by the neurologist. In the majority of cases, patients were referred to neurosurgeon when typical local neurologic symptoms (seizures, hemiparesis, and aphasia), and/or typical generalized neurologic symptoms (headache) developed.

In the first three cases, the patients had 3–10-year histories of schizophrenia spectrum disorders and were eventually diagnosed with an anaplastic oligodendroglioma, an intra-cerebral cyst, and a multiform glioblastoma, respectively. In all three patients, organic lesions were located in the left temporal lobe. Studies<sup>14,15</sup> have demonstrated that reduction in grey matter volume of the left temporal lobe is specific to schizophrenia. Moreover, Kasai and colleagues<sup>16</sup> have shown that gray matter volume of the left superior temporal gyrus

**FIGURE 7.**

**A contrast enhanced MRI showing bifrontal meningioma involving limbic structures**

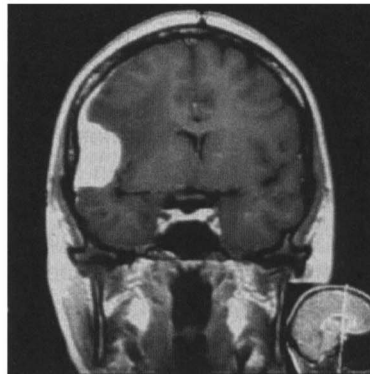


MRI=magnetic resonance imaging.

Bunevicius A, Deltuva VP, Deltuviene D, Tamasauskas A, Bunevicius R. *CNS Spectr.* Vol 13, No 11. 2008.

**FIGURE 8.**

**An MRI showing 4.5X3.8X4.1 cm extra-axial tumor in the right temporal area**



MRI=magnetic resonance imaging.

Bunevicius A, Deltuva VP, Deltuviene D, Tamasauskas A, Bunevicius R. *CNS Spectr.* Vol 13, No 11. 2008.



progressively reduces in schizophrenic patients. It indicates that abnormalities in this part of the brain might play an important role in pathophysiology of schizophrenia.

In patient 3, an organic brain lesion was suspected and she was referred to perform brain imaging only when local (sensomotoric aphasia) and generalized (headache) neurologic signs and symptoms developed. Complaints of aphasia started before her last admission to an inpatient psychiatric hospital, but organic brain lesion was not suspected at that time. Brain imaging was performed only when she developed headache.

This case suggests that psychiatrists must keep in mind that schizophrenia is associated with structural abnormalities in the left temporal lobe and must be aware of focal neurologic signs caused by organic lesions in the left temporal lobe.

Patient 2 indicates importance of interpretation of atypical psychiatric symptoms. In this case, atypical symptoms of affective disorder, such as unpleasant sensations of hairs in the mouth, developed 3 years before neurologic diagnosis and resulted in changing psychiatric diagnosis from generalized anxiety disorder to diagnosis of schizoaffective disorder. However, brain imaging was performed only when local (weakness of the right arm) and generalized (headache) neurologic signs and symptoms developed. Brain tumors can cause atypical psychiatric symptoms, such as auditory hallucinations, visual hallucinations, or peduncular hallucinosis.<sup>17-19</sup> Therefore, it is recommended to perform brain imaging when a patient present with atypical psychiatric symptoms or there is a change in the patient's symptoms pattern.<sup>9</sup>

Patient 1 had a 10-year history of schizophrenia. The development of seizures led to performing brain imaging and diagnosing a brain tumor. However, we do not have data of neurologic symptoms and signs at the time of her first admission. Epileptic seizures are common in patients with brain tumors.<sup>20</sup> Moreover, in some cases seizures might be the first sign of brain tumor and organic brain lesion must always be included into differential diagnostics of seizures, as done in this case.<sup>21,22</sup>

Patient 4 had a 6-year history of depression and 6-month history of Parkinson's disease. MRIs were performed when patient developed headache and left hemiparesis. Right fronto-temporal meningioma compressing basal ganglia was diagnosed.

In some reports, there are presented cases of patients with a history of depression who were eventually diagnosed to have brain tumor.<sup>23,24</sup> Gupta and Kumar<sup>4</sup> reported that 21% of patients with meningiomas presented with psychiatric symptoms, including depressive illness and/or anxiety and personality-related changes, in the absence of neurologic signs, although there is no information on how many of those patients had only a depressive illness. Thus, diagnosing a brain tumor might lead to revision of the diagnosis of depression. In some cases, symptoms of parkinsonism resolved completely after extirpating a brain tumor.<sup>25,26</sup> In the presented case, symptoms of parkinsonism were probably caused by compression of the basal ganglia by meningioma as it was seen in the CT scans. It has been suggested that parkinsonian patients with atypical symptoms and poor response to dopaminergic drugs as well as patients with focal neurologic signs must undergo brain imaging.<sup>26</sup>

Patients 5 and 6 were 64 and 75 years of age, respectively, and had a classic triad of symptoms of hydrocephalus: a few to a 10-year history of dementia (diagnosed as Alzheimer's disease), gait disturbances, and urine incontinence (patient 6 also had palsy of the tenth cranial nerve), but were eventually diagnosed with occlusive hydrocephalus due to secondary stenosis of aqueductus and meningioma in the posterior fossa with signs of occlusive hydrocephalus, respectively. Hydrocephalus is associated with the decrease of cognitive capabilities and sometimes patients may be incorrectly diagnosed with dementia.<sup>27,28</sup> However, studies show that cognitive functions improve after removal of hydrocephalus (shunt insertion), therefore, normal circulation of cerebrospinal fluid must be restored.<sup>29,30</sup> On the other hand, it was reported that in patients with borderline dementia shunt insertion surgery resulted in no or minimal improvement in cognitive functioning.<sup>31</sup> In the presented cases, standardized test for evaluation of cognitive functioning were not presented to patients before and after neurosurgical intervention, therefore, we could not evaluate the influence of removal of hydrocephalus on cognitive capabilities. However, incontinence and gait disturbances have improved in both patients. This shows that patients with dementia must receive a high level of awareness for organic brain lesions.

Patient 7 presented with complaints of head-

ache, urine incontinence, and a 1-year history of Alzheimer's disease. There were no focal neurologic signs. MRIs of the brain showed big bifrontal meningioma compressing corpus callosum. There is an established relationship between structural changes in corpus callosum and cognitive impairment.<sup>32,33</sup> Also, the extent of damage to corpus callosum correlates with the severity of dementia.<sup>34</sup>

Patient 8 had a 6-month history of complaints of anxiety, fear, as well as increased sensibility and irritability. She was eventually diagnosed with organic emotional lability disorder. When focal and generalized neurologic signs developed, the patient was diagnosed with meningioma in the right temporal side. Mainio and colleagues<sup>35</sup> found that brain tumors in the right hemisphere are associated with higher level of anxiety, and there is a significant decline of anxiety level after extirpation of the tumor. This association was not found in respect to brain tumors located in the left hemisphere.

It has been suggested that the laterality of anxiety might reflect the differentiation of the two hemispheres although the association is not yet understood. Another study<sup>36</sup> found no association between laterality of brain tumor and anxiety level. Further research is needed in determining the effect of right hemisphere tumors on anxiety symptoms.

## CONCLUSION

Once the local or generalized neurologic symptoms manifest, brain imaging must be performed as soon as possible. This is the most common paradigm of diagnosis of organic brain lesion in psychiatric patient: psychiatric symptoms, focal or generalized neurologic symptoms, brain imaging, organic brain lesion. However, this way may be too long for a patient with brain tumor (or with other organic brain lesion), because early detection has direct influence on treatment options and quality of life of such patients. In fact, consideration of brain imaging should not be limited to generalized or focal neurologic symptoms in psychiatric patients, but must also be considered for all psychiatric patients who present with atypical psychiatric symptoms, with late onset of psychiatric symptoms (>50 years of age) or there is a change in clinical presentation of psychiatric symptoms.

A major limitation of this study was that there

was no follow-up of patients. The course of psychiatric symptoms after neurosurgical intervention is not known. Therefore, we could not establish whether psychiatric symptoms were caused by organic brain lesion or the patients had two separate diseases. Another limitation as with many retrospective studies was that we were not able to verify psychiatric diagnoses noted in patients medical histories. However, all psychiatric diagnoses were coded as *ICD-10* psychiatric diagnoses (code F). For further studies establishing psychiatric diagnosis, standard psychiatric evaluations should include validated structured clinical interviews with standard psychometric measures for psychiatric symptoms and cognitive functioning.

In this article, we aimed to show diagnostic difficulties that psychiatrists encounter diagnosing organic brain disorder. This study demonstrates that psychiatrists should have a high level of alertness in regard to organic brain lesion in psychiatric patients with atypical psychiatric symptoms especially in older population. Evaluation for focal and generalized neurologic symptoms as well as for atypical psychiatric symptoms should be a routine practice setting, and timely diagnostic interventions, such as brain imaging, and reference to neurologist or neurosurgeon must be performed. **CNS**

## REFERENCES

- Jamieson RC, Wells CE. Manic psychosis in a patient with multiple metastatic brain tumors. *J Clin Psychiatry*. 1979;40:280-283.
- Gross RA, Herridge P. A manic like illness associated with right frontal arteriovenous malformation. *J Clin Psychiatry*. 1988;49:119-120.
- Binder RL. Neurologically silent brain tumors in psychiatric hospital admissions: three cases and a review. *J Clin Psychiatry*. 1983;44:94-97.
- Gupta RK, Kumar R. Benign brain tumours and psychiatric morbidity: a 5-years retrospective data analysis. *Aust N Z J Psychiatry*. 2004;38:316-319.
- Uribe VM. Psychiatric symptoms and brain tumor. *Am Fam Physician*. 1986;34:95-98.
- Meyers CA, Hess KR. Multifaceted end points in brain tumor clinical trials: cognitive deterioration precedes MRI progression. *Neuro Oncol*. 2003;5:89-95.
- Moise D, Madhusoodanan S. Psychiatric symptoms associated with brain tumors: a clinical enigma. *CNS Spectr*. 2006;11:28-31.
- Kocher R, Linder M, Stula D. Primary brain tumors in psychiatry [German]. *Schweiz Arch Neurol Neurochir Psychiatr*. 1984;135:217-227.
- Madhusoodanan S, Danan D, Moise D. Psychiatric manifestations of brain tumors: diagnostic implications. *Expert Rev Neurother*. 2007;7:343-349.
- Hollister LE, Boutros N. Clinical use of CT and MR scans in psychiatric patients. *J Psychiatry Neurosci*. 1991;16:194-198.
- The ICD-10 Classification of Mental and Behavioural Disorders: Clinical Descriptions and Diagnostic Guidelines*. Geneva, Switzerland: World Health Organization; 1992.
- DeAngelis LM. Brain tumors. *N Engl J Med*. 2001;344:114-123.
- Gilman S. Imaging the brain. Second of two parts. *N Engl J Med*. 1998;338:889-896.
- Hirayasu Y, Shenton ME, Salisbury DF, et al. Lower left temporal lobe MRI volumes in patients with first-episode schizophrenia compared with psychotic patients with first-episode affective disorder and normal subjects. *Am J Psychiatry*. 1998;155:1384-1391.
- Onitsuka T, Shenton ME, Salisbury DF, et al. Middle and inferior temporal gyrus gray matter volume abnormalities in chronic schizophrenia: an MRI study. *Am J Psychiatry*. 2004;161:1603-1611.
- Kasai K, Shenton ME, Salisbury DF, et al. Progressive decrease of left Heschl gyrus and planum temporale gray matter volume in first-episode schizophrenia: a longitudinal



- nal magnetic resonance imaging study. *Arch Gen Psychiatry*. 2003;60:766-775.
17. Khong SY, Leach J, Greenwood C. Meningioma mimicking puerperal psychosis. *Obstet Gynecol*. 2007;109:515-516.
  18. Harris CP, Townsend JJ, Brockmeyer DL, et al. Cerebral granular cell tumor occurring with glioblastoma multiforme: case report. *Surg Neurol*. 1991;36:202-206.
  19. Maiuri F, Iaconetta G, Sardo L, et al. Peduncular hallucinations associated with large posterior fossa meningiomas. *Clin Neurol Neurosurg*. 2002;104:41-43.
  20. van Breemen MS, Wilms EB, Vecht CJ. Epilepsy in patients with brain tumours: epidemiology, mechanisms, and management. *Lancet Neurol*. 2007;6:421-430.
  21. Wilne SH, Ferris RC, Nathwani A, et al. The presenting features of brain tumours: a review of 200 cases. *Arch Dis Child*. 2006;91:502-506.
  22. Beers MH, Porter RS, eds. *The Merck Manual of Diagnosis and Therapy*. 18th ed. Whitehouse Station, NJ: Merck Research Laboratories; 2006.
  23. Oreskovic NM, Strother CG, Zibners LM. An unusual case of a central nervous system tumor presenting as a chief complaint of depression. *Pediatr Emerg Care*. 2007;23:486-488.
  24. Spence SA, Taylor DG, Hirsch SR. Depressive disorder due to craniopharyngioma. *J R Soc Med*. 1995;88:637-638.
  25. Bostantjopoulou S, Katsarou Z, Petridis A. Relapsing hemiparkinsonism due to recurrent meningioma. *Parkinsonism Relat Disord*. 2007;13:372-374.
  26. Adhiyaman V, Meara J. Meningioma presenting as bilateral parkinsonism. *Age Ageing*. 2003;32:456-458.
  27. Thynne K. Normal pressure hydrocephalus. *J Neurosci Nurs*. 2007;39:27-32.
  28. Vacca V. Diagnosis and treatment of idiopathic normal pressure hydrocephalus. *J Neurosci Nurs*. 2007;39:107-111.
  29. Duinkerke A, Williams MA, Rigamonti D, et al. Cognitive recovery in idiopathic normal pressure hydrocephalus after shunt. *Cogn Behav Neurol*. 2004;17:179-184.
  30. Chaudhry P, Kharkar S, Heidler-Gary J, et al. Characteristics and reversibility of dementia in Normal Pressure Hydrocephalus. *Behav Neurol*. 2007;18:149-158.
  31. Iddon JL, Pickard JD, Cross JJ, et al. Specific patterns of cognitive impairment in patients with idiopathic normal pressure hydrocephalus and Alzheimer's disease: a pilot study. *J Neurol Neurosurg Psychiatry*. 1999;67:723-732.
  32. Thomann PA, Wustenberg T, Pantel J, et al. Structural changes of the corpus callosum in mild cognitive impairment and Alzheimer's disease. *Dement Geriatr Cogn Disord*. 2006;21:215-220.
  33. Frisoni GB, Testa C, Zorzan A, et al. Detection of grey matter loss in mild Alzheimer's disease with voxel based morphometry. *J Neurol Neurosurg Psychiatry*. 2002;73:657-664.
  34. Chaim TM, Duran FL, Uchida RR, et al. Volumetric reduction of the corpus callosum in Alzheimer's disease in vivo as assessed with voxel-based morphometry. *Psychiatry Res*. 2007;154:59-68.
  35. Mainio A, Hakko H, Niemelä A, et al. The effect of brain tumour laterality on anxiety levels among neurosurgical patients. *J Neurol Neurosurg Psychiatry*. 2003;74:1278-1282.
  36. Pringle AM, Taylor R, Whittle IR. Anxiety and depression in patients with an intracranial neoplasm before and after tumour surgery. *Br J Neurosurg*. 1999;13:46-51.



MOUNT SINAI  
SCHOOL OF  
MEDICINE

Now Available Online at [www.cnspectrums.com](http://www.cnspectrums.com)

*An expert review of clinical challenges in neurology and psychiatry*


## **Alzheimer's Disease Summit: Translating Research Advances into Clinical Practice**

by Jeffrey L. Cummings, MD, Ziad Nasreddine, MD, Kathleen Welsh-Bohmer, PhD, Ellen Woo, PhD, Liana G. Apostolova, MD, Mark A. Mintun, MD, Elaine R. Peskind, MD, Gary W. Small, MD, Rachelle S. Doody, MD, PhD, Paul S. Aisen, MD, Norman R. Relkin, MD, PhD, Mary Sano, PhD, and Russell Katz, MD

To request a print supplement, please e-mail [ks@mbcommunications.com](mailto:ks@mbcommunications.com)

Supported by educational grants from Forest Pharmaceuticals, Inc., Eisai Inc., Medivation, Inc., and Elan Pharmaceuticals, Inc.

From the Publishers of Primary Psychiatry, CNS Spectrums, and Psychiatry Weekly



Now Available - Expert Panel CME Podcasts:

# ALZHEIMER'S DISEASE SUMMIT (ADS)

Downloadable CME PsychCasts Available Free @  
<http://cmepsychcast.mblcommunications.com> and on iTunes "Science and Medicine"

Jointly sponsored by The Mount Sinai School of Medicine and MBL Communications, Inc.

## **"Advances in Clinical Assessment"**

Ziad Nasreddine, MD, Kathleen A. Welsh-Bohmer, PhD, and Ellen Woo, PhD

## **"Advances in Neuroimaging and Biomarkers"**

Liana G. Apostolova, MD, Mark A. Mintun, MD, and Elaine R. Peskind, MD

## **"Current Alzheimer's Disease Therapy: Best Practices"**

Jeffrey L. Cummings, MD, Gary W. Small, MD, and Rachele S. Doody, MD, PhD

## **"The Future of Alzheimer's Disease Therapeutics"**

Paul S. Aisen, MD, Norman R. Relkin, MD, PhD, and Mary Sano, PhD

Funding for these podcasts has been provided by educational grants from Forest Pharmaceuticals, Inc., Eisai Inc., Medivation, Inc., and Elan Pharmaceuticals, Inc.

CME 4



PRIMARY PSYCHIATRY  
The Largest Peer-Reviewed Psychiatric Journal in the Nation

CNS SPECTRUMS  
The International Journal of Neuropsychiatric Medicine

Psychiatry Weekly  
The Leading News Service from Primary Psychiatry and Physician's Weekly

ADS  
ALZHEIMER'S DISEASE SUMMIT

