

## LETTER TO THE EDITOR

**Repeated embolism and multiple aneurysms: central nervous system manifestations of cardiac myxoma**Q. Li<sup>a</sup>, H. Shang<sup>a</sup>, D. Zhou<sup>a</sup>, R. Liu<sup>b</sup>, L. He<sup>a</sup> and H. Zheng<sup>a</sup><sup>a</sup>Department of Neurology, West China Hospital, Sichuan University, China; and<sup>b</sup>Department of Radiology, West China Hospital, Sichuan University, China

Correspondence: Dr Hongbo Zheng and Dr Li He, Department of Neurology, West China Hospital, Sichuan University, Guoxuexiang No. 37, 610041 Chengdu, China (fax: +8628 8542 3550; e-mail: drzhenghb@126.com and heli2003new@126.com).

**Keywords:** echocardiography, intracranial aneurysm, intracranial embolism, myxoma

Received 19 March 2008

Accepted 1 July 2008

Acute cerebral embolism of left atrial myxomas has been well documented, but cerebral aneurysm formation resulting from atrial myxoma is a rare neurological manifestation. We describe here a patient whose left atrial myxoma and multiple cerebral aneurysms were identified after multiple cerebral embolisms during a 5-year period.

A 27-year-old woman was admitted to our hospital with a sudden onset of vertigo, dysarthria and right-sided weakness. The patient reported a history of a sudden fall with loss of consciousness and left-sided hemiplegia at the age of 22. At that time, she was diagnosed at a local hospital with multiple cerebral infarctions

because of magnetic resonance imaging (MRI) evidence of multiple ischaemic lesions in the cerebellum, brain stem and basal ganglia (Fig. 1a and b). Echocardiography was not performed at the local hospital because of the patient's absence of any history or signs of cardiac problems. The patient fully recovered within 6 months and had no residual symptoms. However, the patient experienced two episodes of vertigo and right-sided weakness in the past 5 years. Each episode lasted 5–10 min and resolved spontaneously. No conventional vascular risk factors, stroke family history or contraceptive drug administration were reported.

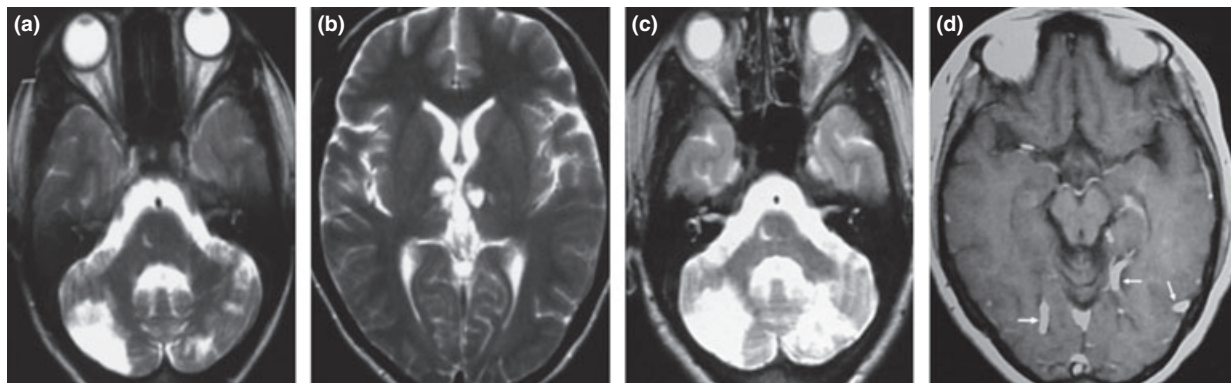
In our hospital, abnormal neurological signs in the patient included pathological laughing, scanning speech, muscle strength of right limbs: 3 (strength: 3/6 grade), hyperreflexia of the right deep tendon reflex and increased muscle tone in the right limbs presenting as spasticity and an ataxic gait. A cardiology consult revealed that the patient had a regular heart rate and rhythm, with no audible murmurs on auscultation. An electrocardiography demonstrated no abnormality as well. Laboratory tests were remarkable only for increased erythrocyte sedimentation (28.0 mm/h, reference: 0–20 mm/h) and C-reactive protein (5.63 mg/l, reference 0–5 mg/l). Clinical immunology studies, examination of the serum for syphilis and lumbar puncture revealed no abnormalities. A MRI scan disclosed an additional infarcted lesion in the left cerebellar hemisphere in addition to the previous lesions (Fig. 1c). A T1-weighted MRI with contrast showed marked dilated arteries enhanced with gadolinium–DTPA

in the posterior cerebral artery territories (Fig. 1d). Echocardiography revealed a pedunculated mass originating from the left atrium through the mitral valve into the left ventricle. Angiography disclosed multiple typical distal fusiform and saccular aneurysms or aneurysmal dilations in the bilateral internal carotid artery territories (Fig. 2a and b), as well as a marked enlargement of the proximal portion of the bilateral branch of the posterior cerebral arteries (Fig. 2c). Clinical and laboratory investigations including abdominal ultrasonography, chest radiography and vascular ultrasonography of the cervical and extremities did not reveal an aneurysm of the extra-cerebral arteries.

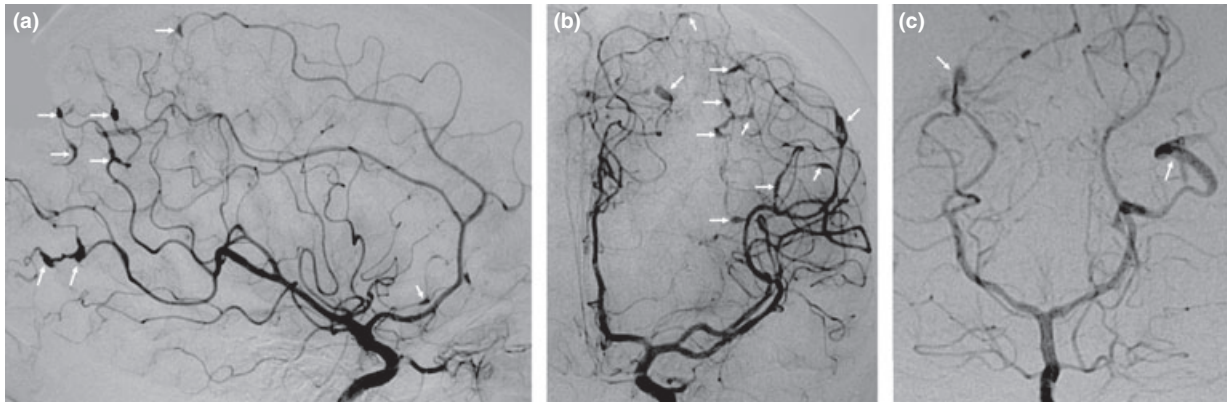
The patient was then referred to the cardiosurgery department for a thoracotomy. Pathological analysis disclosed that the resected atrial mass, measuring 4 × 3 × 3 cm, was a typical myxoma. After surgery, the patient was discharged from the hospital without any specific treatment. No neurological symptoms reoccurred during 2 years of follow-up study. No myxoma was revealed during repeat echocardiographical investigation. Careful follow-up including MRI and angiography will still be continued for both recurrence and progression or regression of cerebral aneurysms.

**Discussion**

The patient described herein presented with repeat posterior circulation embolisms, which were diagnosed based on objective evidence and the patient's clinical history. We suggested that the stroke was due to the tumour fragments or



**Figure 1** T2-weighted magnetic resonance imaging (MRI) shows multiple infarcted lesions in pons and cerebellum (a) as well as basal ganglia (b) at the first stroke. A new infarct lesion in the left cerebellum hemisphere (c) was disclosed by T2-weighted MRI; tubular dilated arteries (arrows) in posterior cerebral artery territories were revealed by T1-weighted MRI following gadolinium–DTPA administration (d) after 5 years.



**Figure 2** Digital subtraction angiography shows numerous fusiform and saccular aneurysms or irregular aneurismal dilatation of the branches of internal carotid arteries (ICA) and the proximal portion of the bilateral posterior cerebral arteries. (a: right-sided ICA, lateral view; b: left-sided ICA, anterior view; c: vertebral artery, anterior view).

adherent thrombus since no other stroke risk factors or alternate aetiology were found. This conclusion was also supported by the fact that no neurological symptoms recurred after removal of the atrial myxoma. However, echocardiography was not performed for the patient and atrial myxoma as the cause of the stroke was delayed for 5 years after the first stroke episode. Therefore, physicians should be aware of cardiac embolic sources in young patients with cerebral embolism, even in the absence of cardiac auscultation abnormalities, because approximately one-third of patients with atrial myxoma lack cardiac signs [1]. Echocardiography should be ordered routinely for stroke patients because of its high sensitivity for cardiac myxoma.

Despite the lack of pathological evidence we speculate that the patient experienced multiple intracranial aneurysms associated with myxoma, because other underlying cause of aneurysms was excluded. The characteristics of multiple, distal cerebral aneurysms in this patient

were in agreement with those reported previously [2], some of which had myxoma cells in the wall of the aneurysms, which was determined by histopathological studies [3]. However, the number of distal cerebral aneurysms in our patients were extremely striking and larger than those reported previously (range: 1–8, mean: 3) [3], up to eighteen. In particular, it is rare that fusiform and saccular aneurysms occur concurrently in one patient [3]. The natural history of myxomatous aneurysms is not well characterized. Josephson [4] reported one patient with myxomatous aneurysms that had been stable, with the patient remaining asymptomatic for 8 years. Our patient had no signs of intracranial bleeding and no component of the aneurysm was suitable for resection. The surgical treatments or biopsy for these multiple small aneurysms may be particularly risky. Without any further treatment, the patient remained asymptomatic for 2 years after resection of the atrial myxoma. We recommend a long-term follow-up plan for patients with

myxomatous aneurysms; enlarged aneurysms or intracranial bleeding may require invasive management. Echocardiographical investigations for cardiac myxoma will also be performed as a part of the follow-up plan.

#### References

1. Pinede L, Duhaut P, Loire R. Clinical presentation of left atrial cardiac myxoma. A series of 112 consecutive cases. *Medicine* 2001; **80**: 159–172.
2. Sabolek M, Bachus-Banaschak K, Bachus R, Arnold G, Storch A. Multiple cerebral aneurysms as delayed complication of left cardiac myxoma: a case report and review. *Acta Neurologica Scandinavica* 2005; **111**: 345–350.
3. Jean WC, Walski-Easton SM, Nussbaum ES. Multiple intracranial aneurysms as delayed complications of an atrial myxoma: case report. *Neurosurgery* 2001; **49**: 200–202.
4. Josephson SA, Johnston SC. Multiple stable fusiform intracranial aneurysms following atrial myxoma. *Neurology* 2005; **64**: 526.