

5. Meneveau N, Bassand JP, Schiele F et al. Safety of thrombolytic therapy in elderly patients with massive pulmonary embolism: A comparison with non-elderly patients. *J Am Coll Cardiol* 1993;22:1075–1079.
6. Gisselbrecht M, Diehl JL, Meyer G et al. Clinical presentation and results of thrombolytic therapy in older patients with massive pulmonary embolism: A comparison with non-elderly patients. *J Am Geriatr Soc* 1996;44:189–193.
7. Kucher N, Rossi E, De Rosa M et al. Massive pulmonary embolism. *Circulation* 2006;113:577–582.
8. Wan S, Quinlan DJ, Agnelli G et al. Thrombolysis compared with heparin for the initial treatment of pulmonary embolism. *Circulation* 2004;110:744–749.
9. Fijalkowska A, Kurzyna M, Torbicki A et al. Serum N-terminal brain natriuretic peptide as a prognostic parameter in patients with pulmonary hypertension. *Chest* 2006;129:1313–1321.
10. O'Donnell S, Cranney A, Wells GA et al. Strontium ranelate for preventing and treating postmenopausal osteoporosis. *Cochrane Database Syst Rev* 2006; (3):CD005326.

EXTENSIVE INTRACRANIAL MICROBLEEDS IN TRANSTHYRETIN AMYLOIDOSIS

To the Editor: A 68-year-old right-handed woman with a past medical history of a stroke (left putamen hemorrhage with residual right hemiparesis), hypertension, diabetes mellitus, hyperlipidemia, and moderate dementia presented to the emergency department after having been found unresponsive at a nursing home. She was observed to have three generalized tonic clonic seizures in rapid succession and was sent to the hospital. No head trauma was noted. Her medications included metoprolol and baclofen. Initial examination revealed an elderly woman with a blood pressure of 198/59 mmHg who was easily arousable but followed no commands. Cranial nerve examination was significant for right nasolabial fold flattening. There was increased tone in her right arm and leg. She moved her extremities against gravity but to a lesser extent on the right. Deep tendon reflexes were 2+ throughout, with extensor plantar responses.

She was initially loaded with intravenous fosphenytoin and had no seizure recurrence. A computed tomography scan was performed, revealing subarachnoid hemorrhage in the left postcentral sulcus (Figure 1A). Her international normalized ratio (INR) was 1.0, with a platelet count of 227,000/ μ L. She was admitted to the intensive care unit, and her blood pressure was controlled with intravenous nicardipine. An electroencephalogram revealed continuous left hemispheric polymorphic slowing, and she had no subsequent seizures while in the hospital. Her mental status improved to the extent that she was awake, oriented to the hospital, and following requests, but she had significant deficits in memory and was prominently abulic. Magnetic resonance imaging (MRI) of the brain was performed, revealing localized subarachnoid hemorrhage as above and evidence of extensive cerebral microbleeds (Figure 1B–D). Magnetic resonance angiography (MRA) was normal. A serological workup for vasculitis was unrevealing, and she had a normal transthoracic echocardiogram. A lower extremity duplex ultrasound showed an acute left common femoral vein thrombosis, and an inferior vena cava filter was placed. She was discharged on phenytoin at her baseline mental status.

As an outpatient, she was transitioned from phenytoin to levatiracetam without complications. Fifteen months later, she again presented to the hospital with seizures. A lumbar puncture was performed, showing normal cerebro-

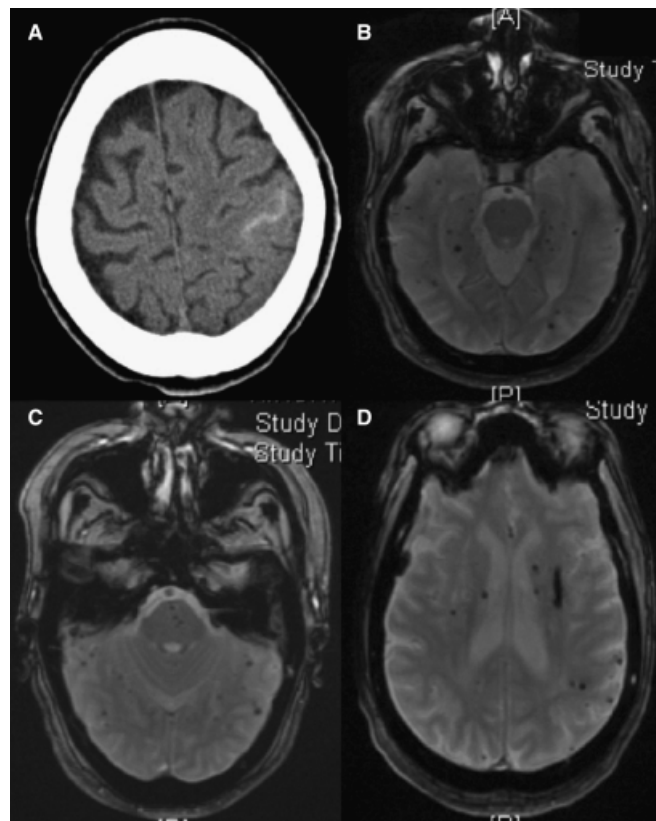


Figure 1. Computed tomography and magnetic resonance imaging of the brain. (A) Computed tomography scan demonstrating subarachnoid hemorrhage in the left postcentral sulcus. (B–D) Magnetic resonance image gradient-echo sequences revealing multiple foci of parenchymal microhemorrhage, as well as a slit-like lesion in the left putamen (D) corresponding to the patient's initial stroke.

spinal fluid. She improved with an increase of her levatiracetam dose. Repeat MRI and MRA were unchanged, but genetic testing was done for evaluation of cerebral autosomal dominant arteriopathy with subcortical infarcts and leukoencephalopathy (CADASIL) and amyloidosis. She tested positive for a point mutation in the transthyretin gene (codon 122, valine to isoleucine). She was maintained off antiplatelet and anticoagulant agents.

Cerebral microhemorrhages are defined as smaller than 5-mm rounded foci of intraparenchymal blood with residual hemosiderin that appear as hypointense lesions on gradient-echo sequence of MRI.¹ Two important diseases that are considerations in patients with cerebral microhemorrhages are CADASIL and amyloid angiopathy. In this patient, CADASIL was excluded using genetic testing, because she did not have the *Notch3* mutation. Amyloid angiopathy was a strong consideration in this patient with dementia, deep subcortical and superficial hemorrhagic strokes, and widespread microhemorrhages. Studies investigating the prevalence of microbleeds in various populations reveal a higher percentage in patients with clinically diagnosed dementia; conversely, patients with lobar hemorrhage and microbleeds have a much greater prevalence of executive dysfunction, cognitive decline, functional dependence, and death than do patients with lobar hemorrhage without microbleeds.²

Amyloidosis related to mutations in the transthyretin gene now has a well-described phenotype called oculoleptomeningeal amyloidosis, first described in 1980.³ The central nervous system manifestations of this disorder include leptomeningeal hemorrhage (occasionally leading to hydrocephalus, superficial siderosis), dementia, ataxia, spasticity, and seizures.^{4–6} The majority of these patients have retinal and vitreous hemorrhages as well.

This patient had a mutation in codon 122, which has previously been described in African-American patients in the southern United States.⁷ It has been associated with cardiomyopathy and peripheral neuropathy. There have been no descriptions of this particular mutation with cerebrovascular disease.

One limitation is that the patient's prior left putamen hemorrhage may be more related to small vessel lipohyalinosis than to amyloidosis, because she had longstanding vascular risk factors, but it is possible that the two etiologies are synergistic. In addition, it was not possible to locate family members with knowledge of any family history of dementia, stroke, or other neurological syndromes associated with amyloidosis.

To our knowledge, this is the first case of a patient with widespread cerebral microhemorrhages found to have transthyretin amyloidosis, but as genetic testing becomes a more-widespread tool in establishing an etiology in dementia, it is likely that the hereditary predisposition to cerebral microhemorrhages will be further elucidated.

Matthew S. Robbins, MD

Jay Yasen, MD

Department of Neurology

Albert Einstein College of Medicine

Bronx, NY

ACKNOWLEDGMENTS

Conflict of Interest: No financial support received. No conflict of interest.

Author Contributions: Dr. Robbins was involved in identifying the subject, designing report, interpretation of data, and preparation of manuscript. Dr. Yasen was involved in identifying subject, designing report, interpretation of data, and preparation of manuscript.

Sponsor's Role: No sponsors.

REFERENCES

1. Viswanathan A, Chabriat H. Cerebral microhemorrhages. *Stroke* 2006;37:550–555.
2. Koenneke H. Cerebral microbleeds on MRI. Prevalence, associations, and potential clinical implications. *Neurology* 2006;66:165–171.
3. Goren H, Steinberg MC, Farboody GH. Familial oculoleptomeningeal amyloidosis. *Brain* 1980;103:473–495.
4. Benson MD. Leptomeningeal amyloid and variant transthyretins. *Am J Pathol* 1996;148:351–354.
5. Nakamura M, Yamashita T, Ueda M et al. Neuroradiologic and clinicopathologic features of oculoleptomeningeal type amyloidosis. *Neurology* 2005;65:1051–1056.
6. Petersen RB, Goren H, Cohen M et al. Transthyretin amyloidosis: A new mutation associated with dementia. *Ann Neurol* 1997;41:307–313.
7. Jacobson DR, Reveille JD, Buxbaum JN. Frequency and genetic background of the position 122 (Val-Ile) variant transthyretin gene in the black population. *Am J Hum Genet* 1991;49:192–198.

INTENSITY OF ANTICOAGULATION IN OCTOGENARIANS WITH NONVALVULAR ATRIAL FIBRILLATION

To the Editor: The intensity of anticoagulation currently used for octogenarians^{1,2} and for patients aged 76 and older (mean age 81.5)³ with nonvalvular atrial fibrillation (NVAF) might be a strategy of high risk and low benefit. This intensity of anticoagulation, characterized by an international normalized ratio (INR) of 2 to 3, is the optimum one for patients aged 18 and older with NVAF.⁴ Evidence that this may be inappropriate for octogenarians comes from a study that enrolled 427 subjects aged 65 and older (including 153 aged ≥ 80) with NVAF who were anticoagulated to a target INR of 2 to 3. In that study, patients aged 80 and older experienced significantly more ($P = .01$) episodes of severe hemorrhage than their younger counterparts.² Given the fact that hemorrhagic risk is positively correlated with intensity of anticoagulation,⁵ fewer hemorrhagic episodes might have occurred had lower intensities of anticoagulation been used, as in the earlier studies that documented the efficacy of warfarin in preventing NVAF-related stroke.^{6,7} One such study was the Boston Area Anticoagulation Trial for Atrial Fibrillation (BAATAF), in which 32 of 404 participants were aged 80 and older, and the target INR was 1.5 to 2.7. In that study, warfarin was found to confer a 2.3% per year absolute reduction in the risk of NVAF-related stroke. This was associated with only two major hemorrhagic events (one of them intracranial) in 212 warfarin-treated patients and one major extracranial hemorrhagic event in 208 patients assigned to placebo.⁶ Comparable prophylactic benefit was documented in the Stroke Prevention in Nonrheumatic Atrial Fibrillation (SPINAF) study, in which a target INR of 1.4 to 2.8 was found to confer a 3.3% per year absolute reduction in the risk of NVAF-related stroke. Unlike the BAATAF, in which patients taking regular aspirin medication contributed 46% of all the patient-years in the control group, none of the SPINAF participants were taking aspirin.⁷ These results^{6,7} compared favorably with those obtained in the Copenhagen Atrial Fibrillation, Aspirin and Anticoagulant Therapy Study, in which the much higher target INR of 2.8 to 4.2 was found to confer an absolute reduction of 2.6% per year in the risk of stroke.⁸ Only in the Stroke Prevention in Atrial Fibrillation 1 Study was a comparable intensity of anticoagulation, namely an INR 2 to 4.5, found to confer a greater reduction in the risk of stroke. In that trial, of the 421 participants in the warfarin or placebo group, eight of those allocated to warfarin were aged 76 and older, and eight of those allocated to placebo were aged 76 and older. The absolute reduction in stroke risk was 4.7% per year.⁹ Three “relevant” hemorrhagic episodes (2 of them intracranial) occurred in 210 patients on warfarin, and only one intracranial hemorrhagic episode occurred in the 211 patients assigned to placebo.⁹ In the absence of a prospective study of low-intensity anticoagulation (INR 1.4–2.8) in subjects aged 80 and older, a comparison of beneficial outcomes of low-intensity anticoagulation (target INR 1.5–2.7) in trials such as BAATAF,⁶ in which some of the participants were aged 80 and older, and the adverse outcomes when subjects in that age group were anticoagulated to the higher target INR of 2 to 3,²