

Differential Hand-neglect After a Callosal Lesion

Michitaka Funayama, MD,* Taro Muramatsu, MD,† and Motoichiro Kato, MD†

Background: The relationship between hemispatial neglect and callosal lesions is not fully understood.

Method: A 74-year-old woman exhibited destruction of the posterior part of the genu and the entire truncus of the corpus callosum and a part of the right cingulate sulcus after infarction of the right pericallosal artery.

Results: Three years after the infarction, severe left-sided unilateral spatial neglect was noted for the right hand and mild right-sided unilateral spatial neglect for the left hand.

Conclusions: These findings are consistent with the model of right hemisphere dominance for spatial attention. The corpus callosum lesion itself could have been responsible for the patient's disconnection neglect.

Key Words: unilateral spatial neglect, corpus callosum, disconnection, right hemisphere

(*Cog Behav Neurol* 2008;21:246–248)

Clinical evidence has shown that neglect is more frequent and severe after right hemisphere lesions than after equivalent lesions in the left hemisphere, which leads to the hypothesis that the left hemisphere attends to contralateral stimuli, whereas the right hemisphere attends to both contralateral and ipsilateral stimuli.^{1,2} Another influential hypothesis is that of Kinsbourne's, which proposes that the hemispheres operate with opposing attentional vectors and also inhibit the other.^{3–5} Furthermore, the left has a strong contralateral bias, and the right a weak one.⁵

Consistent with these hypotheses, unilateral intra-carotid amytal injections lead to contrainjection visual neglect only after inactivation of the right hemisphere.⁶ Findings of this sort regarding the capabilities of single hemispheres is crucial in understanding cognitive asymmetry, though relatively few have been obtained.

In the neuropsychologic literature, studies of patients with split brains, due either to surgery or injury, have greatly contributed to understanding of the specia-

lized cognitive functions of each hemisphere. For example, patients with callosal lesions demonstrate left-hand (controlled by linguistically nondominant hemisphere) agraphia, tactile anomia, and other related conditions. As such, a lesion of the corpus callosum which leaves the hemispheres intact offers a unique opportunity to observe the attentional capacity of each hemisphere in isolation, as each is obliged to function on its own. Although an unusual form of neglect has been reported in patients after callosal injury,^{7–9} each hemisphere's function has been separately investigated in only a few cases, for example, the patient described by Kashiwagi et al,¹⁰ who demonstrated left hemispatial neglect confined to the right hand.

We describe a new case of neglect, in which the major lesions were limited to the corpus callosum and right cingulate cortex. Detailed analysis of the signs and symptoms revealed differential hand-neglect, with severe left-sided unilateral spatial neglect (USN) noted for the right hand and mild right-sided USN for the left hand. These findings seem to demonstrate predominance of spatial attention and a bias slightly to the left in the right hemisphere and a bias to the right in the left hemisphere.

CASE REPORT

The patient was a 74-year-old right-handed female with 10 years of education. Her school record was average. She had no history of neurologic or psychiatric disorders. In September 2000, at the age of 71, she developed acute disconnection syndrome, such as mutism and disuse of the left hand. T1-weighted contrast magnetic resonance image (Fig. 1) demonstrated lesions in the posterior part of the genu and the entire truncus of the corpus callosum and a part of the right cingulate sulcus, consistent with infarction of the right pericallosal artery. She recovered from acute disconnection syndrome after a few weeks. The visual field on confrontation testing and sensation were normal, and no paralysis or ataxia was found. However, her dyslexia and dysgraphia have persisted.

Neuropsychologic tests were performed in September 2003, 3 years after onset. She gave her informed consent before her inclusion in the study. No aphasia or visual agnosia was found. A callosal syndrome was noted, including apraxia and tactile anomia in the left hand and constructional disability in the right hand and lack of interhemispheric transfer including crossed point localization, crossed tactile object identification, and cross-replication of hand posture.

A marked left-sided USN was found in the revised visual retention test (Benton), the visual memory span in the Wechsler Memory Scale-Revised and the Rey-Osterrieth Complex Figure Test, and the Block design in the Wechsler Adult Intelligence Scale-Revised when the right hand was used for performance. In the Trail Making Test, Trail A was performed with the right

Received for publication February 14, 2008; accepted July 2, 2008.

From the *Department of Neuropsychiatry, Ashikaga Red Cross Hospital, Tochigi; and †Department of Neuropsychiatry, Keio University School of Medicine, Tokyo, Japan.

Reprints: Michitaka Funayama, MD, Department of Neuropsychiatry, Ashikaga Red Cross Hospital, 3-2100 Honjo, Ashikaga-City, Tochigi 3260808, Japan (e-mail: Fimndia@aol.com).

Copyright © 2008 by Lippincott Williams & Wilkins

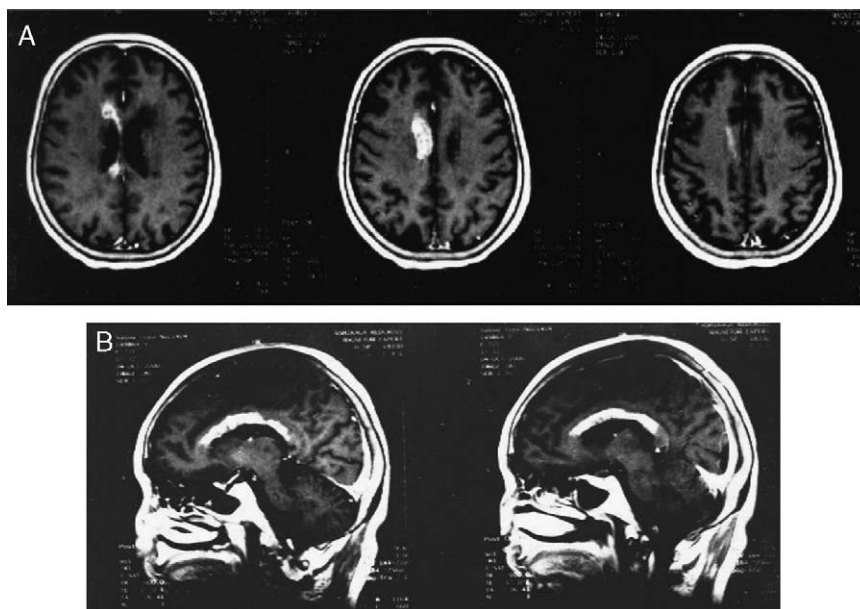


FIGURE 1. T1-weighted magnetic resonance image. T1-weighted magnetic resonance image of the patient, showing lesions in the posterior part of the genu and entire truncus of the corpus callosum and a part of the right cingulate sulcus. A, Axial section (right brain on left side); B, Sagittal section.

hand first and with the left hand 1 month later. The test took 12 minutes 20 seconds with the right hand and 6 minutes 25 seconds with the left hand. The areas difficult to find (requiring more than 30 s) were the left space with the right hand and the right lower space, though small, with the left hand. When asked to read Chinese characters (kanji) or numbers, she read out only the right half of the character and neglected the left half. When asked to write a Chinese character, she omitted the left half.

METHODS

Conventional neuropsychologic tests revealed that the patient had hemispatial neglect. To characterize her neglect in greater detail, the BIT (Behavioral Inattention Test)¹¹ Japanese version¹² was performed. Though this test consists of the conventional test and the behavioral test, we used only the former, which can be performed with each hand separately. The line bisection subtest of the BIT was performed 10 times each with the right and left hand alternately, and other subtests were performed with the right hand, left hand, right hand, left hand, and right hand, for a total of 5 times every month beginning September 2003. Five healthy females (mean age, 75.2 ± 3.6) also participated in the cancellation and line bisection subtests of BIT as control subjects.

RESULTS

For the right hand, severe leftward neglect, but not rightward neglect, was noted. In contrast, mild rightward neglect, but not leftward neglect, was noted for the left hand, as demonstrated by the scores of the Line Cancellation Test (right hand: 28, 36, 36; left hand: 36, 36, full score 36; controls: right hand 35.8 ± 0.4 , left hand 35.4 ± 1.3), Letter Cancellation Test (right hand: 24, 22,

23; left hand: 29, 36, full score 40; controls: right hand 37.8 ± 2.9 , left hand 38.4 ± 1.5), and the Star Cancellation Test (right hand: 25, 37, 36; left hand: 51, 54, full score 54; controls: right hand 52.4 ± 1.5 , left hand 53.4 ± 0.9). Figure 2 shows the results of the Line Bisection Test, which clearly demonstrated the tendency mentioned above in all 3 positions. A statistically significant difference (*T* test, $P < 0.05$) between the patient and each control were found in all positions, except for the left position of line on page with the left hand. In the Figure Copying Test and Drawing Pictures, the right hand misdrew the figures with defects on the left side of the figure. The patient did not copy figures satisfactorily with the left hand due to the apraxia.

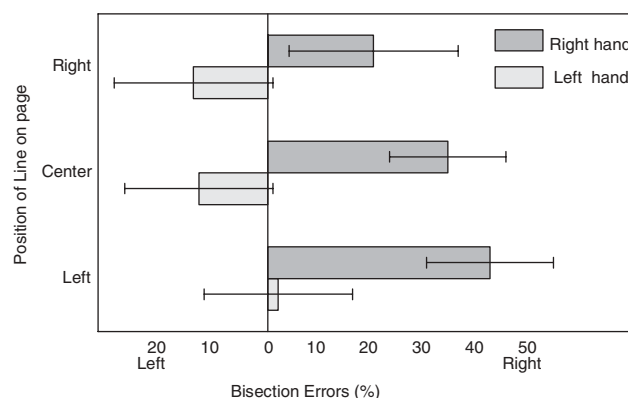


FIGURE 2. Bisection errors. Mean bisection errors on the line bisection subtest of the Behavioral Inattention Test. The horizontal lines to be bisected were positioned in the center, or to the left or right, of an A4 sheet of paper.

DISCUSSION

In this patient, neuropsychologic examinations demonstrated continued loss of interhemispheric transmission as a result of callosal disconnection, with each hemisphere obliged to function on its own in certain tasks. Thus, the rationale of our experimental investigation was as follows: She would have to depend predominantly on the left hemisphere when right-hand performance was required. In this condition, only right-sided attention of the left hemisphere is activated while bilateral attention of the right hemisphere is inhibited, resulting in leftward neglect. By the same logic, she must depend on the right hemisphere when left-hand performance is required. In this condition, right-sided attention of the left hemisphere is inhibited and only bilateral attention of the right hemisphere is activated, though the right hemisphere attends preponderantly to contralateral left hemispace, resulting in mild rightward neglect. Notably, these conditions are compatible with Kinsbourne's view³⁻⁵: The callosal disconnection would prevent cross-hemispheric inhibition, releasing the left hemisphere's strongly directed attention and the right hemisphere's weakly directed attention.

Consistent with this hypothesis, neuropsychologic investigation of the patient revealed differential hand-neglect, with severe left-sided USN noted for the right hand and mild right-sided USN for the left hand. Specifically, in the BIT battery, each subtest performance consistently showed right-hand neglect and milder neglect in left hand. Results of quantitative analysis of the Line Bisection Test were consistent with this (Fig. 2). These findings support the hypothesis that the left hemisphere attends only to the contralateral hemispace, whereas the right hemisphere attends to both sides of space, though preponderantly to the contralateral hemispace.

The involvement of the corpus callosum in neglect syndrome is still controversial. In patients who have undergone callosotomy, neglect is observed only in the early postoperative period.¹³ By contrast, persistent symptoms of neglect have been observed in some patients with lesions of the corpus callosum due to hemorrhage or infarction in the anterior cerebral artery territory.⁷⁻⁹ In general, patients with neglect improve over a period of weeks and months. This is probably because the patient's uninjured hemisphere (either right or left) is able to compensate for the loss of function. Concerning factors related to the extent of recovery, Levine et al¹⁴ suggested the importance of premorbid atrophy and/or lesion size. Consistent with this, Novelly and Lifrak¹³ indicated that USN can be an important and even persistent symptom after callosotomy, particularly in certain patients with prior focal disease. This suggests that the cingulate lesion in our patient may have contributed to the persistence of neglect syndrome. Moreover, it can be argued that our patient's neglect was caused by her cingulate lesion.

Nevertheless, it seems difficult to ascribe her differential hand-neglect to the cingulate lesion alone, that is, aside from the left hemispatial neglect observed in right-hand performance, right hemispatial neglect observed in left-hand performance cannot be attributed to the right cingulate lesion. Only disconnection due to the lesion in the corpus callosum clearly explains her neglect as a whole.

Some authors have considered callosal neglect a consequence of disconnection, with the report by Kashiwagi et al¹⁰ in particular worth mentioning. In their patient, left USN was invariably demonstrated in right-hand performance despite left frontal damages. In contrast, little or no right USN was demonstrated in tasks performed with the left hand. They therefore concluded that their patient's USN was evidence of disconnection. Our findings in part replicated but also extended theirs. The conclusion they drew was that USN was attributable to a combination of lesions in the corpus callosum and the left medial frontal lobe. That portion of frontal cortex was intact in our patient, suggesting that the corpus callosum lesion by itself could have been responsible for the disconnection neglect. Moreover, the quantitative analysis we performed clearly indicated that spatial attention is differently represented in the 2 hemispheres.

REFERENCES

1. Heilman KM, Van den Abell T. Right hemisphere dominance for attention: the mechanism underlying hemispheric asymmetries of inattention (neglect). *Neurology*. 1980;30:327-330.
2. Mesulam M-M. A cortical network for directed attention and unilateral neglect. *Ann Neurol*. 1981;10:309-325.
3. Kinsbourne M. A model for the mechanism of unilateral neglect of space. *Trans Am Neurol Assoc*. 1970;95:143-146.
4. Kinsbourne M. The cerebral basis of lateral asymmetries in attention. *Acta Psychol*. 1970;33:193-201.
5. Kinsbourne M. Hemi-neglect and hemisphere rivalry. *Adv Neurol*. 1977;18:41-49.
6. Spiers PA, Schomer DL, Blume HW, et al. Visual neglect during intracarotid amobarbital testing. *Neurology*. 1990;40:1600-1606.
7. Goldenberg G. Neglect in a patient with partial callosal disconnection. *Neuropsychologia*. 1986;24:397-403.
8. Heilman KM, Bowers D, Watson RT. Pseudoneglect in patients with partial callosal disconnection. *Brain*. 1984;107:519-532.
9. Heilman KM, Adams DJ. Callosal neglect. *Arch Neurol*. 2003;60:276-279.
10. Kashiwagi A, Kashiwagi T, Nishikawa T, et al. Hemispatial neglect in a patient with callosal infarction. *Brain*. 1990;113:1005-1023.
11. Wilson B, Cockburn J, Halligan PW. *The Behavioural Inattention Test*. Bury St. Edmunds, UK: Thames Valley Test Company; 1987.
12. Ishiai S. *Behavioural Inattention Test*. Tokyo: Shinkoigaku-shuppansha; 1999. Japanese version.
13. Novelly RA, Lifrak MD. Forebrain commissurotomy reinstates effects of preexisting hemisphere lesions. In: Reeves AG, ed. *Epilepsy and the Corpus Callosum*. New York: Plenum Publishing Corporation; 1985:467-500.
14. Levine DN, Warach JD, Benowitz L, et al. Left spatial neglect: effects of lesion size and premorbid brain atrophy on severity and recovery following right cerebral infarction. *Neurology*. 1986;36:362-366.