

## Cerebral Dural Sinus Thrombosis

*Cerebral dural sinus thrombosis is an unusual syndrome in which a patient presents with a severe headache that may be associated with diverse neurologic and physical findings. The case of a 31-year-old woman with headache, vomiting, generalized tonic-clonic seizure, and subsequent dense hemiplegia is presented. The patient was diagnosed as having a cerebral dural sinus thrombosis, but only after the diagnosis was missed initially. The syndrome may be difficult to detect because it can mimic several other entities. There are several known or suspected predisposing factors. The syndrome, diagnostic modalities, and therapeutic options are reviewed. [Pannke TS: Cerebral dural sinus thrombosis. Ann Emerg Med July 1991;20:813-816.]*

Thomas S Pannke, MD  
Peoria, Illinois

From the Emergency Medicine Residency Program, University of Illinois College of Medicine at Peoria.

Received for publication August 21, 1990.  
Revision received February 5, 1991.  
Accepted for publication February 18, 1991.

### INTRODUCTION

Severe headache represents a fairly common complaint among emergency department patients. Patients with the history of "migraines" are seen frequently. Careful history will usually allow differentiation between the patient's usual headache and more serious headaches. Cerebral dural sinus thrombosis (CDST) is an uncommon syndrome that can cause severe headache. The presentation of the disease can vary from headache alone to generalized seizures followed by focal deficits. There are several known or suspected predisposing factors. The case of a 31-year-old woman with a history of migraine whose course with CDST was fairly typical is presented, illustrating some of the possible clinical presentations as well as a successful treatment plan.

Address for reprints: Thomas S Pannke, MD, University of Illinois College of Medicine at Peoria, Emergency Medicine Residency Program, St Francis Medical Center, 530 Northeast Glen Oak, Peoria, Illinois 61637.

### CASE REPORT

A 31-year-old woman presented to another ED complaining of intermittent headache for one week and vomiting for two days. On the day of admission, she was awakened from sleep by a severe headache. She was transferred to our hospital with the diagnosis of possible subarachnoid hemorrhage. The patient had a significant history of recurrent "migraine"-type headaches for which previous workup had been negative. These migrainous headaches had resulted in several ED visits over the previous year for parenteral narcotic analgesia. Medications included oral contraceptive pills, prazepam, and piroxicam. The patient denied any other neurologic symptoms.

Examination revealed a supple neck, normal fundi, and normal neurologic examination. Computed tomography (CT) did not reveal an intracranial bleed or other pathology. A lumbar puncture revealed an opening pressure of 44 cm cerebrospinal fluid, 726 RBCs, and two WBCs. Protein was 55 mg/dL (550 mg/L), and glucose was 56 mg/dL (3.0 mmol/L).

The patient was hospitalized, and workup included magnetic resonance imaging (MRI) of head and neck and cerebral angiography that revealed no pathology. Her headache improved over the course of a week. She was discharged with an improved headache and instructed to take acetazolamide and return for follow-up in one week. The discharge diagnosis was probable migraine headache, although a dural sinus thrombosis had been suspected.

One day after discharge, the patient presented by advanced life support personnel to the ED complaining of a five-minute generalized tonic-clonic

**FIGURE 1.** Diagram of cerebral dural sinuses. (Hollinshead WH, Rosse C: Textbook of Anatomy, ed 4. Philadelphia, JB Lippincott Co, 1985, p 925. Used with permission.)

seizure and subsequent dense right hemiplegia and slurred speech. She denied any trauma, febrile illness, or family history for seizures.

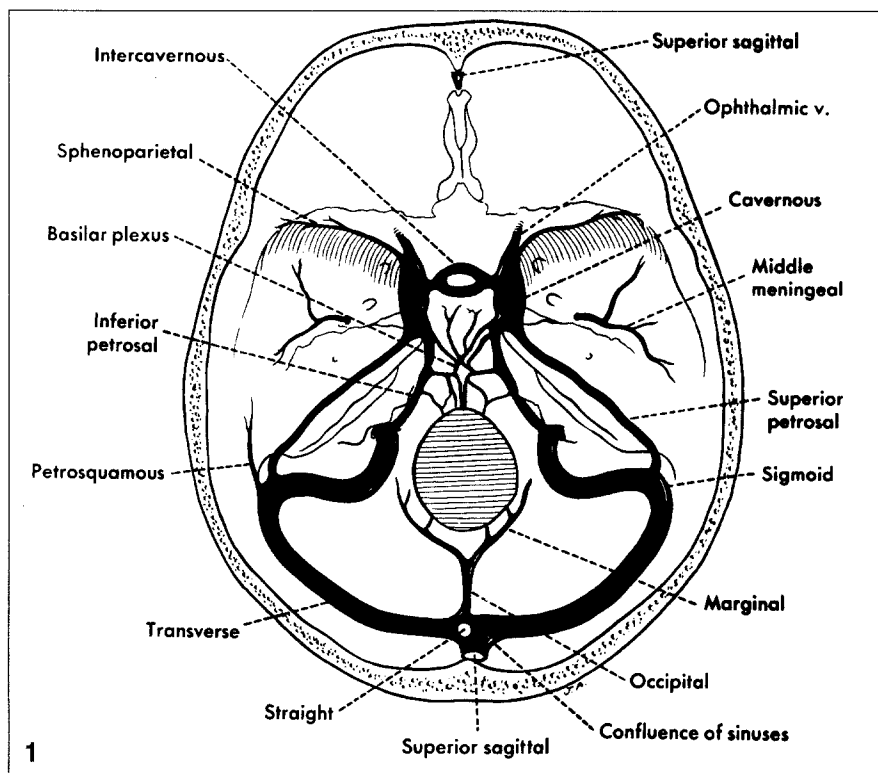
On examination, she was dysarthric, dense right hemiplegia with right ankle clonus was found, and there was no papilledema. Unenhanced CT scan in the ED was interpreted by a radiologist as normal. She was admitted, and IV loading with phenytoin was carried out.

The follow-up MRI revealed extensive thrombosis in the sagittal, straight, and jugular sinuses. These findings were confirmed by cerebral angiography. The patient was placed on heparin and mannitol and continued on phenytoin with subsequent resolution of her hemiplegia during the next two days. No further seizures were noted. On the third hospital day, she was changed from heparin to warfarin. The patient subsequently was found to have an asymptomatic left frontal intracranial hemorrhage on a routine follow-up MRI. She made a complete recovery and was instructed to avoid any future use of oral contraceptives. She was discharged home on phenytoin, warfarin, and acetaminophen/hydrocodone for headache.

## DISCUSSION

The diagnosis of CDST must be considered in patients complaining of unusual headaches, new-onset seizures, and focal neurologic deficits. Patients may present with headache alone or have vomiting, seizure, hemiparesis or hemiplegia, blurred vision, or other neurologic symptoms. These headaches are not location specific; however, they are typically severe. The seizures may be focal or generalized. Physical examination may reveal the above neurologic deficits; diplopia from a falsely localizing sixth nerve palsy, a homonymous hemianopsia, papilledema, occasional fever, and nuchal rigidity. Lumbar puncture may reveal increased opening pressure, increased protein, or increased RBCs.<sup>1</sup>

The anatomy of the cerebral sinuses is shown (Figure 1). Our patient had a superior sagittal sinus throm-



bosis that extended into the straight and jugular sinuses.

A thrombus in the cavernous sinus, most often seen after infection of the ethmoid, maxillary, or sphenoid sinuses or of the facial skin, can present with headaches; cranial nerve findings of III, IV, V-ophthalmic, and VI involvement; and papilledema. Also seen with cavernous sinus thrombosis are high fluctuating fevers, edema of the forehead and eyelids, and chemosis and proptosis. Hemiplegia, dysarthria, or seizure resulting from an uncomplicated cavernous sinus thrombosis are unlikely to be seen.

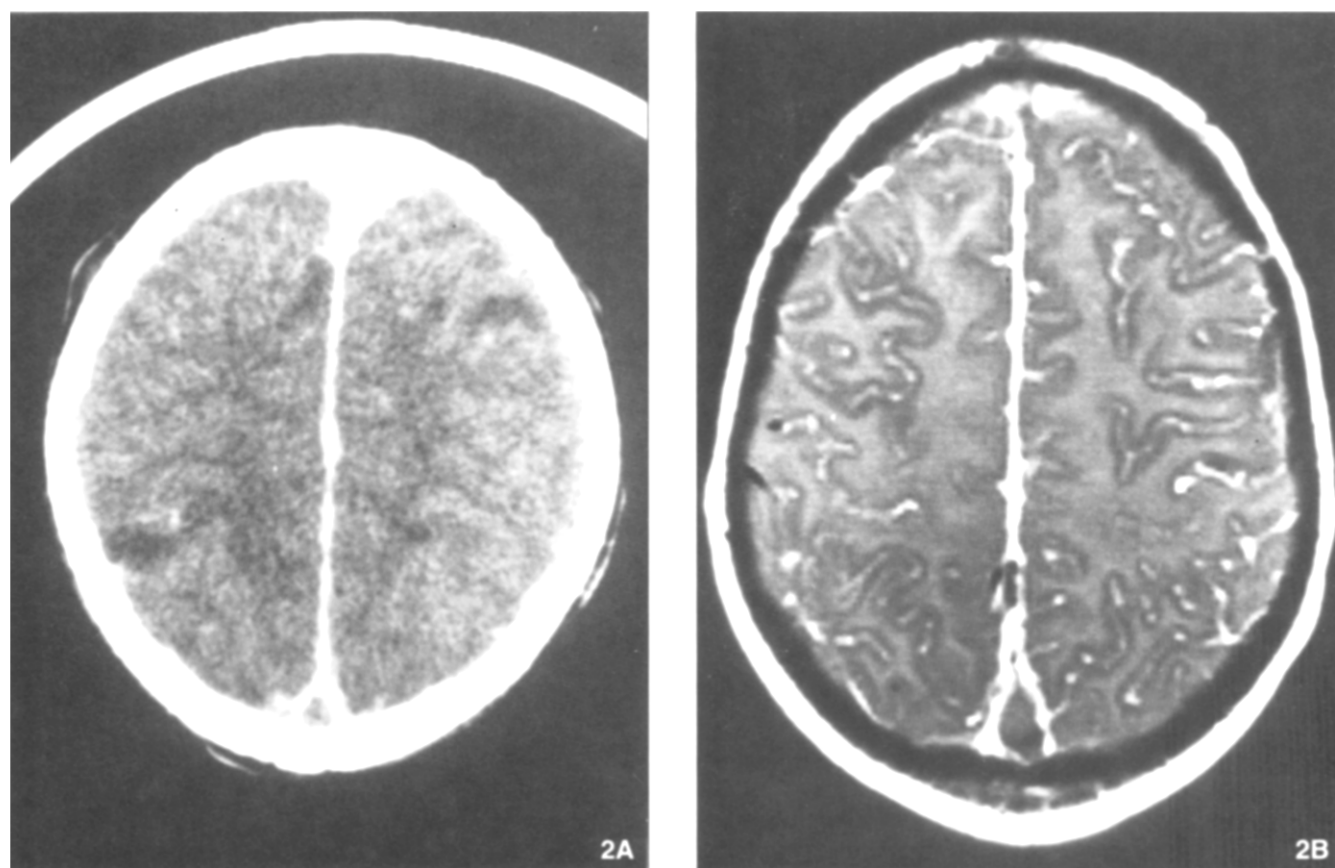
A review of 38 cases revealed that there are two important groups of patients with CDST. The first group typically has headache and papilledema. The second group has, in addition, vomiting, seizures, and focal neurologic deficits. The two groups are thought to represent thrombus in the sinus alone in the former and extension of thrombus into the cortical veins in the latter.<sup>1</sup> These two groups may be important prognostically but clinically represent different phases of the syndrome. Other symptoms that might be seen include numbness, paresthesias, visual disturbances, aphasia or dysarthria, leth-

argy, and coma. Those presenting with seizure and focal deficits may do worse than those with headache alone.<sup>1</sup>

This patient presumably had a headache from CDST during her first admission that escaped detection, despite appropriate diagnostic workup. After she had a seizure and neurologic deficit, the diagnosis was made using the same workup. This case demonstrates the natural history of a typical presentation for CDST.

There have been many proposed predisposing factors for this disease, most of which involve a state of hypercoagulability. These include cancer<sup>2</sup> and possibly chemotherapy,<sup>3</sup> the postpartum state,<sup>4,5</sup> oral contraceptive use,<sup>1,6-9</sup> regional enteritis,<sup>10</sup> and infection with dehydration.<sup>11</sup> Our patient had a history of "migraines" and was taking an oral contraceptive. It has long been thought that migraine headache is a relative contraindication to use of oral contraceptives; however, this has not been studied conclusively.<sup>12</sup> As many as 20% of reported cases of CDST have no etiology found after workup.

Diagnostic modalities have changed with the advent of MRI. CT with enhancement can detect 80% of CDST.<sup>1</sup> The most important finding



**FIGURE 2.** A. Contrast-enhanced CT scan. B. MRI scan displaying the "empty delta sign." This sign represents a clot within the superior sagittal sinus.

**TABLE.** Headache type

Signs	CDST	Cavernous Sinus Thrombosis	Migraine	Subarachnoid Hemorrhage
Fever	+	+++	0	+
Papilledema	+++	+++	0	++
Infection*	+	+++	0	0
<b>Symptoms</b>				
Vomiting	+++	0	++	++
Seizure	++	0	0	++
Hemiplegia	++	0	+	++
Dysarthria	++	0	+	++
Cranial nerves†	+	+++	0	+
Coma or altered mental status	++	0	0	+++

+++ , very common; ++ , somewhat common; + , seen only occasionally; 0 , unusual.

\*Infection elsewhere in body.

†Cranial nerve involvement, often III, IV, V, VI in cavernous sinus thrombosis, and occasionally falsely localizing VI in CDST.

on an enhanced CT is the "empty delta sign" seen in 28% to 35% of patients (Figure 2).<sup>13,14</sup> This sign represents a clot within the sinus and contrast material in the smaller veins within the wall of the sinus. False-positives may be seen if there is adjacent subdural hematoma, subdural empyema, subarachnoid hemorrhage, or dural sinus septation.<sup>14</sup> An un-

enhanced CT scan, as might be done in the workup of a possible subarachnoid bleed, may reveal small ventricles in about 33%<sup>13</sup> and the "cord" or "dense vein" sign in 6% to 20%.<sup>13,14</sup> The classic recommendation had been to follow any negative scans in suspicious individuals with cerebral angiography.<sup>13</sup>

CT scanning probably represents

the first line of diagnosis for use in the ED because it is generally available and can detect CDST as well as other pathology. MRI provides improved capabilities over the CT scan for the diagnosis of CDST as well as other potential causes for a patient's symptoms. Even though it is a new modality with only limited information in the literature, MRI appears to be the best modality available for the diagnosis of CDST.<sup>15,16</sup> Angiographic follow-up to negative MRI scans is recommended at this time.<sup>17</sup> The workup for our patient included all of these diagnostic modalities. Her initial presentation was considered to be clinically a result of CDST, but the diagnosis was not proven. The reason for this possibly missed diagnosis remains elusive even after retrospective review.

The differential diagnosis for a patient presenting with a severe head-

ache should include subarachnoid hemorrhage, herald bleed (thunder-clap headache), unsuspected subdural or epidural hemorrhage, cavernous sinus thrombosis, vascular cephalgia, pseudotumor cerebri, stroke, tumor, and meningitis. The unenhanced CT with follow-up lumbar puncture can help with the diagnosis, but a high index of clinical suspicion is needed to make the diagnosis in a patient with a CDST (Table).

Therapy is probably the most controversial aspect of any discussion of CDST. There have been reports of successful therapy using urokinase to lyse the thrombus, either locally or systemically.<sup>18,19</sup> Some advocate anticoagulation alone,<sup>20</sup> whereas others oppose anticoagulation and propose steroid or antiseizure medication.<sup>21</sup> The use of mannitol with or without anticoagulation also has been proposed,<sup>8</sup> as has barbiturate coma with ventricular drainage.<sup>22</sup> The use of surgical evacuation appears to be more of historical interest. This case was managed successfully with the use of combination therapy that included antiseizure and anticoagulant medication and an osmotic diuretic. The development of an asymptomatic intracranial hemorrhage was noted, but this did not affect the eventual outcome.

The prognosis for a patient with dural venous sinus thrombosis is fairly good. Recent literature has reported a mortality rate of 10% with several different therapeutic interventions. Morbidity in the form of blindness, resulting from optic atrophy, and focal motor deficits occur in 6% to 20% of patients. Factors found to correlate well with poor outcome are the initial presence of focal symptoms.<sup>1</sup> Our patient developed focal deficits but suffered no adverse sequelae.

From a single case, no conclusion about the best therapy can be made. The use of anticoagulation to prevent clot extension makes empiric sense, but it must be balanced against the risk of intracranial bleed in a patient with increased intracranial pressure and venous congestion. There is a theoretic argument against using an osmotic diuretic because dehydration is often implicated as a contributing factor in the development of CDST. In this case, mannitol was used to decrease the high intracranial pressure that had been detected by the lumbar puncture.

## SUMMARY

A case of CDST is presented. The patient had a typical presentation of the syndrome. Successful diagnosis using enhanced CT, MRI, and angiography was demonstrated. Management directed at the pathologic derangements using heparin, warfarin, phenytoin, and mannitol brought about resolution of the patient's symptoms. No therapeutic conclusions can be reached from this case. There are several reports of CDST in patients who take oral contraceptive medication, and it is believed that this contributed to the patient's development of the syndrome. This case is presented to illustrate a possible diagnosis for a patient with severe headache and, in particular, new neurologic deficits.

## REFERENCES

1. Boussier M, Chiras J, Bories J, et al: Cerebral venous thrombosis — A review of 38 cases. *Stroke* 1985;16:199-213.
2. Sigsbee B, Deck M, Posner J: Nonmetastatic superior sagittal sinus thrombosis complicating systemic cancer. *Neurology* 1979;29:139-146.
3. Hickey W, Garnick M, Henderson I, et al: Primary cerebral venous thrombosis in patients with cancer — A rarely diagnosed paraneoplastic syndrome. *Am J Med* 1982;73:740-749.
4. Estanol B, Rodriguez A, Conte G, et al: Intracranial venous thrombosis in young women. *Stroke* 1979;10:680-684.
5. Vali A, McKinstrey C, Dick D: Case of the month: A fit in a young woman. *Br J Radiol* 1988;61:335-336.
6. Atkinson E, Fairburn B, Heathfield K: Intracranial venous thrombosis as complication of oral contraception. *Lancet* 1970;1:914-918.
7. Haley E, Brashear H, Barth J, et al: Deep cerebral venous thrombosis: Clinical, neuroradiological, and neuropsychological correlates. *Arch Neurol* 1989;46:337-340.
8. Beal M, Wechsler L, Davis K: Cerebral vein thrombosis and multiple intracranial hemorrhages by computed tomography. *Arch Neurol* 1982;39:437-438.
9. Goldberg A, Rosenbaum A, Wang H, et al: Computed tomography of dural sinus thrombosis. *J Comput Assist Tomogr* 1986;10:16-20.
10. Sigsbee B, Rottenberg D: Sagittal sinus thrombosis as a complication of regional enteritis. *Ann Neurol* 1978;3:450-452.
11. Gum G, Numaguchi Y, Foster R, et al: Superior sagittal sinus thrombosis with intracerebral hematoma. *Comput Radiol* 1987;11:199-202.
12. Benson M, Rebar R: Relationship of migraine headache and stroke to oral contraceptive use. *J Reprod Med* 1986;12:1082-1088.
13. Rao K, Knipp H, Wagner E: Computed tomographic findings in cerebral sinus and venous thrombosis. *Radiology* 1981;140:391-398.
14. Virapongse C, Cazenave C, Quisling R, et al: The empty delta sign: Frequency and significance in 76 cases of dural sinus thrombosis. *Radiology* 1987;162:779-785.
15. Macchi P, Grossman R, Gomori J, et al: High field MR imaging of cerebral venous thrombosis. *J Comput Assist Tomogr* 1986;10:10-15.
16. McMurdo S, Brant-Zawadzki M, Bradley W, et al: Dural sinus thrombosis: Study using intermediate field strength MR imaging. *Radiology* 1986;161:83-86.
17. Bauer W, Einhaupl K, Heywang S, et al: MR of venous sinus thrombosis: A case report. *Am J Nucl Radiol* 1987;8:713-715.
18. Scott J, Pascuzzi R, Hall P, et al: Treatment of dural sinus thrombosis with local urokinase infusion. *J Neurosurg* 1988;68:284-287.
19. DiRocco C, Iannelli A, Leone G, et al: Heparin-urokinase treatment in aseptic dural sinus thrombosis. *Arch Neurol* 1981;38:431-435.
20. Castaigne P, Laplane D, Boussier M: Superior sagittal sinus thrombosis [letter]. *Arch Neurol* 1977;34:788-789.
21. Gettelfinger D, Kokmen E: Superior sagittal sinus thrombosis. *Arch Neurol* 1977;34:2-6.
22. Hanley D, Feldman E, Borel C, et al: Treatment of sagittal sinus thrombosis associated with cerebral hemorrhage and intracranial hypertension. *Stroke* 1988;19:903-909.