

Supported by the SMA Foundation, New York, NY (M.O., W.K.C., D.C.D.); Helene Pelletier Foundation (M.O.), Colleen Giblin Foundation (D.C.D.); NIH CTSA Award 1 UL1 RR024156-01 (P.K.).

Disclosure: M.O., W.K.C., P.K., and D.C.D. have received grants from the SMA Foundation and D.C.D. has received grants from the Colleen Giblin Foundation for other research activities not reported in this article. A.V. has received royalties for antibodies used in the study of neurological diseases. The remaining authors report no conflicts of interest.

Received April 2, 2008. Accepted in final form July 2, 2008.

Address correspondence and reprint requests to Dr. Darryl C. De Vivo, 710 168th Street, 2nd floor, New York, NY 10032; dcd1@columbia.edu

Copyright © 2008 by AAN Enterprises, Inc.

## ACKNOWLEDGMENT

The authors thank the parents of the children presented in this report for their helpful comments and their permission to show the facial features of their three children to increase awareness of this clinical phenotype.

1. Jacobson L, Polizzi A, Morriss-Kay G, Vincent A. Plasma from human mothers of fetuses with severe arthrogryposis

multiplex congenita causes deformities in mice. *J Clin Invest* 1999;103:1031–1038.

2. Rieder AA, Conley SF, Rowe L. Pediatric myasthenia gravis and velopharyngeal incompetence. *Int J Pediatr Otorhinolaryngol* 2004;68:747–752.
3. Morel E, Eymard Y, Vernet-der Garabedian B, Pannier C, Dulac O, Bach JF. Neonatal myasthenia gravis: a new clinical and immunologic appraisal on 30 cases. *Neurology* 1988;38:138–142.
4. Ahlsten G, Lefvert AK, Osterman PO, Stalberg E, Safwenberg J. Follow-up study of muscle function in children of mothers with myasthenia gravis during pregnancy. *J Child Neurol* 1992;7:264–269.
5. Jeannet PY, Marcoz JP, Kuntzer T, Roulet-Perez E. Isolated facial and bulbar paresis: a persistent manifestation of neonatal myasthenia gravis. *Neurology* 2008;70:237–238.
6. Brueton LA, Huson SM, Cox PM, et al. Asymptomatic maternal myasthenia as a cause of the Pena-Shokeir phenotype. *Am J Med Genet* 2000;92:1–6.
7. Carr SR, Gilchrist JM, Abuelo DN, Clark D. Treatment of antenatal myasthenia gravis. *Obstet Gynecol* 1991;78:485–489.

S. Felix  
S. Jeannin, MD  
C. Goizet, MD, PhD  
J.B. Thambo, MD  
S. Giraud, MD  
H. Plauchu, MD  
M. Montaudon, MD,  
PhD  
I. Sibon, MD, PhD

## STROKE FOLLOWING PULMONARY ARTERIOVENOUS FISTULA EMBOLIZATION IN A PATIENT WITH HHT

Hereditary hemorrhagic telangiectasia (HHT) is a rare autosomal dominant disorder involving the vascular system. Two clinically indistinguishable forms are described, HHT1 and HHT2, caused by mutations in the *ENG* and *ALK1* genes.<sup>1</sup> Diagnosis is based on the presence of at least three of the four following symptoms: spontaneous epistaxis, cutaneous telangiectases, arteriovenous malformations in internal organs, and positive familial history. The main complications are severe anemia, portal and pulmonary hypertension, hypoxemia, brain abscesses, and stroke.<sup>1,2</sup>

**Case report.** A 17-year-old boy, with HHT for only past medical history, was admitted in the emergency department for an acute isolated aphasia. Neurologic examination was normal apart from the aphasia, which spontaneously resolved in 10 hours. A general examination was normal. This neurologic event occurred 48 hours after endovascular treatment of a pulmonary arteriovenous malformation (PAVM) identified 6 months before, following the occurrence of an abnormal dyspnea. The consecutive pulmonary investigations (chest X-ray and CT scan with angiography) had led to the detection of three PAVMs. Because of severe hypoxemia, endovascular treatment of the most important PAVM had been planned (figure, A and B). Embolotherapy was performed using first three mechanical detachable coils to ensure no migration before coil detachment, and then using several pushable coils with microfibers. Pretherapeutic brain MRI and MR angiography had ruled out a cerebral arteriovenous malforma-

tion and a previous cerebral ischemic event. No neurologic symptoms were reported during the procedure and until the patient was discharged 24 hours after PAVM embolization.

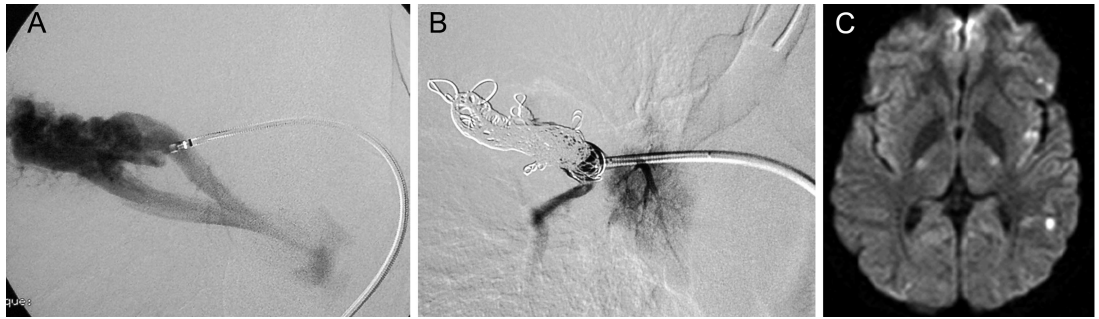
Brain diffusion MRI demonstrated several hyperintense cortical lesions (figure, C) in the territory of the left middle cerebral artery with low apparent diffusion coefficient values. MR angiography was normal. Standard biologic investigations were normal. Assessment of thrombophilia, including antithrombin III, C protein, S protein, factor VIII, and homocystinemia measurement, was negative. EKG and Holter EKG were normal. Transthoracic contrast echocardiography and transesophageal echocardiography (TEO) found a right-to-left shunt, and a patent foramen ovale (PFO) was evoked. PFO was ruled out during cardiac catheterization, and the right-to-left shunt was determined to be related to a persistent untreated PAVM.

Following this ischemic stroke an antiplatelet drug treatment (aspirin) was started; the initial dose of 250 mg PO daily was reduced to 75 mg because of epistaxis. This treatment was maintained for 6 months without side effects. No stroke recurrence was observed during this period. The patient is currently waiting for a new PAVM embolization.

The diagnosis of HHT was molecularly confirmed by identifying a heterozygous deletion of exon 2 to 10 of *ALK1* in this patient using quantitative multiplex PCR of short fragments.<sup>1</sup>

**Discussion.** Acute ischemic stroke, cerebral hemorrhages, bacterial meningitides, and cerebral abscess

**Figure** Pulmonary angiography showing a pulmonary arteriovenous malformation before (A) and after (B) embolization of endovascular material before stroke, and brain diffusion MRI demonstrating recent cerebral infarcts in the left middle cerebral artery territory (C)



are the main neurologic complications of HHT.<sup>2</sup> Among them, ischemic stroke and cerebral abscess are strongly related to the presence of PAVMs. During the last decade, PAVM embolization, a well-validated procedure, has demonstrated its ability to reduce the frequency of these complications. Nevertheless, this treatment can be associated with severe side effects such as infections, lung infarction, pleural pain and effusion, air embolism, cardiac arrhythmia, transient angina, and paradoxical embolization with cerebral infarction.<sup>3</sup>

In the present report, the short interval (48 hours) between PAVM embolization and stroke occurrence and the absence of any other stroke etiologic factor (large artery disease, PFO, thrombophilia) strongly suggest a potential link between these events.

The location of the lesions observed on MRI, the presence of a right-to-left shunt found on TEO, and the persistence of two PAVMs support the hypothesis of a paradoxical embolism through an unclosed PAVM or the treated PAVM itself in case of partial occlusion. In this context, clot, gas, or coil embolization can be evoked. Gas or coil embolisms are directly related to the procedure and therefore can be ruled out due to the delayed stroke occurrence.<sup>2,3</sup>

Several factors can contribute to increase the risk of paradoxical clot embolism following PAVM endovascular treatment in patients with HHT. First, patients with HHT have an increase of procoagulant factors such as factor VIII, D-dimer, and thrombin-antithrombin complex serum levels directly related to their disease.<sup>4,5</sup> Second, PAVM can induce a shunt-related hypoxemia that leads to polycythemia and hyperviscosity. Third, endovascular treatment itself is associated with an increased plasma level of prothrombotic factors.<sup>6</sup> The combination of these factors increases the risk of thrombus formation whereas

PAVM occlusion modifies the pressures in persistent PAVM, therefore increasing the risk of clot embolization.

In this context, antiplatelet drug use, such as low-dose aspirin, as primary stroke prevention during the days following endovascular PAVM embolization in patients with HHT should be evaluated. Defective platelet aggregation by adenosine diphosphate (ADP) and collagen adrenalin has been previously reported in HHT patients with severe bleeding.<sup>7</sup> Thus, checking platelet function with ADP- and collagen-induced platelet aggregation tests before using antiplatelet drugs seems to be mandatory in HHT.

*From the Departments of Clinical Neurosciences (S.F., S.J., C.G., I.S.), Cardiology (J.B.T.), and Radiology (M.M.), CHU Bordeaux; Université Victor Segalen Bordeaux 2 (C.G.), Laboratoire de Génétique Humaine; Service de Génétique Moléculaire et Médicale (S.G., H.P.), CHU Lyon; and Centre de Référence pour la Maladie de Rendu-Osler (H.P.), France.*

*Disclosure: The authors report no disclosures.*

*Received March 3, 2008. Accepted in final form July 2, 2008.*

*Address correspondence and reprint requests to Dr. Igor Sibon, Département de Neurologie, CHU Pellegrin, Université de Bordeaux II, Place Amélie Raba-Léon, 33076 Bordeaux Cedex, France; igor.sibon@chu-bordeaux.fr*

Copyright © 2008 by AAN Enterprises, Inc.

## ACKNOWLEDGMENT

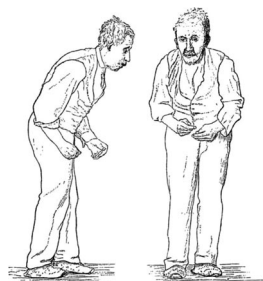The authors thank S. Dupuis for her critical lecture of the manuscript.

1. Lesca G, Burnichon N, Raux G, et al. Distribution of ENG and ACVRL1 (ALK1) mutations in French HHT patients. *Hum Mutat* 2006;27:598.
2. Cottin V, Chinet T, Lavolé A, et al. Pulmonary arteriovenous malformations in hereditary hemorrhagic telangiectasia: a series of 126 patients. *Medicine* 2007;86: 1–17.
3. White RI Jr., Lynch-Nyhan A, Terry P, et al. Pulmonary arteriovenous malformations: techniques and long-term outcome of embolotherapy. *Radiology* 1988;169:663–669.
4. Shovlin CL, Sulaiman NL, Govani FS, Jackson JE, Begbie ME. Elevated factor VIII in hereditary haemorrhagic telan-

- giectasia (HHT): association with venous thromboembolism. *Thromb Haemost* 2007;98:1031–1039.
5. Delgado-Reyes S, Garcia de la Rocha ML, Fernandez-Armayor Ajo V, Sierra I, Martin-Araguz A, Moreno-Martinez JM. Cerebral ischemia in Rendu Osler disease. *Neurologia* 2000;15:76–80.
  6. Hartnell GG, Jackson JE, Allison DJ. Coil embolization of pulmonary arteriovenous malformations. *Cardiovasc Intervent Radiol* 1990;13:347–350.
  7. Pandolfi M, Ehinger B. Conjunctival bleeding in Osler's disease with associated platelet dysfunction: a case report. *Acta Ophthalmol* 1978;56:75–82.

## From the AAN History Library Collection

### Gowers' *A Manual of Diseases of the Nervous System* (1888)



William Richard Gowers' (1845–1915) two-volume textbook, *A Manual of Diseases of the Nervous System* (1886, 1888), was often referred to as the “Bible of Neurology” and was one of the most influential and important neurology texts of the nineteenth century. The second volume, first published in 1888, consists of approximately 1,000 pages addressing the structure and function of the brain, cerebral localization, and various diseases of the cranial nerves, meninges, and brain. A considerable portion of the second volume was devoted to movement disorders, including a thorough and accurate description of the resting tremor and other clinical features of Parkinson disease, as well as detailed and insightful clinical descriptions of chorea, torticollis, tetanus, and writer's cramp. This sketch, from the second volume (1888) of Gowers' textbook,<sup>1</sup> shows the typical posture of “paralysis agitans” (Parkinson disease), a condition which had been described by his countryman, James Parkinson, some seventy years before in *An Essay on the Shaking Palsy* (1817).<sup>2</sup>

Douglas J. Lanska, MD, MS, MSPH, FAAN Chairman, AAN History Section

1. Gowers WR. *A Manual of Diseases of the Nervous System*. Vol. II: Diseases of the Brain and Cranial Nerves; General and Functional Diseases of the Nervous System. London: J.&A. Churchill, 1888, p. 591.
2. Parkinson J. *An Essay on the Shaking Palsy*. London: Sherwood, Neely, and Jones, 1817.

The American Academy of Neurology (AAN) Library Collection originated with a long-term donation of several thousand neurology-related books, many of them rare, by H. Richard Tyler, MD. The collection comprises more than 3,500 books, making it one of the world's most significant research resources for the history of neurology and neurosciences. All the materials in the AAN collection are organized, processed, and easily retrievable for research. AAN members may use the collection by contacting Lilla Vekerdy, Librarian, at [vekerdy@wustl.edu](mailto:vekerdy@wustl.edu) or (314) 362-4235.

If you have a passion for the history of neurology, consider applying for the H. Richard Tyler Award from the AAN which was established to encourage historical research using the AAN Library Collection at the Bernard Becker Medical Library at the Washington University School of Medicine in St. Louis. The award provides up to \$1,200 for research expenses and is open to AAN members and non-members. For more information about the award, visit [www.aan.com/libv](http://www.aan.com/libv) or contact Jeff Sorenson at [jsorenson@aan.com](mailto:jsorenson@aan.com) or (651) 695-2728.

# Neurology®

## STROKE FOLLOWING PULMONARY ARTERIOVENOUS FISTULA EMBOLIZATION IN A PATIENT WITH HHT

S. Felix, S. Jeannin, C. Goizet, et al.

*Neurology* 2008;71;2012-2014

DOI 10.1212/01.wnl.0000336973.27761.45

**This information is current as of December 8, 2008**

<b>Updated Information &amp; Services</b>	including high resolution figures, can be found at: <a href="http://www.neurology.org/content/71/24/2012.full.html">http://www.neurology.org/content/71/24/2012.full.html</a>
<b>References</b>	This article cites 7 articles, 0 of which you can access for free at: <a href="http://www.neurology.org/content/71/24/2012.full.html##ref-list-1">http://www.neurology.org/content/71/24/2012.full.html##ref-list-1</a>
<b>Citations</b>	This article has been cited by 1 HighWire-hosted articles: <a href="http://www.neurology.org/content/71/24/2012.full.html##otherarticles">http://www.neurology.org/content/71/24/2012.full.html##otherarticles</a>
<b>Subspecialty Collections</b>	This article, along with others on similar topics, appears in the following collection(s): <b>All Epilepsy/Seizures</b> <a href="http://www.neurology.org/cgi/collection/all_epilepsy_seizures">http://www.neurology.org/cgi/collection/all_epilepsy_seizures</a> <b>All Psychiatric disorders</b> <a href="http://www.neurology.org/cgi/collection/all_psychiatric_disorders">http://www.neurology.org/cgi/collection/all_psychiatric_disorders</a>
<b>Permissions &amp; Licensing</b>	Information about reproducing this article in parts (figures, tables) or in its entirety can be found online at: <a href="http://www.neurology.org/misc/about.xhtml#permissions">http://www.neurology.org/misc/about.xhtml#permissions</a>
<b>Reprints</b>	Information about ordering reprints can be found online: <a href="http://www.neurology.org/misc/addir.xhtml#reprintsus">http://www.neurology.org/misc/addir.xhtml#reprintsus</a>

*Neurology*® is the official journal of the American Academy of Neurology. Published continuously since 1951, it is now a weekly with 48 issues per year. Copyright . All rights reserved. Print ISSN: 0028-3878. Online ISSN: 1526-632X.

