
CAN SUBDURAL HEMATOMA BE A TRIGGER FOR GUILLAIN–BARRÉ SYNDROME?

NİLGÜL YARDİMCİ

Department of Neurology
Baskent University Faculty of Medicine
Ankara, Turkey

SALİH GULSEN

Department of Neurosurgery
Baskent University Faculty of Medicine
Ankara, Turkey

AYNUR YILMAZ AVCI

Baskent University Hospital
Baskent University Faculty of Medicine
Antalya, Turkey

NUR ALTINORS

Department of Neurosurgery
Baskent University Faculty of Medicine
Ankara, Turkey

TURGUT ZİLELİ

Department of Neurology
Baskent University Faculty of Medicine
Ankara, Turkey

Received 2 April 2008.

Address correspondence to Nilgül Yardimci, Baskent University Faculty of Medicine, Department of Neurology, Fevzi Cakmak Cad 10. Sok No: 45, 06490, Bahcelievler, Ankara, Turkey. E-mail: ntuncel@yahoo.com

366

UFUK CAN

Department of Neurology
Baskent University Faculty of Medicine
Ankara, Turkey

Guillain-Barré syndrome (GBS) is an acute inflammatory polyneuropathy which follows a precipitating event in approximately two thirds of cases. Although its pathogenesis is unclear, it is likely to be a consequence of an immune-mediated process. In the literature there are three case reports of GBS following subarachnoid hemorrhage, subdural hematoma, and facial bone fracture after head trauma. The unique feature of our case with GBS after subdural hematoma is the presence of cerebellar symptoms. We believe that GBS results from an aberrant immune response following trauma that somehow mistakenly attacks the nerve tissue of its host, and we discuss the effects of the trauma of head injury on cellular and humoral immunities and the absence of antiganglioside antibody (anti-GD1b IgG, which is accused of ataxia and cerebellar symptoms) in this case report.

Keywords anti-GD1b IgG antibody, Guillain-Barré syndrome, head trauma, immunity, stress, subdural hematoma

INTRODUCTION

Guillain-Barré syndrome (GBS) which was first described by Guillain, Barré, and Strohl in 1916 is an acute inflammatory demyelinating polyneuropathy. The annual incidence of GBS is fairly uniform at between one and four cases per 100,000 people throughout the world. GBS follows a precipitating event in approximately two thirds of cases (Asbury & Cornblath, 1990). Numerous case reports and descriptions of large series implicate a plethora of different infections and other events such as immunization, various types of trauma, general surgical procedures, orthopedic operations, and spinal anaesthesia as possible antecedents of GBS.

It is believed that GBS results from an aberrant immune response that somehow mistakenly attacks the nerve tissue of its host, most probably by recognizing a molecularly similar epitope mechanism (molecular mimicry). Immune reactions against these epitopes result in acute inflammatory demyelinating neuropathy or acute axonal forms.

In the literature there are only 3 cases of GBS following head injury (Duncan & Kennedy, 1987; Gabriel, Marcos, & Myriam, 1997; Lin, Lee, Lin, Yai, & Lin, 2006). In this unique case report we describe an unusual form of GBS presenting with prominent cerebellar symptoms after subdural hematoma.

CASE

The patient was an otherwise-healthy 75-year-old woman. She had suffered from a head trauma due to a traffic accident 10 days ago. Her neurologic examination was normal, but because of the bilateral frontal subdural hematoma of 10-mm width observed in the cranial tomography she had been under observation. Ten days after the accident she had to be admitted to the hospital because she developed paraparesis a week after the accident which progressed to flask quadriparesis in 3 days' time. In the control cranial magnetic resonance imaging (MRI; Figure 1) she had only right frontal subdural hematoma of 5-mm width which was better than what was seen in her first computerized tomography (CT) scan. Her past medical history was normal, and she did not report any recent infectious illness. On her neurologic examination she was fully alert and oriented. The result of her cranial nerve examination was normal, including no ophthalmoparesis. The muscle strength was 4/5 in the upper extremities and 3/5 in the lower extremities. All tendon reflexes were absent, and the plantar responses were flexor. There was no impairment of pinprick, touch, position sense, or vibratory sensations. Investigations revealed normal hematological and biochemical data. Cerebrospinal fluid was acellular with a high protein level. Antibody titers for various viruses were normal. *Campylobacter jejuni* was not detected in the faeces. Electrodiagnostic studies revealed a severe generalized, predominantly motor-demyelinating peripheral neuropathy. On the next day of the admission to hospital she developed choreic movements dominant in the right arm and prominent cerebellar ataxic speech. Subsequently bilateral abnormal finger–nose and heel–knee tests showed the appearance of intentional tremor on both sides, dysmetria, and dysidiadochokinesia. She was unable to sit unsupported because of truncal ataxia. There was no loss of proprioceptive sense. As her brain MRI was normal only for slight right frontal subdural hematoma we ruled out other diseases with cerebellar symptoms such as cerebellar vascular disease, hematoma, and encephalitis in the brain stem or cerebellum. Serological screening results for neurotropic viruses, *Borrelia burgdorferi*, *Treponema pallidum*, and HIV-1, were negative. Moreover anti-GD1b antibody accused of the ataxia in Guillain–Barré syndrome was negative. She was treated with plasmapheresis. After the second plasmapheresis her choreic movements and cerebellar dysfunction diminished. In the following days her motor weakness gradually improved. Plasmapheresis was performed seven times. One month later when she was discharged from the hospital she had mild paraparesis (muscle strength 4/5) and rare choreic movements in her right arm. In her neurologic examination 3 months later she was totally normal.

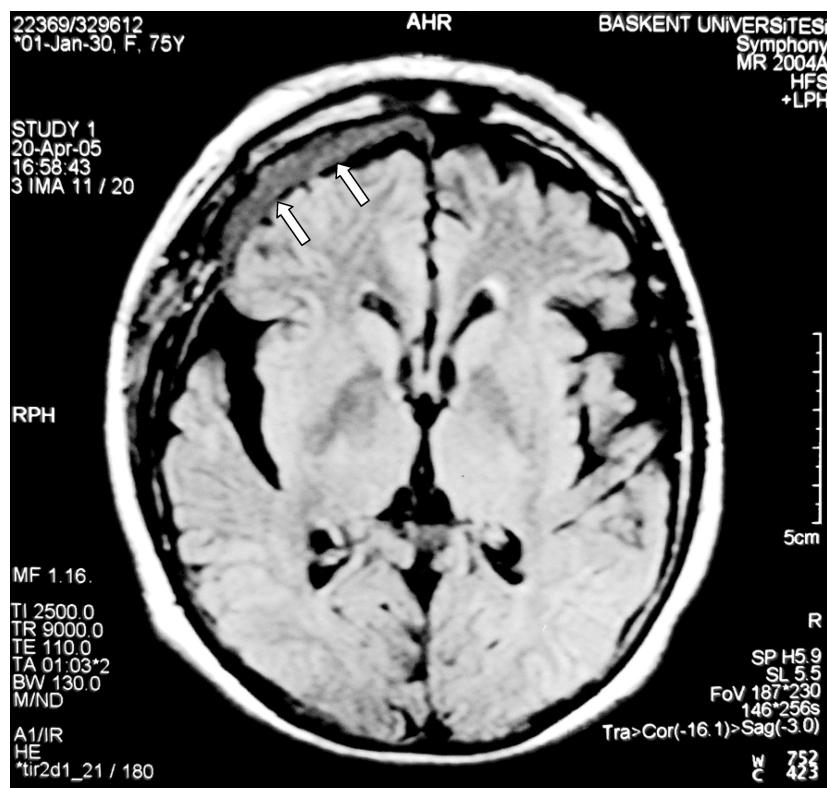


Figure 1. Axial slice of T₁-weighed MRI scan showing chronic subdural hematoma in the right frontal lobe.

DISCUSSION

GBS is the most frequent cause of acute neuromuscular paralysis. Although the most affected patients have the typical presentation of an acute demyelinating neuropathy, several patients have regionally or functionally restricted clinical presentation or evidence of an axonal neuropathy, broadening the boundaries of this syndrome. Besides GBS may also have atypical presentations.

Both cellular and humoral immune responses may be involved in the pathogenesis of GBS, mounted against an antigen that still needs to be defined. Also autoimmune-mediated mechanism, possibly triggered by an infectious agent sharing epitope/s with neural antigens (molecular mimicry), has been proposed.

In the present case, the patient's condition was different from the ataxic form of GBS because she had shown not only ataxia but also obvious cerebellar symptoms unrelated to muscle weakness, without ophthalmoplegia or proprioceptive sensory disturbance. In a number of GBS cases, antiganglioside antibody (anti-GD1b IgG) has been accused of ataxia and cerebellar symptoms. Anti-GD1b IgG antibody is thought to bind to myelin around the Ranvier node and primary sensory neuron (Kusunoki, Chiba, Tai, & Kanazawa, 1999). Moreover, it has been reported that GD1b exists in the cerebellar granular layer, dentate nucleus, and olivary nucleus in the cerebellum (Hitoshi et al., 1994). A recent report by Sugimoto et al. (2002) suggested that the anti-GD1b antibody was associated with prominent cerebellar ataxia through binding to the cerebellar granular layer or 1a fiber of the spinal spinocerebellar tract. Binding of anti-GD1b antibody to some myelin, mainly in the paranodal region, can be associated with the pathogenetic mechanisms of conduction block or demyelination observed in GBS. Moreover (Wicklein, Pfeiffer, Yuki, Hartard, and Kunze (1997) reported that GBS with ataxia results from disturbance of deep sensations. However, in our case, the ataxia was believed to be cerebellar-type because deep sensations were normal. Using only the present results, we cannot explain the diversity in clinical features among patients with serum anti-GD1b antibody. Some additional factors should be involved in the development of damage in the cerebellar mechanisms, even if anti-GD1b antibody is one of the causative factors (Sugimoto et al.). It is necessary to accumulate additional case reports and studies to clarify the association between GBS and cerebellar symptoms and anti-GD1b IgG. Strikingly, in our patient anti-GD1b antibody titers were normal (i.e., less than 100).

General trauma is among the triggers of GBS, but there are only three case reports regarding the event of GBS following head trauma (Duncan & Kennedy, 1987; Gabriel et al., 1997; Lin et al., 2006). Duncan & Kennedy reported a male patient who had brain contusion and subdural hematoma and then presented with clinical and electroneuromyographic findings which were compatible with GBS. Gabriel et al. described a similar case of a victim of head injury with subarachnoid hemorrhage. Lin et al. reported an unusual case of GBS which occurred 10 days after facial bone fracture (left zygomatic arch, medial and lateral walls of the left orbit, anterior and posterior wall of left maxillary sinus) without any brain oedema in CT scan. Our patient is an unusual presentation of GBS after subdural hematoma with prominent cerebellar symptoms for the first time in the literature.

In our case head trauma might have been the trigger for GBS that evoked an immune-mediated disorder producing inflammation and demyelination of

the peripheral nerves. The trauma of head injury may alter the cellular and humoral immunities (Quattrocchi, Frank, et al., 1992; Quattrocchi, Miller, et al., 1991). It has been shown that severe head injury in the absence of significant systemic injury results in anergy to delayed-type hypersensitive skin testing; in addition suppression of helper T cell activation suggests that severe head injury results in a helper T cell function defect. This defect does not appear to resolve within 3 weeks of injury, as opposed to the defect in helper T cell activation (expression of interleukin-2 receptors), which normalizes within 3 weeks of injury (Quattrocchi, Issel, Miller, Frank, & Wagner, 1991). In our patient GBS symptoms appeared a week after the subdural hematoma occurrence, which is consistent with the mentioned time.

Another possible mechanism is the stress caused by trauma, activating some latent or subclinical process (Herbert & Cohen, 1993; Segerstrom & Miller, 2004). It has been shown that stress may elicit prolonged secretion of cortisol, against which white blood cells mount a counterregulatory response by downregulating their cortisol receptors. This downregulation in turn reduces the cells' capacity to respond to anti-inflammatory signals and allows cytokine-mediated inflammatory processes to flourish. The more a stressor deviates from those parameters by becoming more chronic, the more components of the immune system are affected in a potentially detrimental way (Segerstrom & Miller).

CONCLUSION

The unique feature of this GBS after subdural hematoma is the presence of cerebellar symptoms. This case is an atypical presentation of the syndrome. To what extent variants and atypical presentations of GBS are a reflection of fundamentally different pathomechanisms or whether the heterogeneity of the immunological targets on nerve fibers might cause these variations so far remains to be explored.

REFERENCES

- Asbury, A. K., & Cornblath, D. R. (1990). Assessment of current diagnostic for Guillain-Barré syndrome. *Annals of Neurology*, 27(Suppl), S21-S24.
- Duncan, R., & Kennedy, P. G. E. (1987). Guillain-Barré syndrome following acute head trauma. *Postgraduate Medicine*, 63, 479-480.
- Gabriel, R., Marcos, R. G., & Myriam, C. (1997). Guillain-Barré syndrome and head trauma. *Arquivos de neuro-psiquiatria*, 55, 315-318.

- Guillain, G., Barré, J. A., & Strohl, A. (1916). Sur un syndrome de radiculoneurite avec hyperalbuminose du liquide cephalorichidien sans reaction cellulaire. Remarques sur les caracteres clinizques et graphiques des reflexes tendineux. *Bulletins et Memoires de la Societe Medicale des Hopitaux de Paris*, 40, 162–70.
- Herbert, T. B., & Cohen, S. (1993). Stress and immunity in humans: A meta-analytic review. *Psychosomatic Medicine*, 55, 364–379.
- Hitoshi, S., Kusunoki, S., Chiba, A., Takatsu, R., Sunada, Y., Nukina, N., et al. (1994). Cerebellar ataxia and polyneuropathy in a patient with IgM M-protein specific to the GalNAc epitope. *Journal of the Neurological Sciences*, 126, 219–224.
- Kusunoki, S., Chiba, A., Tai, T., & Kanazawa, I. (1999). Localization of GM1 and GD1b antigens in the human peripheral nerve system. *Muscle & Nerve*, 16, 752–756.
- Lin, T. M., Lee, S. S., Lin, R. T., Yai, C. S., & Lin, S. D. (2006). Guillain–Barré syndrome following facial bone fracture. *Journal of Plastic, Reconstructive & Aesthetic Surgery*, 59, 543–546.
- Quattrocchi, K. B., Frank, E. H., Miller, C. H., Dull, S. T., Howard, R. R., & Wagner, F. C., Jr. (1991). Severe head injury: Effect upon cellular immune function. *Neurological Research*, 13, 13–20.
- Quattrocchi, K. B., Issel, B. W., Miller, C. H., Frank, E. H., & Wagner, F. C. Jr. (1991). Impairment of helper T-cell function and lymphokine-activated killer cytotoxicity following severe head injury. *Journal of Neurosurgery*, 75, 766–773.
- Quattrocchi, K. B., Miller, C. H., Wagner, F. C. Jr., DeNardo, S. J., DeNardo, G. L., Ovodov, K., et al. (1992). Cell-mediated immunity in severely head-injury patients: The role of suppressor lymphocytes and serum factors. *Journal of Neurosurgery*, 77, 694–699.
- Segerstrom, S. C., & Miller, G. E. (2004). Psychological stress and the human immune system: A meta-analytic study of 30 years of inquiry. *Psychological Bulletin*, 130, 601–630.
- Sugimoto, H., Wakata, N., Kishi, M., Fujioka, T., Kurihara, T., Irve, Y., et al. (2002). A case of Guillain–Barré syndrome associated with cerebellar ataxia and positive serum anti-GD1b IgG antibody. *Journal of Neurology*, 249, 346–347.
- Wicklein, E. M., Pfeiffer, G., Yuki, N., Hartard, C., & Kunze, K. (1997). Prominent sensory ataxia in Guillain–Barré syndrome associated with IgG anti-GD1b antibody. *Journal of the Neurological Sciences*, 151, 227–229.