

THE primate visual cortex is a mosaic of different areas which are roughly organized into two major pathways, a dorsal one along an occipito-parietal channel and a ventral one along an occipito-temporal channel. It is known that visual stimuli are processed differently within these two systems and one might expect therefore that behavioral deficits would differ according to the channel damaged by cerebral lesions. Two patients with left prestriate lesions presented perceptual deficits in the right visual field. These deficits involved reading, recognition of line drawings and colour perception and would be compatible with a dysfunction of the ventral system. Magnetic resonance imaging analysis confirmed that this was the case.

**Key words:** Human visual cortex, Ventral and dorsal system, Prestriate lesions, Form and colour perception deficits, Neuropsychology

## Unmasking of visual deficits following unilateral prestriate lesions in man

François Michel,<sup>CA</sup> Marie-Anne Henaff and Rémy Bruckert

U.280 INSERM, 151 Cours A. Thomas, 69003, Lyon, France

<sup>CA</sup> Corresponding Author

### Introduction

In monkeys physiological and anatomical studies have uncovered a mosaic of as many as 20 separate areas. On a larger scale the system can be thought of as composed of two parallel channels of information processing,<sup>1–3</sup> the magno-cellular channel (the 'motion', 'achromatic' or 'low-contrast' channel) and the parvo-cellular channel (the 'form', 'colour' channel). The first channel projects to the parietal lobe and connects areas in a dorsal system which processes spatial properties, i.e. 'where' representations. The second channel projects to the temporal lobe and connects areas in a ventral system which processes object properties, i.e. 'what' representations. A crucial station of the first channel is V5 while a crucial station for the second channel is V4. Yet some authors contest too strict a dichotomy between these two major information-processing streams.<sup>4–6</sup>

The human visual system probably has a functional organization similar to that of monkeys. However, relevant anatomical data are lacking. The frontier between area V1 and V2 is easily identified by the stripe of Gennari.<sup>7</sup> Other borders of V2 are delineated by cyto- and myelo-architectonic criteria and possibly by a molecular marker.<sup>8</sup> The boundaries of other areas can be inferred from cyto- and myelo-architectonic criteria combined with loci of callosal connections.<sup>9</sup> The position of V4 remains approximate. Area V5 has been tentatively localized on a flat map as an heavily myelinated area in the parieto-occipital sulcus.<sup>10</sup>

PET studies confirm that the human visual cortex is parcellated. Indeed blood flow changes show activation of different discrete areas according to the visual display attributes (shape, colour, movement,

depth) attended to.<sup>11,12</sup> Lueck *et al.*<sup>13</sup> have localized a colour centre, homologous to V4, near the lingual and fusiform gyri. V5 and MST seem to be located on the dorso-lateral surface of the occipital lobe and the inferior parietal lobule. Even specific loci activated by passive word reading or visual memory tasks have been localized in the prestriate cortex.<sup>14,15</sup>

One may expect that lesions would induce different visual deficits according to the channel or the areas damaged. Several cases of behavioral deficits restricted to perception of colour (see Zeki's comprehensive review<sup>16</sup>) or movement<sup>17</sup> have been reported. In these cases lesions were mostly bilateral, in roughly mirror locations, outside the striate areas. However, such patients are so rare that it seems necessary to resort to the more numerous patients with unilateral lesions.<sup>18,19</sup> In such cases tachistoscopic visual tests can be used in an effort to unmask deficits in one hemifield.

### Materials and Methods

We studied two patients with lesions damaging ventral prestriate areas while sparing the striate areas themselves.

Tachistoscopic hemifield presentation of stimuli was monitored by a specific computer program.<sup>20</sup> Patients sat 50–60 cm in front of a white CRT screen driven by a Mac II computer. They were presented with written material subtending from 2 to 4 degrees of visual angle or with line drawings of objects subtending 2 to 8 degrees. Before each presentation patients were required to fixate a point appearing for 1 s at the geometrical centre of the screen.

## Results

**Case 1.** Patient SK is a 55-year-old right-handed male. He first had a cerebral infarct which damaged the middle part of T4 and T5 in the right hemisphere. A left upper quadrantanopia was then the only noticeable deficit.

A year later SK had a second cerebral infarct in

letter was recognized. In the LVF + RVF pairs of letters ( $n=160$ ) were presented during various time exposures between 100 and 250 ms, one letter in each field, at  $1^\circ$  from the fovea. Right-hand side letters were correctly read in only 30% of the pairs while left-hand side letters were always correctly recognized. Thus SK showed a clear extinction in the right-hand side hemifield when tested using a right/

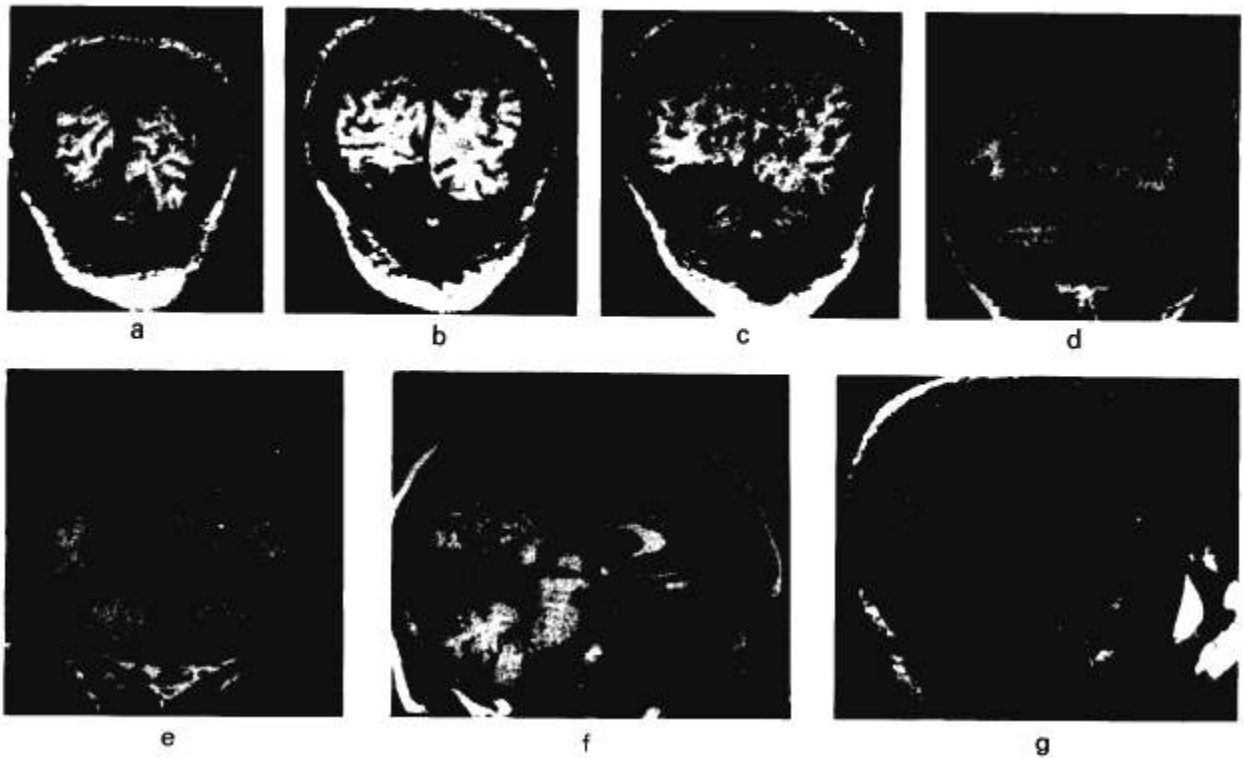


FIG. 1. Magnetic resonance imaging of case 1. (a-e) Coronal cuts; (f) midline sagittal cut; (g) lateral sagittal cut. The lesion destroys the lateral part of the lingual gyrus, the fusiform gyrus and the third occipital gyrus, but spares the occipital pole and most of the calcarine area.

the left posterior temporo-occipital region (Fig. 1), after which he presented a prosopagnosia and an alexia. The alexia receded and SK showed no cognitive disorder apart from a prosopagnosia.

On campimetric examination there was an incomplete left upper quadrantanopia and a normal RVF. Tested with two sorts of grating patterns (IIIIII vs III/III) SK distinguished the string with the italic *I* in both visual fields, but insisted that the pattern was fuzzier in the RVF.

SK's reading in natural conditions was slow but not strikingly abnormal. However, when tested with hemifield tachistoscopic exposure, SK showed an obvious perceptual deficit in the RVF.

**Letters and words.** In the LVF nearly 100% of letters ( $n=120$ ) and 3-, 4- and 5-letter words ( $n=60$ ) were read easily with 100 or 250 ms time exposures. In the RVF 92% of letters ( $n=130$ ) were read at  $1^\circ$  right to the fovea at various exposures, ranging from 50 to 250 ms. Almost no letters could be read beyond  $2^\circ$ . No word could be read for exposures between 100 and 300 ms, but most often the first

left competition paradigm.

**Line drawings.** We presented object line drawings, to the right or the left of the fovea, with a 250 ms exposure time. SK correctly named all items in the LVF and 17 out of 18 drawings in the RVF. This excluded the hypothesis of a RVF scotoma.

With a bilateral presentation he recognized 24 out of 25 items in the left hemifield, but only four out of 25 in the right hemifield. Once again competition induced an extinction phenomenon in the RVF. Colour perception has not been tested.

**Case 2.** VM is a 25-year-old right-handed female who had a surgical removal of an arterio-venous angioma in the left occipital lobe. CT scans and MRI showed the lesion located in the inferior aspect of the left temporo-occipital junction (Fig. 2). Before surgery she could read equally well in both visual fields under bilateral tachistoscopic presentations. Immediately after surgery she showed a word-finding difficulty and a severe alexia without agraphia. Goldman's kinetic perimetry was normal while static automatal perimetry proved a dense RVF hemianopia.

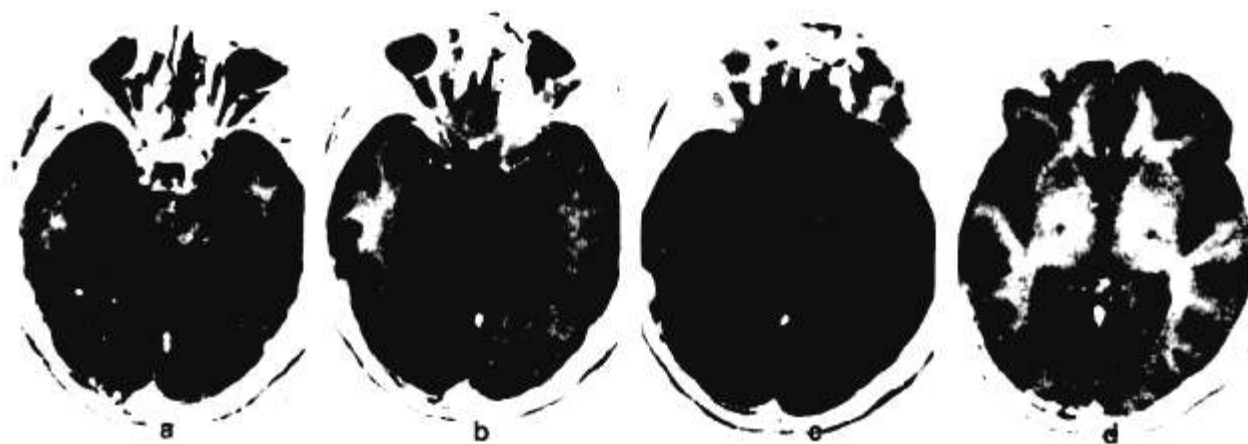


FIG. 2. Magnetic resonance imaging of case 2. (a–d) Horizontal cuts. The lesion destroys the fusiform gyrus and the third occipital gyrus but spares the lingual gyrus and the calcarine area.

Two months later VM had a normal neuropsychological status and only complained of a slowness in reading. The statokinetic dissociation had disappeared and visual fields were normal. However, tachistoscopic exposures revealed perceptual deficits in the RVF. These deficits had partly resumed in the year following surgery but remained severe. We report essentially her latest, in fact her best, performances.

**Contrast sensitivity.** Three different shapes (square, triangle and circle) were filled with gratings and appeared grey on the white screen, subtending a  $3^\circ$  visual angle. They were presented for 50 ms centred at various positions between 0 and 4 degrees from the fovea in the four quadrants. All were easily recognized although VM noticed that shapes looked different in the RVF. To lower the contrast the same grey shapes were displayed on a grey background square of a different texture, inducing a faint brightness contrast. At 20 and 50 ms exposure times, recognition remained perfect in the LVF but was poor in the right inferior quadrant and null in the right superior quadrant.

**Words.** VM was presented with a series of 40 8-letter words, astride the fovea, for 200 ms. She read only 70% of the words, essentially because she could not read the right-sided letters.

She was presented with 40 5-letter words in each hemifield, at  $1^\circ$  lateral from the fixation point. At 100 ms VM read 75% of the words and 90% of the letters in the LVF, 3% of the words and 30% of the letters in the RVF. In the RVF the percentage of recognized letters decreased along the successive five positions within the word (respectively, 72, 45, 17, 12 and 15%).

VM was presented with 20 pairs of 4-, 5- and 6-letter words, one word in each hemifield, during 200 ms. In the LVF she read 95% of the words. In the RVF she read 70% of the 4-letter words, 10% of the 5-letter words, and 0% of the 6-letter words. With the same series presented for 100 ms she read 100% of the words in the LVF but 0% in the RVF.

She was also presented for 333 ms with three randomly mixed series of 25 pairs of words, one series on the horizontal meridian, one series  $2^\circ$  under and one series  $2^\circ$  above. In the LVF she read 95% of the words in the upper quadrant, 88% on the horizontal meridian and 85% in the inferior quadrant. In the RVF she read, respectively, 18, 23 and 45% of the words, i.e. a lower performance in the right superior quadrant.

**Line drawings.** In three different sessions VM was presented with 75 pairs of line drawings for 200 ms. She recognized 98% of pictures in the LVF and 62% in the RVF.

**Colours.** In three different sessions, 60 pairs of isoluminant coloured disks (blue, red, green or yellow) were presented on a black screen, one disk in each hemifield, for 100, 200 and 500 ms. With 100 and 200 ms exposures VM correctly named 95% of colours in the LVF, 42% in the RVF. At 500 ms all pairs of coloured disks were correctly named.

To eliminate a possible deficit of naming of RVF stimuli, a same-different judgment task was used. Twenty-seven pairs of isoluminant coloured disks (12 pairs of the same colour and 15 of different colours) were presented for 200 ms. In the first session VM judged all pairs as different. The same series of 27 pairs was presented for 200 ms for a three level evaluation: same, slightly different, very different. Responses were at chance level. These results reflect a strong difference in colour perception in the two hemifields that VM only became aware of during these tachistoscopic testings. She stated that disks appeared greyish on the right side.

A coloured video image was digitalized with two different levels of saturation in order to obtain one highly and one slightly coloured picture. A series of 48 pairs of the two pictures, 12 of each kind (highly-highly, highly-slightly, slightly-highly, and slightly-slightly coloured) was randomly presented for 200 ms, one picture in each hemifield, subtending a  $4^\circ$  visual angle close to the fovea. The patient

was told to judge each picture of the pair as 'bright' or 'pale'. All pictures presented in the left hemifield were correctly judged, while all but four pictures presented in the right hemifield were judged 'pale', i.e. 20 out of 24 'bright' were reported 'pale'.

## Discussion

The first patient complained only of a slowness in reading. The second patient considered that she had completely recovered except that reading was not as fast as prior to surgery.

Despite apparently normal visual fields both patients showed perceptual deficits in their RVF when tachistoscopic presentations were used. They had no behavioral difficulties which could be attributed to a dysfunction of the dorsal system (perception of movement, pointing or reaching, use of peripersonal space, spatial attention, visual search, etc.). On the other hand, they showed severe deficits which could be attributed to a dysfunction of the ventral system (reading, colour and form perception).

Radiology confirmed these clinical hypotheses. In both cases MRI showed that the lesions involved only prestriate areas. We cannot precisely identify which particular visual areas were damaged but we can state that in both patients the ventral system, but not the dorsal system, was damaged.

In Case 1 the capacity of visual recognition in the RVF was reduced. The lesion apparently involved the ventral system extensively. The second patient was less impaired and presented essentially difficulties in reading and perceiving colours in the RVF. Area V5 was probably spared and this may explain the early campimetric stato-kinetic dissociation. The lesion probably involved V4 and V3 and temporal areas in the close vicinity. This patient had her worst performances in the superior quadrant, which suggests a lesion of areas topographically organized in quadrants since a possible lesion of the inferior part of the optic radiation is not consistent with the normal campimetric examination.

In both patients the reading deficit was prominent. Acuity and contrast sensitivity were sufficient to

allow recognition of line drawings. Why were letters and words not recognized? Some procedures specific to reading (parallel processing, spatial attention, word form building, etc) were probably hampered.

In all the tests bilateral mirror presentations of stimuli were very disabling. This may suggest that during unilateral presentations the intact hemisphere could palliate the failure of the damaged hemisphere via callosal pathways.

## Conclusion

Deficits consequent upon unilateral prestriate lesions may pass unnoticed. However, our results show that it is possible to unmask them by comparing perceptual performances in each hemifield. Although some authors have questioned the validity of too strict a dichotomy, the present results seem to validate the concept of dual pathways since the specific deficits observed in these two patients reflect damage to the ventral system.

Both patients exhibited a detectable recovery. This suggests that the profuse interconnections within the visual system, particularly the callosal ones, may be an efficient anatomical substratum for a functional recovery.

## References

- 1 Ungerleider LG, Mishkin M. *Analysis of Visual Behavior*. Cambridge: MIT Press, 1982.
- 2 Livingstone MS, Hubel DH. *J Neurosci* **7**: 3416–3468 (1987).
- 3 Morel A, Bullier J. *Visual Neurosci* **4**: 555–578 (1990).
- 4 Zeki S, Shipp S. *Nature* **335**: 311–317 (1988).
- 5 Ettlinger G. *Cortex* **26**: 319–341 (1990).
- 6 Schiller PH, Logothetis NK. *Trends Neurosci* **13**: 392–398 (1990).
- 7 Stensaas SS, Liddington DK, Dobbelle WH. *J Neurosurg* **40**: 747–755 (1974).
- 8 Hockfield S, Toote RB, Zaremba S. *Proc Natl Acad Sci USA* **87**: 3027–3031 (1990).
- 9 Clarke S, Miklosy J. *J Comp Neurol* **298**: 188–214 (1990).
- 10 Sereno MI, McDonald CT, Allman JM. *Soc Neurosci Abstr* **451**: 3 (1988).
- 11 Corbetta M, Miezin FM, Dobmeyer, et al. *Science* **248**: 1556–1559 (1990).
- 12 Gulyas B, Roland PE, Stone E, et al. *Soc Neurosci Abstr* **16**: 621 (1990).
- 13 Lueck CJ, Zeki S, Friston KJ, et al. *Nature* **30**: 386–389 (1990).
- 14 Petersen SE, Fox PT, Posner MI, et al. *J Cog Neurosci* **1**: 153–170 (1989).
- 15 Roland PE, Gulyas B, Seitz RJ, et al. *NeuroReport* **1**: 53–56 (1990).
- 16 Zeki S. *Brain* **113**: 1721–1777 (1990).
- 17 Zihl J, Von Cramon D, Mai N. *Brain* **106**: 313–340 (1983).
- 18 Albert ML, Reches A, Silverberg R. *J Neurol Neurosurg Psych* **38**: 546–549 (1975).
- 19 Castro-Caldas A, Salgado V. *Arch Neurol* **41**: 84–87 (1984).
- 20 Bub D, Gum T. *Psychlab Manual*. Vol 85, Montreal (1990).

Received 22 March 1991;  
accepted 24 April 1991