

Postpartum Cerebral Angiopathy Mimicking Hypertensive Putaminal Hematoma: A Case Report

R. Ramnarayan, MD¹ and J. Sriganesh, MD²

¹Senior Consultant Neurosurgeon, Malar Hospitals, Chennai, India

²Consultant Obstetrician and Gynaecologist, Sultanate of Oman

Objective: To present an emerging clinical entity which may mimic another common entity. **Methods:** A 31 year-old woman complained of sudden severe headache and collapsed. She had delivered by Cesarean section one week previously. She had a normal antenatal history and did not have any evidence of hypertension. **Results:** Clinical examination revealed her to be in altered sensorium, GCS E2V2M5 with reduced movements on the left side. CT scan showed a large right putaminal hematoma with mass effect and midline shift. MRI also showed the hematoma but the MRV was normal. Despite antiedema measures and hyperventilation, the patient continued to deteriorate and so underwent right hemicraniectomy. MRA was done postoperatively and showed diffuse spasm of both middle cerebral arteries. A diagnosis of postpartum cerebral angiopathy was made and she was put on methylprednisolone and other antiedema measures were continued. With this she improved significantly. At one year she had residual hemiparesis but had returned to work. Four-vessel angiogram repeated 1 year later showed no arterial spasm. She later had cranioplasty to cover the defect. **Conclusions:** This case is presented to show that in a postpartum patient, if she presents with putaminal hematoma, postpartum angiopathy needs to be suspected and appropriate investigations and treatment, including steroids, should be given as the overall prognosis is good.

Keywords Postpartum, Intracranial Bleed, Vasospasm, Steroids, Outcome.

INTRODUCTION

Postpartum angiopathy (Call Fleming syndrome) is a reversible cerebral vasoconstriction syndrome. It usually occurs after a normal pregnancy and presents with headache and neurological deficits (1–4). Clinical outcomes are usually very good.

Address correspondence to R. Ramnarayan, MD, Senior Consultant Neurosurgeon, Malar Hospitals, Chennai, 600020, India. E-mail: r_ramnarayan@yahoo.com

CASE REPORT

A 31-year-old woman underwent an elective repeat Cesarean section. The antepartum history was normal and she had no history of hypertension. Her vital signs including blood pressure were within normal limits all through the antepartum, peripartum and the postpartum period (period of hospital stay). She also had a good and uneventful postoperative period. On the morning of her eighth postoperative day she had sudden severe global headache: within a few moments she collapsed. On examination, her blood pressure was 220/120. She was drowsy, rousable, but very drowsy (Glasgow Coma Score (GCS): E2V2M5), and a dense (0/5 power) left hemiparesis. A CT scan (Figure 1) showed a large right putaminal hematoma with severe mass effect and midline shift. She was hyperventilated and put on antiedema measures. Magnetic resonance imaging (MRI) and venography (MRV) (Figure 2) were performed under GA; however magnetic resonance angiography (MRA) could not be completed due to deteriorating O₂ saturations. MRI confirmed the hematoma and the MRV was normal. Patient was continued on ventilation and antiedema measures. CT scan (Figure 3) repeated the next day showed an increase hematoma size. Hematology, coagulation, and biochemistry screens were normal. The patient underwent right hemicraniectomy; ventilation and antiedema measures were continued. The bone flap was kept in an abdominal subcutaneous pouch. The patient was weaned off ventilation after 5 days but without significant neurological improvement: persistently altered sensorium (GCS: E2V2M5) dense (0/5) left hemiparesis. An MRA (Figure 4) performed on the seventh post-hemicraniectomy day revealed spasm of both the middle (MCA) and anterior (ACA) cerebral arteries; findings confirmed by four-vessel angiogram. A diagnosis of postpartum angiopathy was made and patient was put on methylprednisolone 1 g daily for 5 days. With this the patient showed rapid improvement. By the fifth day of methylprednisolone, she was conscious and obeying commands.

The patient was kept on regular follow up and continued on physiotherapy and other supportive measures. At the time of discharge, she was fully conscious, alert and was normal except for moderate (3/5) left-sided weakness. Serial CT scans (Figure 5) revealed gradual resolution of the hematoma. She slowly improved in her neurological status and started walking and caring for her baby. About a year later she underwent cranioplasty using the old bone flap. A repeat four-vessel angiogram revealed complete resolution of the cranial vasculature.

DISCUSSION

Reversible cerebral arterial vasoconstriction (Call Fleming) syndromes are conditions associated with spontaneously reversible segmental narrowing of the large and medium sized intracranial arteries without subarachnoid

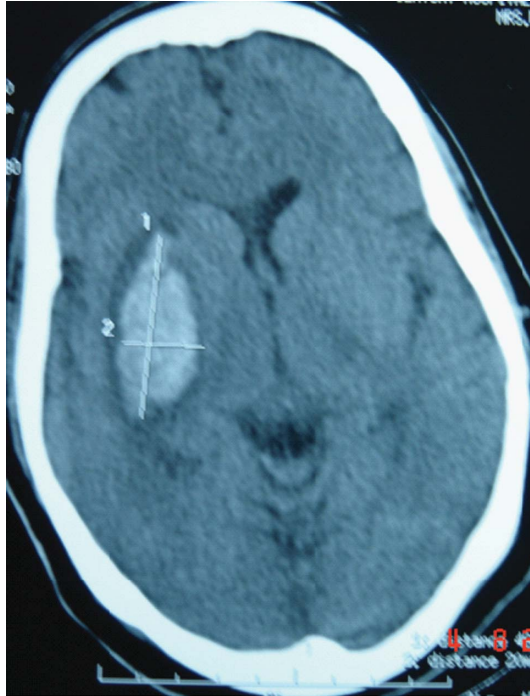


Figure 1: Plain CT scan at admission showing the moderate size right putaminal hematoma with minimal mass effect and midline shift.

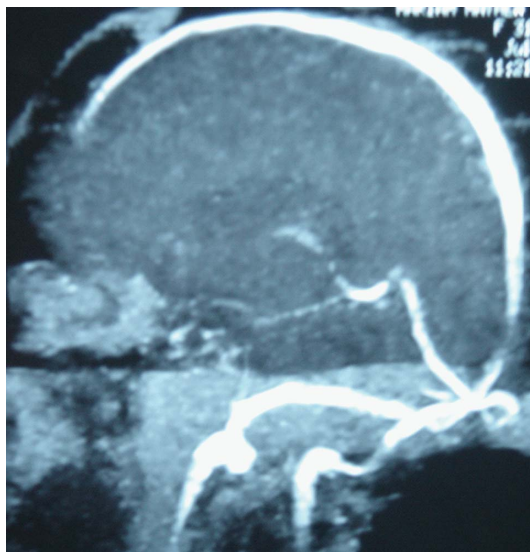

Figure 2: Magnetic resonance venogram showing the patent venous system.

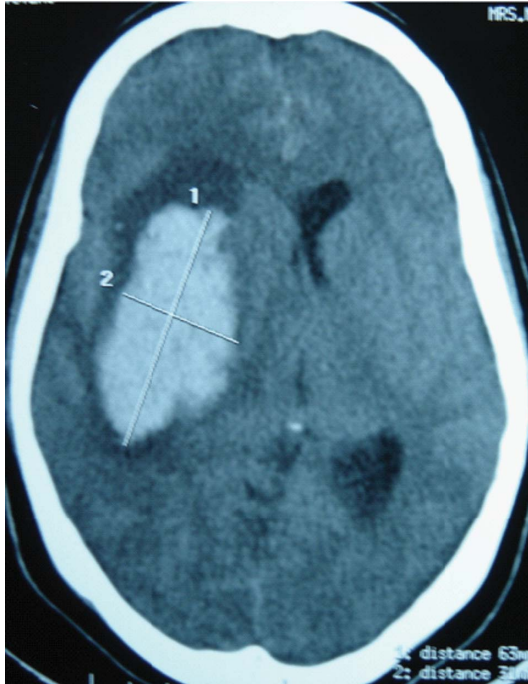


Figure 3: Repeat CT scan 2 days later showing increase in the size of the hematoma, mass effect and midline shift.

hemorrhage, infection, or inflammation (1–4). This is an important and under-recognized cause of stroke in young women (4).

Pregnancy and the puerperium are known risk factors for stroke. In fact, the incidence of stroke in pregnancy is 13 times that of non-pregnant women of the same age (5). Kittner et al (6) reported a relative risk of 0.7 of cerebral infarction during pregnancy and 8.7 in the postpartum period. The risk of intracerebral hemorrhage was 2.5 during pregnancy and 28.3 during the postpartum period (6). Jaigobin and Silver (7) analyzed 50,700 women admitted for delivery and found an incidence of stroke of 6.7%. The incidence of intracerebral hemorrhage was 38% and mortality was 23%.

Konstantinopoulos et al (8) presented a patient who had left sided weakness on the ninth day following a normal delivery. Radiology including angiogram showed scattered areas of concentric narrowing and dilatation of cerebral vessels which was suggestive of postpartum angiopathy. The woman was put on steroids and cyclophosphamide, and improved.

Calado et al (9) presented a case that developed postpartum cerebral angiopathy with an adverse clinical course. They performed a brain and leptomeningeal biopsy which showed pathological changes attributed to prolonged vasoconstriction with additional features of small vessel vasculitis. Their view

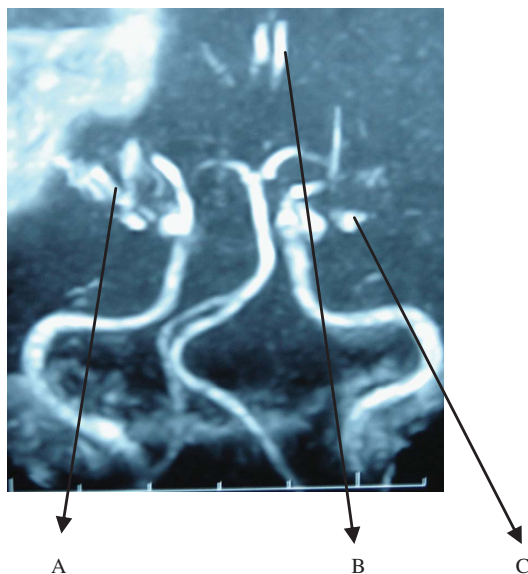


Figure 4: MR angiogram showing the spasm of middle cerebral and anterior cerebral arteries. A: showing the beaded appearance of the right middle cerebral artery. B: showing the distal anterior cerebral arteries only. The proximal portions are not visualized due to spasm. C: showing a part of the left middle cerebral artery. The rest is not visualized possibly due to spasm.

was that vasospasm, presumably related to the hormonal influences of pregnancy and puerperium, is the primary problem in postpartum cerebral angiopathy, and that vasculitis may also contribute. Ursell et al (10) presented a lady who had two episodes of postpartum angiopathy in successive pregnancies. They concluded that recognition of this condition may preclude treatment with potentially toxic therapies for vasculitis and will have implications for counseling women in subsequent pregnancies.

The treatment of this condition remains empiric, as there are insufficient data to guide practice. Calado (11) has described a management algorithm, which, with other studies (8–10), advised a short course of steroids. Other case reports (8,9) used immunosuppression but Calado advised immunosuppression only in biopsy proved vasculitis. Calado (8) and Bogousslavsky (12) used Doppler ultrasound to diagnose and follow up this condition. Song et al (13) described a patient with multiple infarcts and transcranial Doppler showed increased velocity in the right MCA distribution. The patient continued to deteriorate and balloon angioplasty of right M1 and supraclinoid segments were performed with good results. This report (13) as well as the report by Akins (14) also showed the effectiveness of Triple H (hypertension, hypervolemia, hemodilution) therapy in these cases. Akins (14) also described the use ofMRA in these cases. Geocadin (15) presented two patients, one of whom presented with

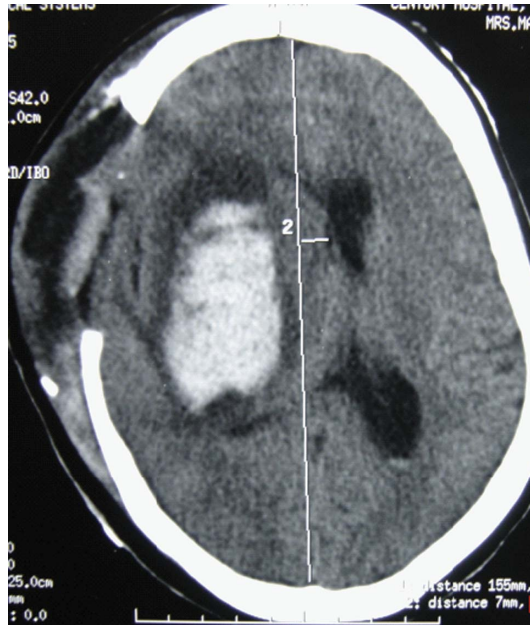

Figure 5: CT scan showing the hemicraniectomy and reduction in size of the hematoma.

a putaminal hematoma. This patient was put on methylprednisolone and cyclophosphamide. She was reviewed regularly with transcranial Doppler and at one year was absolutely normal.

The basic phenomenon in postpartum cerebral angiopathy is arterial vasoconstriction, but the pathogenesis is unclear. Many possibilities have been proposed. A temporary vasoconstriction due to hormonal factors acting directly on the intima has been put forward by some authors (1,16). This temporary vasoconstriction reduces cerebral blood flow. When blood flow decreases, autoregulation and the Cushing's reflex causes elevation of blood pressure. This acute rise in blood pressure might cause rupture of the small caliber vessels supplying the putamen resulting in hemorrhage similar to those observed in hypertension. Calado (9) showed pathological changes attributed to prolonged vasoconstriction with features of small vessel vasculitis in one patient and concluded that vasculitic changes may also contribute to hemorrhage. We believe that these are probably the mechanisms underlying the putaminal hematoma in this patient.

Vasospasm is usually seen in the setting of subarachnoid hemorrhage (SAH) or trauma. This patient had no features to suggest trauma. Subarachnoid hemorrhage during pregnancy and puerperium is recognized (7, 17), and can be excluded by CT scan and MRI. Angiography can usefully demonstrate or exclude aneurysms and arteriovenous malformations well. In this woman

all these were negative. Thus, vasospasm due to extravasation of blood seems very unlikely.

Postpartum cerebral angiopathy is being diagnosed more frequently. This condition has a very good prognosis, especially if steroids are used early. This case is presented to show that in postpartum patients with putaminal hematomas, it is very important to suspect postpartum angiopathy and treat accordingly especially if the patients were not hypertensive during pregnancy. The role of a short course of steroids in this condition is reemphasized.

REFERENCES

1. Singhal AB, Koroshetz W, Caplan LR. Cerebral vasoconstriction syndromes. In *Uncommon Causes of Stroke*. Cambridge University press; 2001:114–123.
2. Call GK, Fleming ML, Scalfon S, Levine H, Kistler JP, Fisher CM. Reversible cerebral segmental vasoconstriction. *Stroke* 1988; 19:1159–1170.
3. Brick JF. Vanishing cerebrovascular disease of pregnancy. *Neurology* 1988; 38:804–806.
4. Singhal AB, Bernstein RA. Postpartum angiopathy and other cerebral vasoconstriction syndromes. *Neurocrit Care* 2005; 3:91–97.
5. Weiber DO. Ishaemic cerebrovascular complications of pregnancy. *Arch Neurol* 1985; 42:1106–1113.
6. Kittner SJ, Stern BJ, Feeser BR, Hebel R, Nagey DA, et al. Pregnancy and the risk of stroke. *N Engl J Med* 1996; 335:768–764.
7. Jaigobin C, Silver FL. Stroke and pregnancy. *Stroke* 2000; 31:2948–2951.
8. Konstantinopoulos PA, Mousa S, Khairallah R, Mtanos G. Postpartum cerebral angiopathy: an important diagnostic consideration in the postpartum period. *Am J Obstet Gynecol* 2004; 191:375–377.
9. Calado S, Vale-Santos J, Lima C, Viana-Baptista M. Postpartum cerebral angiopathy: vasospasm, vasculitis or both. *Cerebrovasc Dis* 2004; 18:340–341.
10. Ursell MR, Marras CL, Farb R, Rowed DW, Black SE, Perry JR. Recurrent intracerebral haemorrhage due to postpartum cerebral angiopathy. Implications for management. *Stroke* 1998; 29:1995–1998.
11. Calado S, Viana-Baptista M. Benign cerebral angiopathy; Postpartum cerebral angiopathy: characteristics and treatment. *Curr Opin Cardio Med* 2006; 8:201–212.
12. Bogousslavsky J, Despland PA, Regli F, Dubuis PY. Postpartum angiopathy: Reversible vasoconstriction assessed by transcranial Doppler ultrasound. *Eur Neurol* 1989; 29:102–105.
13. Song JK, Fischer S, Seifert TD, Cacayorin ED, Alexandrov AV, Malkoff MD, Grotta JC, Campbell MS. Postpartum cerebral angiopathy: atypical features and treatment with intracranial balloon angioplasty. *Neuroradiology* 2004; 46:1022–1026.
14. Akins PT, Levy KJ, Cross AH, Goldberg MP, Schieber MH. Postpartum cerebral vasospasm treated with hypovolemic therapy. *Am J Obstet Gynecol* 1996; 175:1386–1388.

15. Geocadin RG, Razumovsky AY, Wityk RJ, Bhardwaj A, Ulatowski JA. Intracerebral hemorrhage and postpartum cerebral vasculopathy. *J Neurol Sci* 2002; 205:29–34.
16. Donaldson JO. Eclampsia and postpartum cerebral angiopathy. *J Neurol Sci* 2000; 178:1.
17. Mas JL, Lamy C. Stroke in pregnancy and the puerperium. *J Neurol* 1998; 245:305–313.

Copyright of Hypertension in Pregnancy is the property of Taylor & Francis Ltd and its content may not be copied or emailed to multiple sites or posted to a listserv without the copyright holder's express written permission. However, users may print, download, or email articles for individual use.