



ELSEVIER


<http://intl.elsevierhealth.com/journals/ijid>

## LETTER TO THE EDITOR

### Difficulties in the diagnosis of delayed contralateral hemiparesis due to Varicella-Zoster Virus in an HIV-positive patient

Herpes zoster is much more frequent among HIV-infected patients compared to immunocompetent populations.<sup>1</sup> Delayed contralateral hemiparesis (DCH) is a rare but serious complication that can occur weeks to months after an episode of herpes zoster ophthalmicus (HZO).<sup>1</sup> Previous varicella-zoster virus (VZV) infection could be associated with the pathomechanism in cases of central nervous system (CNS) involvement, despite negative VZV-DNA in PCR of the cerebrospinal fluid (CSF).<sup>2</sup> Herein, we describe the case of an HIV-positive patient who developed left hemiparesis due to cerebral angiitis, as evident from MRI images, four months after HZO on the right side.

A 32-year-old HIV-positive male developed left hemiparesis four months after HZO on the right side. At that time, he was treated with acyclovir (10 mg/kg/q 8 hr, intravenously, for ten days). He had begun highly active antiretroviral therapy (HAART; zidovudine/lamivudine/lopinavir plus ritonavir) two weeks before the most recent admission. His lymphocyte T CD4 cell count was 59 cells/ $\mu$ l (3%) and the HIV viral load was >500 000 copies/ml. Serology markers for toxoplasmosis, Chagas disease, hepatitis B and hepatitis C infection were negative, including the venereal disease research laboratory (VDRL) test. Serum VZV IgG was positive, but negative for VZV IgM, both by immunofluorescence assay (IFA) performed on VZV antigen slides (BION Enterprises, IL, USA). For the IgG assay, a second antibody was fluorescein isothiocyanate (FITC)-conjugated rabbit anti-human IgG, specific for gamma chains (DAKO, Denmark). For the IgM assay, a second antibody was FITC-conjugated rabbit anti-human IgM, specific for mu chains (DAKO, Denmark). The CSF revealed 5 mononuclear cells/mm<sup>3</sup>, protein level 0.35 mg/dl, glucose level 56 mg/dl; Ziehl–Neelsen, Indian ink and Gram stains were negative. Multiplex herpesvirus (MHV) PCR for herpes simplex virus (HSV) 1/2, VZV, cytomegalovirus (CMV), Epstein–Barr virus (EBV) and human herpes virus-type 6 DNA (Herplex, Genomica, Spain) was performed on the CSF, all giving a negative result. No antibodies for VZV were found in the CSF by IFA. A contrast-enhanced cerebral CT scan did not disclose abnormalities. An ischemic lesion in the right parieto-occipital area and an uncharacteristic low signal intensity on T2-weighted images of the subcortical temporo-occipital lobes, with extension to the right semioval center and corona radiata, could be

detected by gadolinium-delayed enhancement of MRI. MRI angiography showed multiple segmental narrowing of the right internal carotid and vertebral arteries, and a stop in the rolandic artery (Figure 1). There was lack of opacification in the sylvian branches and no contrast enhancement of the parietal and occipital lobes on the same side. A diagnosis of VZV-associated granulomatous vasculitis was made. Intravenous acyclovir (10 mg/kg tid) plus prednisolone (60 mg qd, gradually diminishing) was administered for three weeks. On day 21, all treatments were withdrawn and the patient was discharged. The hemiparesis gradually healed, with kinetic rehabilitation during the 12-month follow-up period, with concurrent angiographic pattern improvement.

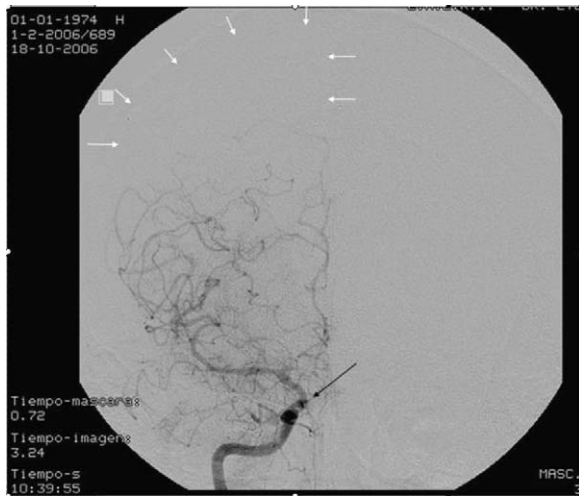
The pathogenesis of this syndrome is thought to be due to either direct VZV invasion of the cerebral arteries by extension along the intracranial branches of the trigeminal nerve or virion spread through the circulatory system, resulting in inflammation of the internal carotid artery or one of its branches on the side ipsilateral to the rash.<sup>1</sup> Aneurysmal lesions reported in the literature showed distribution from the proximal to the distal cerebral arteries. These characteristics suggest that the spread of VZV occurs through the cerebral arteries and not through the trigeminal nerve.<sup>3</sup>

At onset, the typical presentation includes headache and hemiplegia occurring in a patient with a recent history of HZO,<sup>1</sup> as in the case we present. MRI commonly demonstrated widespread lesions, consistent with the ischemic lesion in the right parieto-occipital area shown in this patient. The multiple segmental vascular narrowing observed in the cerebral angiography of our patient is in keeping with granulomatous vasculitis, as described in the literature.<sup>4</sup>

Examination of CSF in cases of CNS vasculitis often reveals mononuclear cell pleocytosis and increased protein levels,<sup>1</sup> conditions that did not occur in our case.

The sensitivity of a multiplex-nested PCR assay for the simultaneous detection of five human herpesviruses (CMV, EBV, VZV, HSV-1/2 and HHV-6) in CSF has been reported to be high for CMV, but was not evaluable for VZV disease, because of the small number of patients.<sup>5</sup> In our experience with the MHV technique, VZV was detected in the CSF of 4 AIDS patients out of 30 with neurological symptoms; in all cases, the diagnosis was meningitis with cutaneous zoster.<sup>6</sup>

When CSF shows normal parameters, the PCR VZV test result is negative, whereas few cases of CSF with altered values show positive PCR.<sup>7</sup> Although PCR could not detect VZV-DNA in CSF, previous VZV infection might be closely



**Figure 1** MRI angiography showing multiple segmental narrowing of the right internal carotid and vertebral arteries, and a stop in the rolandic artery (black arrow). There is also lack of opacification in the sylvian branches (white arrows).

related to the pathomechanism of the regional encephalitis.<sup>2</sup> Gildeen et al. have documented a low sensitivity for PCR in the setting of subacute or chronic CNS VZV infection, and have stressed that intrathecal synthesis of VZV-specific antibodies might be a more reliable diagnostic measure in such cases, particularly with intervals of weeks to months between zoster and onset of neurological disease.<sup>8</sup> In this way, IgG anti-VZV intrathecal synthesis was not detected in our patient. Normally, intrathecally synthesized IgG antibodies are measured in the post-acute stage of disease and persist for several years, although the intrathecal immune response might be delayed or absent when antiviral treatment is started early.<sup>9,10</sup> The clinical deficits and vasculitic MRI changes commonly regressed with antiviral and immunosuppressive therapy.<sup>4</sup> Complete recovery was achieved in this patient after the antiviral scheme was established, although a mortality rate of 20–25%, with a high probability of permanent neurologic sequelae among survivors, has been published in the literature.<sup>1</sup>

Opportunistic infections, such as fungi, syphilis, herpes zoster, septic arteritis in bacterial endocarditis and direct HIV effects on endothelial cells, are recorded among the etiologies of infectious vasculitis in the CNS of patients with HIV infection.<sup>11</sup> None of these were present in our patient, except for herpes zoster and HIV. VZV, CMV and *Treponema pallidum* are known to cause vasculitis in the CNS in the absence of systemic manifestations of the primary disease. Direct effects of the retrovirus as the source of vasculitis were estimated when no specific antibodies for these infections were present in the CSF,<sup>12</sup> although no accurate diagnosis was performed in these cases.

In conclusion, diagnosing DCH can be difficult in the absence of VZV-DNA in CSF, until new technologies, such as real-time PCR with higher sensitivity, are evaluated with regard to VZV-associated syndromes. Patient records, clinical presentation, response to specific antiviral therapy and, mainly, the angiography images should be taken into account in the diagnosis of VZV-associated cerebral vasculitis in HIV patients.

**Conflict of interest:** No conflict of interest to declare.

## References

- Gnann Jr JW. Varicella-Zoster virus: atypical presentations and unusual complications. *J Infect Dis* 2002;**186**(suppl 1):S91–8.
- Kubota M, Kawamura M. Dramatic improvement of urinary retention and the left lower limb paresis with methylprednisolone in a case of regional encephalitis following varicella zoster infection. *No To Shinkei* 2004;**56**:339–43.
- Saraya T, Shimura C, Wada H, Aoshima M, Goto H. Evidence for vascular spread of Varicella Zoster-associated vasculopathy. *Ann Intern Med* 2006;**144**:535–7.
- Berkefeld J, Enzensberger W, Lanfermann H. MRI in human immunodeficiency virus-associated cerebral vasculitis. *Neuroradiology* 2000;**2**:526–8.
- Quereda C, Corral I, Laguna F, Valencia ME, Tenorio A, Echeverria JE, et al. Diagnostic utility of a multiplex herpesvirus PCR assay performed with cerebrospinal fluid from human immunodeficiency virus-infected patients with neurological disorders. *J Clin Microbiol* 2000;**38**:3061–7.
- Mammana L, Moreno A, Villafaña MF, Trione H, Corti M, Bouzas MB. Metodología diagnóstica para el estudio del compromiso del Sistema Nervioso Central (SNC) por virus Herpes (HVs) en pacientes con enfermedad HIV/SIDA. VIII Congreso Argentino de Virología (19-22 de septiembre de 2005). Buenos Aires Argentina. Abstract 10707. <http://www.aam.org.ar/Posters.pdf>.
- García-Bardeci D, Pena MJ, Suárez-Bordón P, Aladro Y, Pérez-González C, Lafarga B. Value of the polymerase chain reaction in the diagnosis of herpes infections of the nervous system. *Enferm Infecc Microbiol Clin* 2004;**22**:150–5.
- Gilden DH, Bennett JL, Kleinschmidt-DeMasters BK, Song DD, Yee AS, Steiner I. The value of cerebrospinal fluid antiviral antibody in the diagnosis of neurologic disease produced by Varicella Zoster virus. *J Neurol Sci* 1998;**159**:140–4.
- Cinque P, Bossolasco S, Vago L, Fornara C, Lipari S, Racca S, et al. Varicella-zoster virus (VZV) DNA in cerebrospinal fluid of patients infected with human immunodeficiency virus: VZV disease of the central nervous system or subclinical reactivation of VZV infection? *Clin Infect Dis* 1997;**25**:634–9.
- Linde A, Klapper PE, Monteyne P, Echevarria JM, Cinque P, Rozemberg F, et al. Specific diagnostic methods for herpesvirus infections of central nervous system: a consensus review by the European Union Concerted Action on Virus Meningitis and Encephalitis. *Clin Diagn Virol* 1997;**8**:83–104.
- Weisberg LA. Neurologic abnormalities in human immunodeficiency virus infection. *South Med J* 2001;**94**:266–75.
- Deshpande AK, Patnaik MM. Nonopportunistic neurologic manifestations of the human immunodeficiency virus: an Indian study. *MedGenMed* 2005;**7**:2.

Humberto A. Metta\*, Lilia Mammana, Liliana Redini, Florencia Bruggesser, Maria B. Bouzas,

*Infectious Diseases Hospital F.J. Muñiz, Buenos Aires, Argentina*

\*Corresponding author. Chief of Infectious Disease, Unit 17, Infectious Diseases Hospital F. J. Muñiz, Tucuman 1630, Piso 3°, Dpto C, Buenos Aires, 1050, Argentina.

Tel.: +54 1146910976; fax: +54 1143742024  
E-mail address: [hmetta@sinectis.com.ar](mailto:hmetta@sinectis.com.ar) (H.A. Metta)

Corresponding Editor: Mark Holodniy

26 September 2008