
Internal carotid artery thrombosis after blunt maxillofacial trauma

Timothy J. Atkinson, DDS,^a Yakir Anavi, DMD,^b and Michael Gornish, MD,^c
Detroit, Mich., and Petah Tiqva, Israel

DETROIT RECEIVING HOSPITAL AND BEILINSON MEDICAL CENTER

Two cases of internal carotid artery thrombosis associated with a maxillary Le Fort III and mandibular angle fractures after maxillofacial blunt injuries are described. Both patients had delayed neurologic deficit and hemiparesis. The diagnosis was made by carotid angiography after clinical evidence of thromboembolism. Clinical aspects and etiology, with special attention to mechanism of injury, are discussed. (ORAL SURG ORAL MED ORAL PATHOL 1991;72:408-11)

Traumatic occlusion or stenosis of the internal carotid artery (ICA) is a rare complication of blunt maxillofacial complex injuries.¹ Blunt carotid injuries, which are usually caused by motor vehicle accidents, may not be recognized until manifested by neurologic deficit. The clinical course may vary considerably in both the type of symptoms and the interval between injury and onset of symptoms. Two unusual cases of ICA thrombosis and hemiparesis after nonpenetrating trauma to the maxillofacial region are documented. The clinical aspects and the pathogenesis of ICA thrombosis are reviewed and analyzed.

CASE REPORTS

Case 1

A 19-year-old female driver involved in an automobile accident was unconscious during the extrication and evacuation to the hospital. At initial examination the patient was moving all extremities and did not respond to painful stimuli. The pupils were fixed, with anisocoria. The left pupil was 4 mm and responded only to direct light stimulus, and the right pupil was 7 mm and did not respond consensually or directly to light stimulus. Associated injuries involved a maxillary Le Fort III fracture and comminuted right mandibular angle fractures, right pneumothorax, and a brain

concussion. No head and neck lacerations were noted, and no bruit was heard over either carotid arteries. Examination of the abdomen and genitourinary system revealed no abnormalities. Computed tomographic (CT) scan of the brain within the first hour of admission appeared normal. Facial CT scan demonstrated the complex maxillary Le Fort III fractures. The patient regained consciousness gradually, becoming alert, responding to commands, and showing no neurologic abnormality.

Eight days after the injury, paresis of the left arm and subsequently of the left leg developed. Repeated CT scan of the brain demonstrated decreased attenuation throughout the right cerebral hemisphere, denoting a cerebral infarct. Right carotid arteriogram revealed a large intra-arterial clot with an almost complete occlusion at the intracranial bifurcation of the right ICA with extension into the right anterior and middle cerebral arteries (Fig. 1). Multiple small emboli were present in the distal aspect of the middle cerebral artery branches. The patient was treated with dexamethasone, 40 mg/day intravenously, to minimize the cerebral edema and intracranial pressure. Facial and mandibular fractures were surgically treated by open reduction and internal wire fixation.

The patient had an uneventful postoperative course. Three months after the accident the patient's neurologic condition stabilized with a moderate residual left-sided hemiparesis.

Case 2

A 31-year-old woman, an unrestrained passenger involved in an automobile accident, was combative on admission after sustaining multiple traumatic injuries. Facial involvement included a 10 cm laceration extending from the nasofrontal area through the canthal and lacrimal apparatus to the left cheek, with underlying comminuted naso-orbital and zygomaticomaxillary complex fractures. Left

^aAttending Oral and Maxillofacial Surgeon, Detroit Receiving Hospital; presently in private practice, Ceifinger Medical Center, Danville, Pa.

^bFormerly Clinical Fellow, Detroit Receiving Hospital; presently Senior Attending Surgeon, Department of Oral and Maxillofacial Surgery, Beilinson Medical Center, Petah Tiqva.

^cSenior Attending Physician, Neuroradiology Section, Department of Radiology, Beilinson Medical Center, Petah Tiqva.
7/12/26892

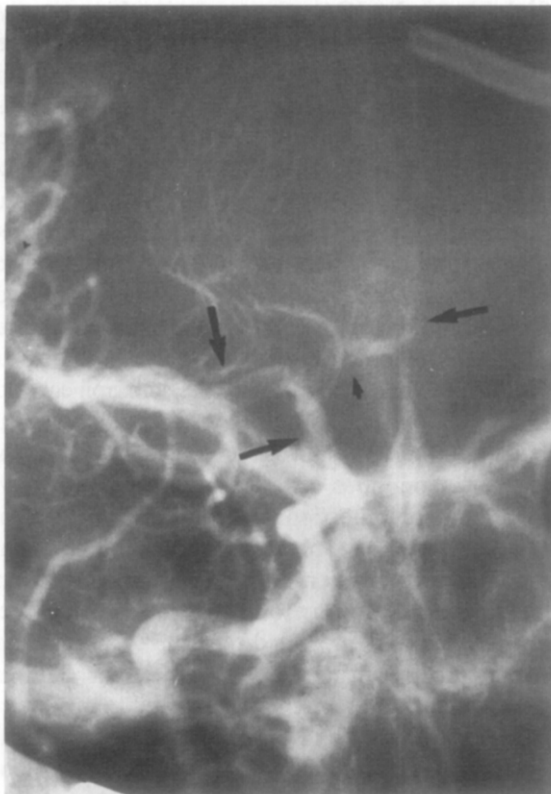

Fig. 1. Case 1. Anteroposterior angiogram of right common carotid artery shows supraclinoid internal carotid (*lowermost arrow*) with poor filling. Intraluminal clot seen as filling defect with marginal opacification (tram-track sign) in proximal portion of right middle cerebral artery (*right arrow*). Origin of right anterior cerebral artery occluded by same clot, whose distal extent is shown in first arterial segment (*small arrow*). Additional filling defect (embolus) in proximal anterior pericallosal artery is present (*left arrow*).

mandibular fractures of the angle and subcondylar areas were also evident. No other systemic injuries besides lacerations of the right hand and knee were present. The patient neurologically had a Glasgow coma score of 8, anisocoria with a 3 mm right reactive pupil and a 4 mm unreactive left pupil, and a left peripheral partial seventh nerve paresis. She moved all four extremities spontaneously and responded to painful stimuli.

Nine hours after the injury the patient's level of consciousness improved considerably and she responded to commands. Hemiparesis of the right upper and lower extremities developed after 32 hours. Repeated CT scan of the brain was normal, with no evidence of cerebral injury. A facial CT scan demonstrated the severely comminuted midfacial fractures. Temporary stabilization of the facial fractures with debridement and closure of the lacerations was performed before definitive reconstruction could be done.

Four days after the injury the right hemiparesis and left

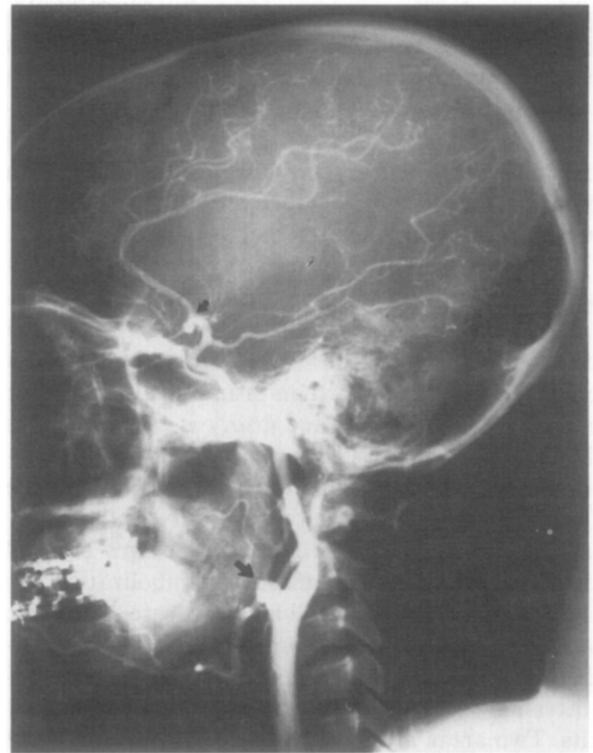


Fig. 2. Case 2. Lateral left carotid angiogram shows nonfilling of middle cerebral sylvian branches (*curved arrow*). Note filling of small lenticulostriate branches of proximal middle cerebral artery. Proximal left external carotid artery is abruptly cut off beyond origins of facial and occipital branches by emboli (*arrow*).

peripheral partial seventh nerve paresis continued, and an expressive dysphasia developed. Determination of a left ischemic cerebral infarct was confirmed by a left cerebral lucency with edema on the CT scan and a left carotid arteriogram. The arteriogram revealed an occlusion of the left middle cerebral artery near its origin and of the external carotid artery above the facial branch (Fig. 2). The radiologic appearance suggested an intimal flap of the artery with the resulting distal occlusions. No treatment was deemed necessary for the middle cerebral arterial infarct. Ten days after the injury definitive reconstruction of the left orbit, zygomaticomaxillary complex, and mandible was performed, with calvarial bone grafts and reconstructive plates.

The patient had an uneventful postoperative course with progressive improvement of the neurologic deficiency throughout the remainder of her hospitalization. At discharge the right hemiparesis, left peripheral partial seventh cranial nerve paresis, and speech deficit persisted. To date, 1 year after the injury, a moderate right hemiparesis and left peripheral partial seventh cranial nerve paresis continues.

DISCUSSION

ICA injuries can occur as a sequela to penetrating or blunt trauma. Direct penetrating injuries to the

ICA may cause complete or partial arterial transection, carotid-cavernous sinus fistula, arteriovenous fistula, mural dissecting aneurysm, pseudoaneurysm (paravascular encapsulated hematomas that communicate with the lumen of the artery), or arterial thrombosis. Indirect vascular damage associated with blunt ICA injuries may induce thrombosis within the vessel, mural dissection, or both.

The pathogenesis of traumatic occlusion or stenosis of the ICA is generally believed to be a tunica intima tear of the artery with subsequent flap elevation by the force of blood flow.² Arteriosclerotic plaques predispose vessels toward an intimal tear. Partial or complete thrombosis of the artery is caused by this dissection and the resultant exposure of the underlying connective tissue to platelets. Propagation of the thrombus either proximally or distally could totally occlude the ICA. In the secondary stages of local thrombus formation an extension or embolization into the cerebral circulation will lead to severe neurologic sequelae or death. The thrombus may also be the nidus for emboli with the potential to occlude small intracranial vessels with the resultant neurologic deficits. Two areas are most frequently involved: (1) at the cervical segment of the ICA, usually 1 to 3 cm above its bifurcation, which is also common for plaque formation, and (2) near the base of the skull and just distal to the origin of the posterior communicating artery. Four possible types of blunt craniocervical and maxillofacial injury have been suggested as possible mechanisms leading to traumatic thrombosis or dissection of the ICA³:

1. A direct blow to the anteromedial region of the neck causes thrombosis more commonly in older persons, by fracture of an atheromatous plaque at the carotid bifurcation.⁴
2. In a blow to the side of the head or neck, with hyperextension and rotation or lateral flexion of the neck toward the opposite side, the cervical ICA is forced and stretched against the transverse processes of the C-2 and C-3 vertebrae, causing intimal tears and arterial dissection.⁵ This occurs most commonly in young victims of motor vehicle or motorcycle accidents.
3. Blunt intraoral trauma by foreign objects, especially prevalent in children, may injure the ICA at the posterior aspect of the tonsillar fossa.⁶
4. Basal skull fractures involving the floor of the middle cranial fossa in areas such as the carotid canal cause thrombosis of the intrapetrous portion of the ICA.

The association of blunt ICA trauma with maxillofacial injuries and mandibular fractures has been rarely reported.^{1,7} The literature has also reported

thrombosis of the ICA after orthognathic surgery⁸ and temporomandibular surgery.⁹ In the current report our patients were involved in motor vehicle accidents and had no evidence of cervical trauma. The ICA thrombosis is thought to have occurred either because of the maxillary Le Fort III or the associated mandibular angle fractures, with trauma to the intratemporal portion of the ICA. In the reviewed cases where the mandible was involved, the mandibular angle was consistently fractured and displaced. Anatomically, the carotid artery is posterior and medial to the mandibular angle. With the mandible usually superior to the bifurcation of the common carotid, an injury to the mandibular bone could result in damage to either the internal or external carotid system. A more ominous complex injury would involve the intratemporal portion of the ICA. It has been suggested that a bony spicule from the mandible may lacerate the carotid artery. Moreover, the biomechanics of ICA injury appear to involve a vector of force in a posterior and medial direction, or a torsional shearing force resulting from such a vector. The artery is momentarily stretched or twisted to produce a disruption of the tunica intima. This could then lead to elevation of an intimal flap by the force of the blood flow, which could result in a thrombus formation at the site of the intimal tear with or without overt dissection. Another speculation for the ICA thrombosis in our cases is as a result the maxillary Le Fort III fractures. This trauma was thought to have occurred when the maxillary tuberosity was separated from the pterygoid plates, causing a force vector leading to the ICA injury.

The onset of neurologic symptoms in patients with traumatic ICA occlusion may be immediate, within 24 to 48 hours, or late, days or weeks after the injury.¹⁰ Characteristically, the onset of detectable neurologic deficits is significantly delayed. This was also true in our patients, who had hemiparesis 1 and 8 days after their motor vehicle accidents. The delayed neurologic symptoms may well reflect the lag period between the original injury and the gradual formation of the carotid arterial thrombus, or the cerebral embolization from the thrombus.⁶ After traumatic ICA thrombosis, cerebral ischemia may present clinically as transient ischemic attacks caused by the release of emboli from the thrombus. Patients with further serious neurologic deficit show lowered level of consciousness, progressive monoparesis or hemiparesis, dysphasia, aphasia, seizures, and sensory disturbances, resulting from cerebral infarction. In fatal cases death occurs from extensive cerebral infarction. Unfortunately, in these patients the nature of the carotid injury may not be appreciated until embolism

with cerebral infarction occurs. The most likely cause of our patient's delayed neurologic deficits and hemiparesis was cerebral ischemia resulting from movement of an embolus into the middle cerebral artery from the area of thrombosis at the site of the intimal tear in the ICA.

Diagnosis of carotid artery occlusions in nonpenetrating injuries is difficult because the clinical picture resembles that of the more common epidural or subdural hematoma. The definitive diagnosis in the presented cases was readily confirmed by contrast carotid angiography and revealed a dissection and thrombosis of the ICA. On injection of the ICA with radiocontrast material, the intracranial branches were poorly visualized or not seen at all. Diagnosis of blunt carotid injury entails accurate visualization of the arterial anatomy.¹¹ Therefore angiography is indicated for maxillofacial injuries when the clinical suspicion of vascular injury is high.

These patients with hemiparesis were treated conservatively because they would have gained little from vascular reconstruction and because a cerebral hemorrhage may have resulted from the procedure.

The present report emphasizes three points:

1. Blunt injury and thrombosis to the ICA may be associated with mandibular angle fractures or Le Fort III facial fractures.
2. The onset of symptoms is often delayed and suggested by the development of neurologic deficits.
3. The diagnosis is often further obscured by concomitant intracranial injury and is assisted by angiography.

REFERENCES

1. Garrison RL, Ristuccia JM, Maloney PL, Doku HC. Multiple facial trauma complicated by occlusion of the internal carotid artery. *J Oral Surg* 1975;33:131-3.
2. Moar JJ. Traumatic rupture of the cervical carotid arteries: an autopsy and histopathological study of 200 cases. *Forensic Sci Int* 1987;34:227-44.
3. Woodhurst WB, Robertson WD, Thompson GB. Carotid injury due to intraoral trauma: case report and review of the literature. *Neurosurgery* 1980;6:559-63.
4. New PFJ, Momose KJ. Traumatic dissection of the internal carotid artery at the atlantoaxial level, secondary to nonpenetrating injury. *Radiology* 1969;93:41-9.
5. Davis JM, Zimmerman RA. Injury of the carotid and vertebral arteries. *Neuroradiology* 1983;25:55-69.
6. Pinter SE. Carotid thrombosis due to intraoral trauma: an unusual complication of a common childhood accident. *N Engl J Med* 1966;274:764-7.
7. Berman DN. Occlusion of the internal carotid artery associated with mandibular fracture. *J Oral Surg* 1975;33:134-5.
8. Sanni KS, Campbell RL, Rosner MJ, Goyne WB. Internal carotid arterial occlusion following mandibular osteotomy. *J Oral Maxillofac Surg* 1984;42:394-9.
9. Sullivan WG, Kawamoto HK Jr. Carotid thrombosis following surgical release of temporomandibular ankylosis. *Plast Reconstr Surg* 1989;83:153-4.
10. Mokri B, Piepgras DG, Houser OW. Traumatic dissections of the extracranial internal carotid artery. *J Neurosurg* 1988; 68:189-97.
11. Kreutz RW, Bear SH. Selective emergency arteriography in cases of penetrating maxillofacial trauma. *ORAL SURG ORAL MED ORAL PATHOL* 1985;60:18-22.

Reprint requests:

Yakir Anavi, DMD
Department of Oral and Maxillofacial Surgery
Beilinson Medical Center
Petah Tiqva 49100, Israel