

Anterior Inferior Cerebellar Artery Dissecting Aneurysm in a Juvenile

—Case Report—

Shintaro FUKUSHIMA, Masaru HIROHATA, Yuji OKAMOTO*,
Shin YAMASHITA, Shigenobu ISHIDA**, and Minoru SHIGEMORI

Departments of Neurosurgery and

***Neuropsychiatry, Kurume University School of Medicine, Kurume, Fukuoka;*

**Neurological Surgery Center, Saiseikai Yahata General Hospital, Kitakyushu, Fukuoka*

Abstract

A 15-year-old girl presented with a distal anterior inferior cerebellar artery (AICA) dissecting aneurysm manifesting as sudden onset of general tonic-clonic convulsion while singing a song. Physical and neurological examinations found headache, vomiting, right perceptive deafness, and right cerebellar ataxia. Cranial magnetic resonance imaging demonstrated a hemorrhagic mass in the brainstem region, and digital subtraction angiography revealed a fusiform dilatation of the anterior pontine segment of the right AICA. The diagnosis was dissecting aneurysm. Endovascular embolization was performed for aneurysm and parent artery occlusion using a Guglielmi detachable coil and 9 TruFill detachable coil systems, respectively, 2 weeks after occipital artery-AICA anastomosis. No ischemic complications were seen, and her neurological deficits completely recovered after the interventional therapy.

Key words: anterior inferior cerebellar artery, dissecting aneurysm, endovascular embolization, occipital artery-anterior inferior cerebellar artery anastomosis, general convulsion, juvenile

Introduction

Dissecting aneurysms of the distal anterior inferior cerebellar artery (AICA) are extremely rare, with a frequency of 0.03% to 0.5%. Sixty-two cases of distal AICA aneurysm have been reported.^{2-6,8)} The 43 female and 17 male patients (2 unreported) were aged from 21 to 85 years (mean 48.7 years). There was no dominant side. Distal AICA aneurysm occurs around the meatal loop near the internal auditory artery. This loop, which is a site of vascular bifurcation during the embryogenic phase, is assumed to be shaped by the disappearance of another branch. Congenital fragility may be involved in the aneurysmal formation.¹⁾ All reported fusiform aneurysms were located at the anterior pontine segment.^{4,6)} However, the natural history and therapeutic strategy have not been established.

We treated a 15-year-old girl with a distal AICA aneurysm manifesting as sudden onset of general tonic-clonic seizure, treated by endovascular em-

bolization of the distal portion of the AICA dissecting aneurysm after right occipital artery (OA)-AICA anastomosis.

Case Report

A 15-year-old girl suffered sudden onset of general tonic-clonic seizure with loss of consciousness while singing a song, and was transferred to a neighboring hospital by ambulance. Computed tomography (CT) revealed no abnormal findings. Her symptoms were transient and improved immediately in response to symptomatic therapy, which was carried out as soon as possible. However, 2 days after her first convulsion, she developed severe headache, vomiting, dizziness, and tinnitus on the right, and magnetic resonance imaging on the same day demonstrated an extraaxial hemorrhagic lesion at the right pontomedullary junction without subarachnoid hemorrhage (Fig. 1). She was transported to our hospital 5 days after admission due to progressive worsening of the headache and regrowth of the hematoma on CT. Her past medical and familial history was unremarkable.

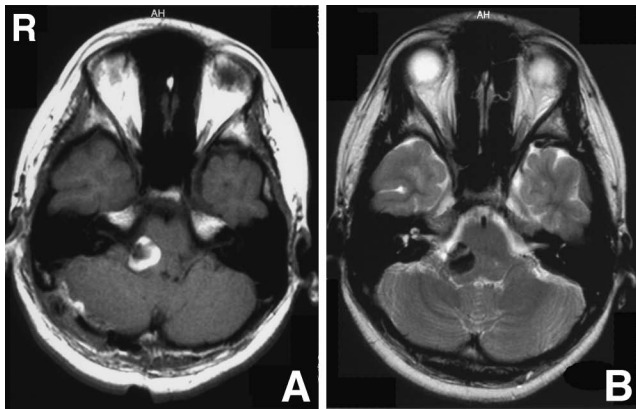


Fig. 1 A: T₁-weighted magnetic resonance (MR) image showing a heterogeneous mass lesion (15 × 15 mm) at the right pontomedullary junction. B: T₂-weighted MR image showing a flow void with intimal flap at the right pontomedullary junction.

On admission, her consciousness was alert, and she had right perceptive deafness, truncal ataxia, and poor tandem gait. Digital subtraction angiography (DSA) revealed a fusiform dilatation of the anterior pontine segment of the right AICA (Fig. 2). The right posterior inferior cerebellar artery (PICA) showed hypoplasia, and the bilateral PICA territories were perfused supplementarily by the left PICA. Neither the internal auditory artery nor the subarcuate artery was identified. The diagnosis was right AICA dissecting aneurysm.

The endovascular approach was selected for aneurysm and parent artery occlusion. However, the present patient had the risk of diffuse cerebellar infarction due to the hypoplastic right PICA, and the possibility of worsening deafness, so we planned to carry out the necessary procedures after bypass surgery. OA-AICA anastomosis was performed under general anesthesia 20 days after the seizure attack. During surgery, we could not directly identify the dissecting lesion of the AICA. We anastomosed the right AICA cortical segment and the OA by the end-to-side method with 10-0 nylon, and adequate flow of both the AICA and OA were confirmed with Doppler ultrasonography after completion of bypass surgery. However, DSA could not confirm the patency of these vessels 7 days after surgery. External carotid angiography also revealed absence of patency, even with balloon occlusion of the basilar artery based on the right AICA.

Conservative treatment might not result in resolution of the aneurysm, and she clearly had a risk of future rupture, so intravascular embolization using coils was necessary to plan in anticipation of col-

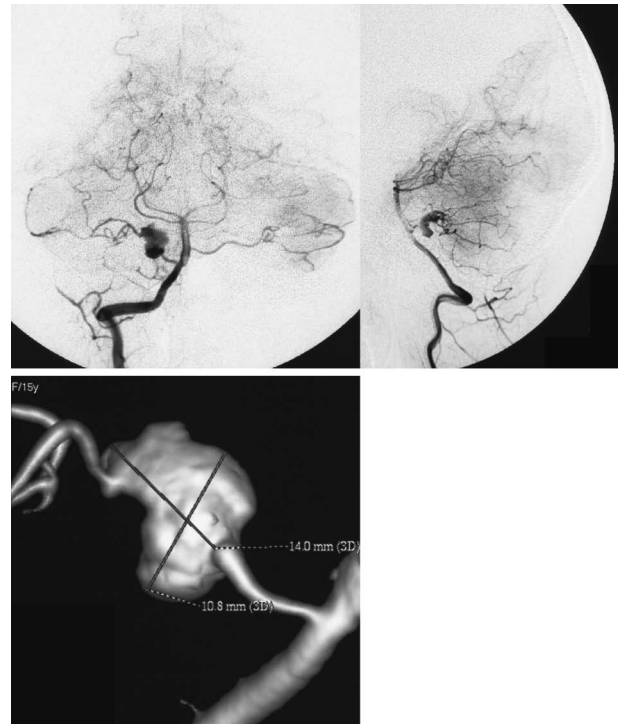


Fig. 2 Digital subtraction angiograms (DSAs) of the right vertebral artery showing a fusiform dilatation of the anterior pontine segment of the right anterior inferior cerebellar artery (upper), and three-dimensional DSA demonstrating the fusiform aneurysm (lower).

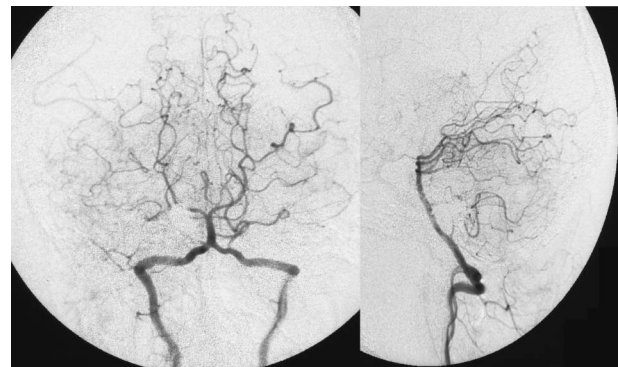


Fig. 3 Digital subtraction angiograms of the right vertebral artery showing complete embolization of the proximal anterior inferior cerebellar artery (AICA) and a dissecting aneurysm with retrograde flow of the right AICA territory through the leptomeningeal anastomosis.

lateral flow. This procedure was performed 32 days after the convulsion incident. Under both general

anesthesia (total intravenous anesthesia) and heparinization, a total of 9 TruFill DCS Detachable Coil Systems (Cordis Neurovascular, Miami, Fla., U.S.A.) were deployed in the aneurysm, and a Guglielmi detachable coil (GDC®; Boston Scientific, Natick, Mass., U.S.A.) in the right proximal AICA through a micro catheter (Excelsior; Boston Scientific) using the transfemoral approach. Complete embolization of the proximal AICA and dissecting aneurysm was successfully achieved. Right vertebral angiography showed obliteration of the aneurysm with retrograde flow of the right AICA territory through the leptomeningeal anastomosis (Fig. 3).

The patient's postoperative course was uneventful, and she was discharged from our hospital without neurological deficits. Follow-up DSA 5 months after the endovascular operation showed complete aneurysmal embolization.

Discussion

Our patient suffered only a single incident of convulsions, without prior or independent simple partial seizures. We considered that this convulsion was caused by acute brain damage. Sleep electroencephalography in the preoperative stage detected frontal intermittent rhythmic delta activity, which occurs in the presence of any irritative zone in the deep brain region such as the brainstem.¹¹⁾ However, these findings do not have any pathological implications, and the recurrence rate of such rhythmic activity is estimated to be extremely low, so we have continued to observe this patient without antiepileptic therapy. Although approximately 1 year has passed since the medical treatment of the present patient, she has had no recurrence of seizures. Therefore, we consider that it was appropriate not to administer antiepileptic drugs.

The best management for any case of dissecting aneurysm is direct surgical trapping or endovascular occlusion. However, the distal flow is dependent on only the leptomeningeal anastomosis after occlusion of the proximal AICA, and there is a risk of ischemic damage, so in principle previous bypass treatment is needed, such as OA-AICA anastomosis. Vascular surgery such as parent artery occlusion or trapping of the posterior circulation is usually safer as the collateral flow is more abundant than with trapping of the anterior circulation. Serious complications after AICA occlusion are, in fact, seldom seen, and the cortical branch may receive collateral flow from the superior cerebellar artery or PICA.^{7,10,12)} However, no reliable, quantitative evaluation methods for cerebral blood flow in the posterior circulation are currently available, and

balloon test occlusion does not provide absolute evaluation for the development of ischemic lesions after vascular trapping or occlusion.⁹⁾

In the present case, we could not achieve effective patency despite the preoperative use of OA-AICA anastomosis, because the interval from the first operation to the second might be long. We consider that the bypass flow was weaker than that of AICA itself in the context of hemodynamic mechanisms, we might have to perform aneurysmal occlusion after the bypass surgery as soon as possible. But in general interventional therapy needs enough anticoagulant status, so we performed the second operation 12 days after the first to avoid the risk of hemorrhagic complication. In fact, the case with bypass surgery plus interventional therapy for the dissecting aneurysm of posterior circulation was unusual in previous report. This consensus still remains unknown. We took the risk of performing aneurysm plus proximal AICA occlusion with detachable coils, and achieved favorable therapeutic results without ischemic complications. Abundant collateral flow was demonstrated in the posterior circulation. Therapeutic intervention without previous bypass surgery is not generally recommended, but if the bypass surgery cannot be performed for some reason, or if effective patency has not been achieved after anastomosis, either parent artery occlusion or trapping should still be considered.

References

- 1) Fujiwara K, Ito J, Kanayama S: [Multiple aneurysms of the PICA communicating artery: a case report]. *No Shinkei Geka* 27: 177-182, 1999 (Jpn, with Eng abstract)
- 2) Ikeda N, Tamura Y, Aoki A, Kuroiwa T, Sakaguchi I: [Ruptured aneurysm of the anterior inferior cerebellar artery-internal auditory artery junction: a case report]. *No Shinkei Geka Journal* 12: 31-36, 2003 (Jpn, with Eng abstract)
- 3) Kato S, Kurokawa T, Yun YS, Fujii M, Nishizaki T, Suzuki M, Sakamoto K, Kashiwagi S, Fujisawa H: [Endovascular embolization for multiple distal anterior inferior cerebellar artery aneurysm: a case report]. *No Shinkei Geka Journal* 13: 539-544, 2004 (Jpn, with Eng abstract)
- 4) Kusaka N, Maruo T, Nishiguchi M, Takayama K, Maeda Y, Ogihara K, Nakagawa M, Gotoh M, Nishiura T: [Embolization for aneurysmal dilatation associated with ruptured dissecting anterior inferior cerebellar artery aneurysm with preservation of the parent artery: case report]. *No Shinkei Geka* 34: 729-734, 2006 (Jpn, with Eng abstract)
- 5) Maekawa M, Awaya S, Fukuda S, Teramoto A: [A ruptured choroidal artery aneurysm of the anterior inferior cerebellar artery obliterated via the endovas-

- cular approach: case report]. *No Shinkei Geka* 31: 523-527, 2003 (Jpn, with Eng abstract)
- 6) Matsuyama T, Okuchi K, Norimoto K, Ueyama T: Ruptured dissecting anterior inferior cerebellar artery aneurysm: case report. *Neurol Med Chir (Tokyo)* 42: 214-216, 2002
 - 7) Nishimoto A, Fujimoto S, Tsuchimoto S, Matsumoto Y, Tabuchi K, Higashi T: Anterior inferior cerebellar artery aneurysm: report of three cases. *J Neurosurg* 59: 697-702, 1983
 - 8) Saito R, Tominaga T, Ezura M, Shimizu H, Yoshimoto T: [Distal anterior inferior cerebellar artery aneurysms: report of three cases and literature review]. *No Shinkei Geka* 29: 709-714, 2001 (Jpn, with Eng abstract)
 - 9) Seyama H, Nishida T, Yamamoto M, Mori H, Satow T, Yamada J, Nakajima N, Takahashi J, Iihara K, Muraio K, Miyamaoto S: [Therapeutic strategy for isolated dissecting aneurysms of the posterior inferior cerebellar artery: report of three cases and review of literature]. *No Shinkei Geka* 34: 1001-1006, 2006 (Jpn, with Eng abstract)
 - 10) Suzuki K, Meguro K, Wada M, Fujita K, Nose T: Embolization of a ruptured aneurysm of the distal anterior inferior cerebellar artery: case report and review of the literature. *Surg Neurol* 51: 509-512, 1999
 - 11) Van der Drift JHA, Magnus O: The EEG with space occupying intracranial lesions in old patients. *Electroencephalogr Clin Neurophysiol* 14: 664-673, 1962
 - 12) Yokoyama S, Kadota K, Asakura T, Kawazoe K: [Aneurysm of the distal anterior inferior cerebellar artery: case report]. *Neurol Med Chir (Tokyo)* 35: 587-590, 1995 (Jpn, with Eng abstract)
-
- Address reprint requests to: Shintaro Fukushima, M.D., Department of Neurosurgery, Kurume University School of Medicine, 67 Asahi-machi, Kurume, Fukuoka 830-0011, Japan.
e-mail: shitapor@med.kurume-u.ac.jp