

Progression of Pre-existing Chiari Type I Malformation Secondary to Cerebellar Hemorrhage

—Case Report—

Atsuhiko KOJIMA, Keita MAYANAGI, and Shunichi OKUI

Department of Neurosurgery, Saitama City Hospital, Saitama, Saitama

Abstract

A previously healthy 32-year-old man was surgically treated under a diagnosis of right subcortical hematoma. Magnetic resonance imaging incidentally demonstrated tonsillar herniation. Thirty-two months later, he was readmitted with complaints of occipital, neck, and shoulder pain as well as cerebellar ataxia. Subsequent magnetic resonance imaging demonstrated cerebellar hemorrhage and progression in the downward herniation of the tonsils. Conservative treatment resulted in spontaneous disappearance of the cerebellar hematoma, and the clinical signs and radiological findings improved. Patients with Chiari type I malformation require neuroimaging follow up because the downward herniation of the tonsils can progress in association with subsequent pathophysiological disorders.

Key words: cerebellar hemorrhage, Chiari malformation, subcortical hematoma

Introduction

Chiari type I malformation has long been thought to be a congenital anomaly, but intracranial pathophysiological disorders may also cause downward migration of the cerebellar tonsils, which is referred to as acquired Chiari type I malformation.³⁾ Asymptomatic Chiari type I malformation without apparent cause has also been found incidentally by magnetic resonance (MR) imaging in adults.²⁾

Here, we report an adult case of Chiari type I malformation that was incidentally demonstrated by MR imaging and subsequently deteriorated after cerebellar hemorrhage.

Case Report

A 32-year-old man, previously in excellent health, developed headache and reduced sensation to light touch in his left upper extremity. Laboratory data were within the normal limits. Computed tomography (CT) and MR imaging revealed a massive hematoma in the right parietal lobe that was not enhanced by contrast medium (Fig. 1A). MR imaging also showed downward displacement of the cerebellar tonsils (Fig. 1B). Cerebral angiography

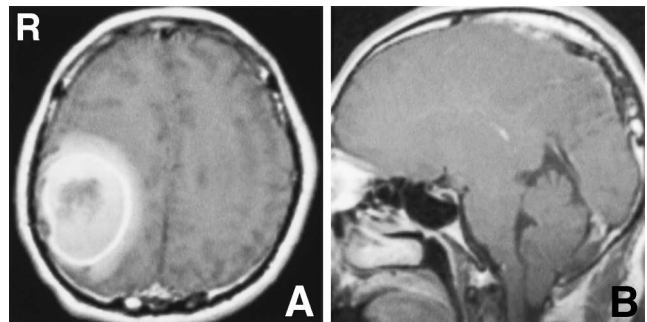


Fig. 1 A: Preoperative T₁-weighted magnetic resonance image with contrast medium showing a massive hematoma in the right parietal lobe, without enhancement. B: Sagittal T₁-weighted magnetic resonance image showing downward herniation of the tonsils.

demonstrated no abnormal findings. The hematoma was surgically evacuated the following day. All specimens obtained from the hematoma and surrounding tissues were pathologically normal. The patient was discharged 3 weeks after admission, once his headache and sensory disturbance had resolved. Follow-up MR imaging demonstrated no changes in the caudal descent of the cerebellar tonsils. Retrospectively, these MR images did not reveal

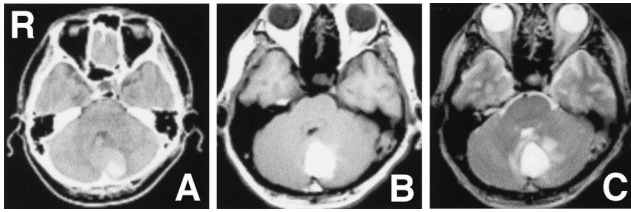


Fig. 2 Computed tomography scan (A), and T₁-weighted (B) and T₂-weighted magnetic resonance images (C) showing a subacute hematoma in the cerebellum.

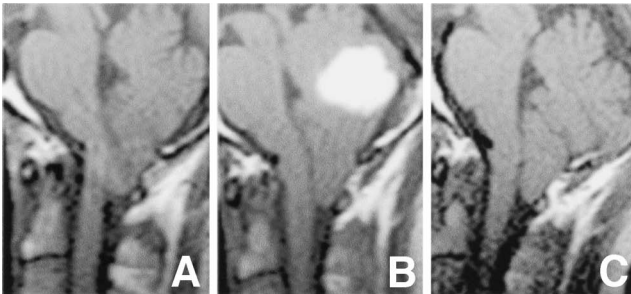


Fig. 3 Sagittal T₁-weighted magnetic resonance images, 3 weeks before the second admission (A) showing the tip of the tonsils was 16.7 mm below the foramen magnum, 10 days after admission (B) showing the downward herniation of the tonsils had progressed to 19.2 mm, and 3 months after the second admission (C) showing the cerebellar hematoma had disappeared and the tip of the tonsils was 15.3 mm below the foramen magnum.

any abnormal findings in the cerebellum.

Thirty-two months after the first admission, the patient developed occipital, neck, and right shoulder pain, and gait disturbance. CT and MR imaging revealed a hematoma in the cerebellum (Fig. 2). On admission, neurological examination demonstrated reduced sensation in the right upper extremity and mild cerebellar ataxia. Subsequent MR imaging showed progression of the downward herniation of the cerebellar tonsils, compared with the previous images (Fig. 3A, B). Spinal MR imaging showed no syrinx or spina bifida. Cerebral angiography again detected no abnormalities. With conservative management, the patient's occipital and neck pain and cerebellar ataxia became less severe. Follow-up MR imaging showed disappearance of the cerebellar hematoma and slight improvement of the tonsillar herniation (Fig. 3C). Two months after admission, the patient was discharged. He has remained clinically

and neurologically stable.

Discussion

MR imaging now allows accurate, noninvasive diagnosis of both incidental and acquired Chiari type I malformation.²⁾ Extension of the tonsils below the foramen magnum is considered normal up to 3 mm, borderline between 3 and 5 mm, and clearly pathologic exceeding 5 mm.¹⁾ In our case, the downward migration of the tonsils was already visible at the time of diagnosis of the supratentorial hematoma, which might have exerted downward pressure on the cerebellum. However, the extension of the tonsils remained at more than 5 mm below the foramen magnum even after complete disappearance of the parietal subcortical hematoma. The cerebellar tonsils usually resume a more normal position after the mass effect of hematoma has been removed.⁹⁾ Therefore, the tonsillar herniation in our patient was probably not directly associated with the supratentorial hematoma.

At the second admission, the patient complained of sudden occipital, neck, and shoulder pain, and gait disturbance. CT showed a cerebellar hematoma. Neck and shoulder pain are more commonly associated with Chiari type I malformation than with cerebellar hematoma. MR imaging after admission also showed progression of the downward herniation of the tonsils. Together, these findings strongly suggested that the cerebellar hematoma had caused downward impaction of the cerebellar tonsils into the spinal canals by intensifying the craniospinal pressure gradient.

Intracranial lesions including supratentorial brain tumors, subdural hematomas associated with traffic accidents, and arachnoid cysts in the posterior fossa can cause a craniospinal pressure gradient resulting in downward herniation of the tonsils.^{4,5,7,8)} Venous congestion and the swelling of the posterior fossa structures arising from a supratentorial arteriovenous malformation can also cause tonsillar herniation.⁶⁾ Mechanism of the deterioration of pre-existing Chiari type I malformation secondary to cerebellar hemorrhage is unknown, but the cerebellar hematoma could have displaced the tonsils in the spinal canal into a lower position in the present case.

Suboccipital craniotomy in addition to the removal of the intracranial mass or intravascular surgery usually leads to a good outcome for adults with acquired Chiari type I malformation.^{4,6-8)} On the other hand, another patient with acquired Chiari type I malformation caused by bilateral chronic subdural hematomas underwent clinicoradiographical

improvement after spontaneous disappearance of the hematomas.⁵⁾ In the present case, we chose conservative treatment rather than surgical decompression because we thought that the tonsillar herniation would improve after the disappearance of the cerebellar hematoma. As we expected, the tip of the tonsils returned to the previous position after the cerebellar hematoma disappeared. Therefore, acquired Chiari type I malformation may be managed by treatment of the primary disease or additional suboccipital craniotomy if the spontaneous resolution of the causative pathophysiology is insufficient or unanticipated. In our case, the hematomas occurred as separate lesions, and the pathological, radiological, and laboratory findings were unremarkable. We have yet to determine the definite causes of the multiple hematomas.

The present case of progression of pre-existing tonsillar herniation after bleeding in the posterior fossa indicates that patients with incidental Chiari type I malformation require neuroimaging follow up because the downward herniation of the tonsils could deteriorate in association with subsequent intracranial disorders.

References

- 1) Aboulezz A, Sartor K, Geyer CA, Godo MH: Position of cerebellar tonsils in the normal population and in patients with Chiari malformation: A quantitative approach with MR imaging. *J Comput Assist Tomogr* 9: 1033-1036, 1985
- 2) Elster AD, Chen MY: Chiari I malformations: clinical and radiologic reappraisal. *Radiology* 183: 347-353, 1992
- 3) Huang PP, Constantini S: "Acquired" Chiari I malformation. Case report. *J Neurosurg* 80: 1099-1102, 1994
- 4) Martínez-Lage JF, Almagro MJ, Ros de San Pedro J, Ruiz-Espejo A, Felipe-Murcia M: Regression of syringomyelia and tonsillar herniation after posterior fossa arachnoid cyst excision. Case report and literature review. *Neurocirugia (Astur)* 18: 227-231, 2007
- 5) Morioka T, Shono T, Nishio S, Yoshida K, Hasuo K, Fukui M: Acquired Chiari I malformation and syringomyelia associated with bilateral chronic subdural hematoma. Case report. *J Neurosurg* 83: 556-558, 1995
- 6) O'Shaughnessy BA, Bendok BR, Parkinson RJ, Shaibani A, Walker MT, Shakir E, Batjer HH: Acquired Chiari malformation Type I associated with a supratentorial arteriovenous malformation. Case report and review of the literature. *J Neurosurg* 104(1 Suppl): 28-32, 2006
- 7) Sasaki T, Tsunoda S, Morimoto T, Utsumi S: Is Chiari I malformation in the aged initiated by mechanical factors? Report of three cases. *Neurol Med Chir (Tokyo)* 30: 324-328, 1990
- 8) Takamura Y, Kawasaki T, Takahashi A, Nunomura K, Tiba K, Hasunuma M, Itou T: A craniocervical injury-induced syringomyelia caused by central canal dilation secondary to acquired tonsillar herniation. Case report. *J Neurosurg* 95(1 Suppl): 122-127, 2001
- 9) Welch K, Shillito J, Strand R, Fischer EG, Winston KR: Chiari I "malformations" — an acquired disorder? *J Neurosurg* 55: 604-609, 1981

Address reprint requests to: Atsuhiko Kojima, M.D., Department of Neurosurgery, Saitama City Hospital, 2460 Mimuro, Midori-ku, Saitama, Saitama 336-8522, Japan.
e-mail: atsuhiko.kojima@nifty.com