

## Short Communications

# Autosomal Dominant Syndrome With Strokelike Episodes and Leukoencephalopathy

Elizabeth Tournier-Lasserre, MD; Marie-Thérèse Iba-Zizen, MD;  
Norma Romero, MD; and Marie-Germaine Bousser, MD

**Background and Purpose:** We conducted a prospective survey of a family presenting a new syndrome characterized mainly by recurrent strokelike episodes and neuroimaging evidence of leukoencephalopathy.

**Summary of Report:** Forty-five members of a single family were studied clinically and with magnetic resonance imaging. Nine had strokelike episodes, including transient ischemic attacks, and minor or major strokes starting between the fourth and sixth decades, with neuroimaging evidence of small, deep infarcts and a widespread white matter disorder. Other symptoms included migraine (three), dementia (two), epilepsy (one), and hearing loss (one). In some patients, we found various immunologic anomalies and muscular lipidosis without ragged-red fibers. Eight other family members were clinically normal, but had identical neuroimaging signs of leukoencephalopathy. No abnormality was detected in the 28 other members of the family examined. Extensive investigations failed to reveal any known cause of cerebral ischemia.

**Conclusions:** There appears to be a new syndrome in this family that is characterized by recurrent subcortical strokelike episodes, leukoencephalopathy, immunologic anomalies, muscular lipidosis, and an autosomal dominant pattern of transmission. (*Stroke* 1991;22:1297-1302)

Stroke in association with the finding of leukoencephalopathy on neuroimaging has been reported in a number of nonfamilial conditions, such as Binswanger's disease, and in some rare genetic and metabolic disorders, such as metabolic encephalopathy, lactic acidosis, and stroke (MELAS) and homocystinuria.<sup>1,2</sup> We report here an autosomal dominant syndrome observed in a French family that is characterized mainly by subcortical strokelike episodes starting in midadulthood and by neuroimaging evidence of a widespread white matter disorder. The condition is associated with muscular lipidosis without ragged-red fibers and with various immunologic abnormalities of uncertain significance.

### Case Reports

Forty-five members of a family originating from the Loire-Atlantique region of France underwent extensive clinical, biological, and radiological investigation. Figure 1 shows the pedigree of this family. The

45 subjects examined belonged to generations III (18 subjects) and IV (27 subjects). All gave informed consent. Nine (six males, three females) had suffered recurrent strokelike episodes (focal cerebral deficits of sudden onset with varying degrees of recovery), which had started between 30 and 60 years of age (Table 1). These led to pseudobulbar palsy in three and dementia in two. The second most frequent symptom, present in three patients, was episodic headache suggestive of migraine. One patient developed significant psychiatric disturbance and another had sensorineural deafness. No optic nerve, spinal cord, peripheral nerve, muscle, or other organ involvement was detected. There was no ophthalmoplegia, proximal weakness, ataxia, growth failure, or symptoms during childhood. Table 1 summarizes the clinical presentation of these nine patients; only one case will be fully reported (family member III-5). Four members of generations I and II had suffered of recurrent strokes.

A 50-year-old previously healthy male was first examined in 1976 after the sudden onset of expressive dysphasia with buccofacial apraxia, from which he recovered completely within 2 months. Two other episodes of sudden onset occurred: one in 1977, again with dysphasia, and the other in 1983, with left-sided numbness involving the cheek, tongue, and first three fingers. From 1977 on the patient complained of recurrent

From Unité de Pathologie de l'Immunité, Faculté de Médecine Necker (E.T.-L.), Service de Neuro-radiologie, Hôpital des Quinze-vingts (M.-T.I.-Z.), Unité INSERM 075 and 153 (N.R.), Service de Neurologie, Hôpital Saint-Antoine (M.-G.B.), Paris, France.

Address for reprints: Pr. M.G. Bousser, Service de Neurologie, Hôpital Saint-Antoine 75571-PARIS Cédex 12, France.

Received February 20, 1991; accepted June 5, 1991.

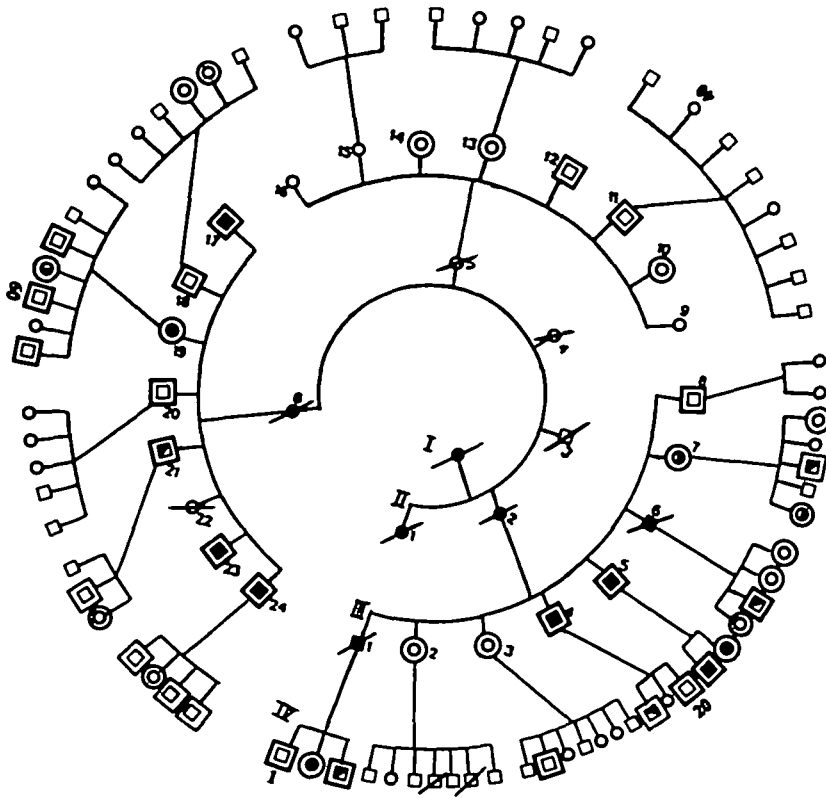


FIGURE 1. Family pedigree. Filled symbols, patients; half-filled symbols, asymptomatic subjects with abnormal magnetic resonance imaging (MRI); empty symbols, healthy individuals; bordered symbols, subjects examined clinically and with MRI; squares, male subjects; circles, female subjects; oblique slash, deceased.

attacks of severe headache with nausea, photophobia, and phonophobia. He gradually developed a typical pseudobulbar palsy, and by 1986 he was severely dysarthric and almost unable to walk. He was apathetic, depressed, and moderately demented (Mini-Mental State Examination [MMSE] score of 23/30). In view of his steady deterioration, the absence of apparent cause (infra), and the discovery of a monoclonal gammopathy without evidence of plasma cell malignancy, he underwent plasmapheresis in October 1986. After five sessions he began to improve, and after 10 sessions he was able to walk long distances without assistance and his speech had improved. The MMSE score was 27/30, and the Barthel Activities of Daily Living index had risen from 65 to 85. Since then, plasmapheresis has been performed every 1–2 months. The patient's clinical condition has remained stable, without any new further episodes. Blood pressure (130/80 mm Hg) and general examination have been normal at all times.

#### Methods

Computed tomography (CT) of the brain (CE 12 000 from CGR or Elscint 2400) was performed in the nine clinically affected subjects, using the orbitomeatal plane as reference. Brain magnetic resonance imaging (MRI) studies were performed in all 45 subjects, the first 32 at 0.15 or 0.5 T (Magniscan GE CGR) and the remainder at 1.5 T (Sigma GE-CGR). T1- and T2-weighted sequences were used in all subjects, with contiguous slices (5–9 mm thick), in sagittal and axial planes using the neuro-ocular plane as reference. Computed tomography showed small

areas of well-delineated hypodensity, without contrast enhancement, scattered throughout the basal ganglia and adjacent white matter, with a preponderance for the external capsule. Furthermore, diffuse and confluent areas of hypodensity were observed in the hemispheric white matter (leukoaraiosis). These two types of lesions were confirmed by MRI which showed, first, small, deep, and well-delineated areas of abnormal signal (decreased on T1-weighted imaging and increased on T2-weighted imaging), and secondly, on T2-weighted imaging, extensive areas of hypersignal in the white matter of the cerebral hemispheres. The small, deep, well-delineated lesions were present in all nine patients and were strikingly similar in all of them, whereas increased white matter signal, present in eight patients, was also found in eight totally asymptomatic subjects, to a variable extent (Figure 2).

The following investigations were performed in all affected individuals, except where otherwise stated, and were normal: duplex scanning of cervical arteries, four-vessel angiography (performed in four patients), electrocardiography, two-dimensional echocardiography, Holter monitoring, chest x-ray, nerve-conduction velocities (performed in three patients), lipid metabolism [total, LDL, and HDL cholesterol; triglycerides; apolipoprotein A-I; Lp(a)], detailed coagulation and hemostasis studies, serum creatine kinase enzymes, hexosaminidases A and B, arylsulfatases A and B, and  $\alpha$ -galactosidase. Free and total serum carnitine levels, blood lactates, and pyruvates at rest and after exercise were normal except in patient III-23, where, twice,

TABLE 1. Clinical Presentation of the Nine Patients in Generations III and IV

Propositus (age of onset)	Vascular risk factors	Main clinical features
III-4 (56)	Hypertension Myocardial infarction	Two sudden episodes of left hemiplegia (1980, 1988) with poor recovery. Pseudobulbar palsy and subcortical dementia.
III-5 (50)	None	Two sudden episodes of dysphasia (1976, 1977) and one (1983) of left face and arm numbness. Severe pseudobulbar palsy. Migraine without aura. IgG- $\lambda$ benign monoclonal gammopathy. Improvement with plasmapheresis.
III-17 (54)	None	Three episodes of sudden onset with good recovery in 1 week to 1 month (1983, pure left hemiplegia; 1984, dysphasia; 1985, left hemiplegia and loss of balance).
III-19 (40)	Increased cholesterol	From 1971 on, grand mal seizures and status epilepticus. Three sudden and poorly regressive episodes (1983, right sensory motor deficit and dysarthria; 1986, pure left sensory deficit; 1988, severe right hemiplegia), pseudobulbar palsy, subcortical dementia, psychiatric disturbance (depressions 1984, 1988), manic episode (1985). No response to plasmapheresis.
III-23 (47)	None	Multiple 5- to 15-minute episodes of paresthesia in left hand and face followed by left-sided headache lasting <1 hour (migraine with aura or transient ischemic attacks).
III-24 (42)	None	Multiple transient episodes (30–60 minutes) of two types: left arm and face weakness and paresthesia, and bilateral blurring of vision without headache.
IV-2 (39)	Cigarette smoker	One sudden episode of dysarthria and left-sided facial weakness lasting 1 month.
IV-21 (34)	None	One sudden episode of expressive dysphasia lasting 5 days.
IV-22 (33)	Cigarette smoker	Multiple episodes (3–24 hours) of dysphasia with or without visual field defects. One sudden episode of pure hemiplegia lasting 1 month. Migraine with and without aura. Bilateral sensorineural hearing loss.

lactate levels at rest were observed to be  $>2$  mM/l (i.e., 3 mM/l and 3.2 mM/l). Total plasma homocysteine level was measured in three cases and found to be increased in one (patient IV-22, 21  $\mu$ mol/l).

The cerebrospinal fluid was analyzed in five patients: it was normal in two (III-17, 19), showed an increase in protein (0.94 g/l) with an IgG monoclonal  $\lambda$  peak in one (III-5), a mild pleocytosis (8 cells/mm<sup>3</sup>) in one (IV-2), and oligoclonal bands in two (IV-2, 22).

Extensive immunologic investigations (screening for antibodies to DNA, nuclear soluble proteins, mitochondria, striated muscle, smooth muscle, thyroid, and skin; blood lymphocyte subpopulation analysis using monoclonal antibodies directed toward CD3, CD4, CD8, T-cell antigens, and B-cell and natural killer cell antigens) were performed because patient III-6 had died of myeloma (IgG- $\kappa$ ) and his brother, III-5, had a benign monoclonal gammopathy. Antibodies were detected in the serum of some patients: antinuclear antibodies (immunofluorescence, titers 1/100–1/400) in three (III-5, 19, IV-22) and antibodies directed toward skin or striated muscle in two (III-17, 21).

Biopsies were obtained from the left deltoid of four patients (IV-4, 5, 19, IV-22) and one asymptomatic subject (III-21) with leukoencephalopathy for histochemical and electron microscopic studies.<sup>3</sup> In two patients (III-5, 19), mitochondria were isolated from 1 g fresh muscle and the analysis of their functions performed.<sup>4</sup> Whereas muscle biopsy was

normal in the asymptomatic subject, a similar abnormal histochemical pattern was observed in the patients: type I fiber predominance (51–65%), type II fiber atrophy, and accumulation of sudanophilic lipids within muscle fibers (Figure 3). Neither glycogen accumulation nor ragged-red fibers were seen. Electron microscopy revealed numerous large lipid droplets in the intermyofibrillary spaces. The morphology and number of mitochondria were normal. Free muscle carnitine values were normal in three cases, but the esterified/total carnitine ratio was increased in two subjects: (III-5, 46.5%; III-21, 54.4%; controls, <33%). Muscle mitochondria displayed normal electron transport and energy coupling. The respiratory chain, as well as  $\beta$ -oxidation, Krebs cycle, pyruvate dehydrogenase, and transmembrane transport of ADP, phosphate, and ATP, was functionally intact.

### Discussion

The genealogical study of this family shows that six males and three females were clinically affected and that five males and three females were clinically asymptomatic, but had MRI white matter hyperintensity signals on T2-weighted imaging. The disease is transmitted either paternally or maternally and affects approximately 50% of offspring. The offspring of unaffected parents are also unaffected. This pattern is consistent with an autosomal dominant pattern of inheritance.

All clinically affected subjects presented with episodes of focal brain deficits of sudden onset. The

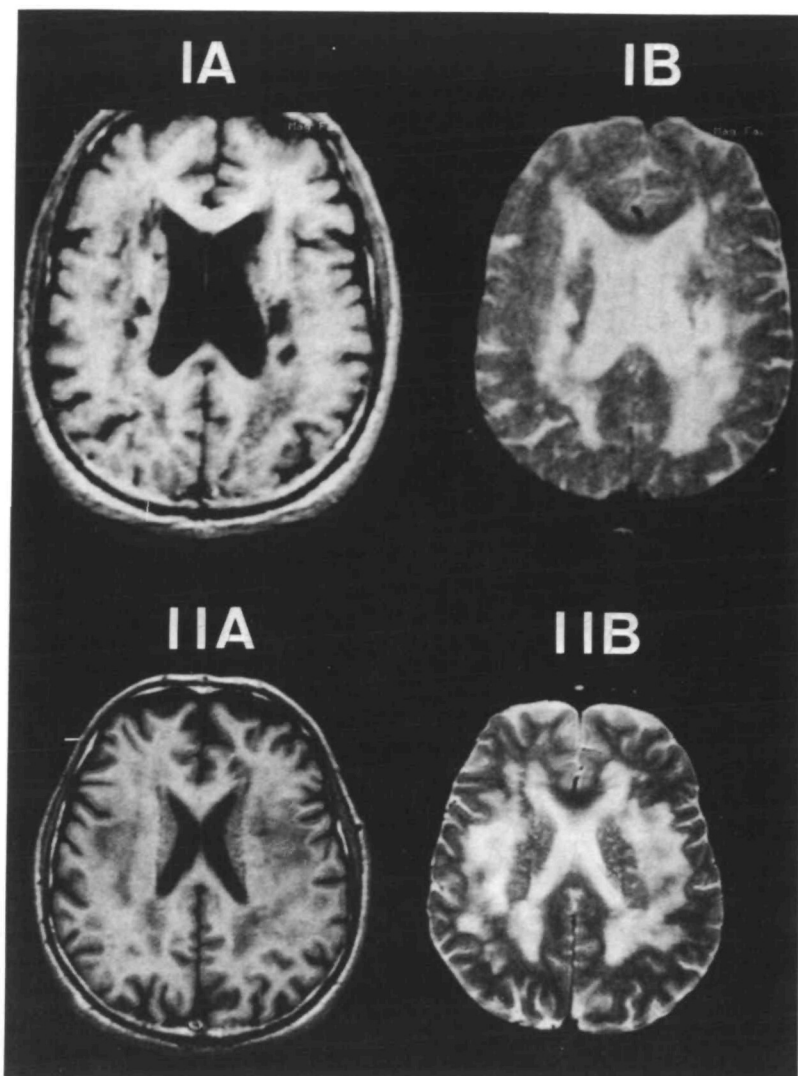


FIGURE 2. Panels IA and B: Magnetic resonance imaging (MRI) scan of patient III-5. T1-weighted imaging: numerous low-signal subcortical lesions (left and right thalami, posterior limb of left internal capsule, right external capsule, and left temporo-occipital white matter). T2-weighted imaging: corresponding areas of high signal with a more diffuse white matter increased signal. Panels IIA and B: MRI scan of family member III-21. T1-weighted imaging: Signal return from white matter is abnormal but no focal areas are seen. T2-weighted imaging: Diffuse high-signal intensity of the subcortical white matter.

time course was highly variable, being that of complete resolution within a few minutes to minimal recovery with various degrees of sequelae. In all but two patients recurrences occurred over the years, leading to pseudobulbar palsy in three and to severe dementia of the subcortical type in two. Such a clinical profile is highly suggestive of an ischemic process, but, in the absence of pathologic data, the term "stroke-like episodes" has been used in the present description. Computed tomography and MRI showed small, well-delineated lesions compatible with, though not diagnostic of, small, deep infarcts, which seem, remarkably, to spare the cortex. The other principal feature of the condition is a white matter disorder, as shown by leukoaraiosis on CT scan and increased signal return on T2-weighted imaging on MRI. Such a leukoencephalopathy has been described in numerous disorders and its significance is still debated; its frequency increases with age, systemic hypertension, other vascular risk factors, and in patients presenting with stroke or dementia.<sup>5</sup> In the present family, it is remarkable in that it is also observed in some young, symptom-free family

members having either an affected parent or a parent with the same subclinical white matter disorder.

Extensive cardiovascular investigations helped to rule out the majority of classic causes of cerebral ischemia such as atheroma, cardiac emboli, or hematologic disorders. The association of multiple subcortical strokes and white matter disease is suggestive of Binswanger's disease<sup>6</sup> and can also be observed in lacunar syndromes.<sup>7</sup> However, the present disorder differs from these in its earlier onset, low rate of hypertension (1 of 9), and autosomal dominant pattern of inheritance. Among the familial conditions that can cause stroke, hereditary dyslipoproteinemias,<sup>8</sup> thrombotic disorders,<sup>9</sup> homocystinuria,<sup>10</sup> and Fabry's disease<sup>11</sup> have distinct clinical presentations and were ruled out by appropriate investigations. Familial cerebral amyloid angiopathy<sup>12</sup> cannot be formally excluded without brain histology, but the absence of cerebral hemorrhage in this family made it unlikely. Stroke-like episodes, white-matter disease, and muscular lipidosis are features of MELAS syndrome.<sup>2</sup> However, the absence of ragged-red fibers, the normality of muscular mitochondrial respiratory

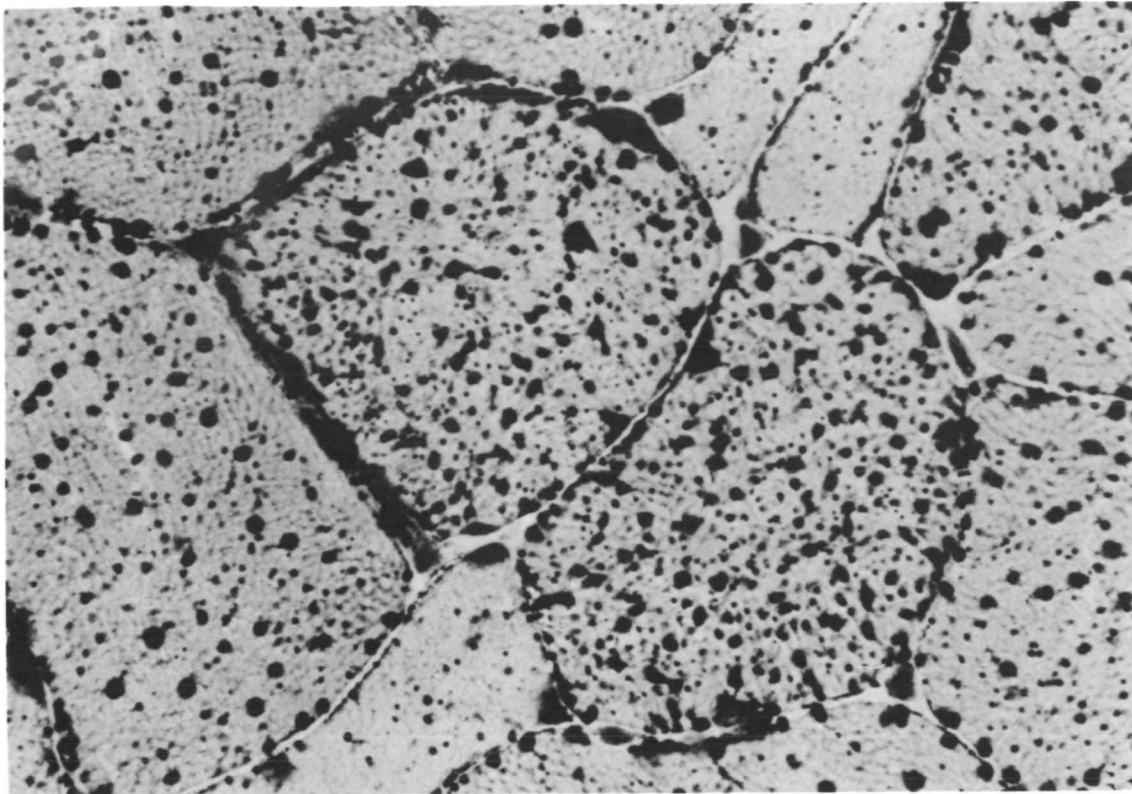


FIGURE 3. Muscle biopsy from patient III-19 showing marked accumulation of lipids in type I muscle fibers. Sudan red stain.

chain and  $\beta$ -oxidation investigations, and the absence of a number of the usual clinical features of MELAS (onset during childhood, mental retardation, cortical infarcts) do not favor this diagnosis. Three other families<sup>13-15</sup> with autosomal dominant recurrent strokes have been reported, but in the absence of MRI and muscle biopsies, it is impossible to know whether they suffer from the same condition.

Thus, in the present family, there appears to be a new autosomal dominant syndrome characterized by recurrent subcortical stroke-like episodes, leukoencephalopathy, and muscular lipidosis. It is interesting to note that the familial nature of this condition was long ignored, mainly because of the relatively late age of onset of symptoms. It might well be that its real frequency is presently underestimated. The cause of this disease, the responsible genetic defect, the role of the abnormal immune status, and the pathogenesis of the stroke-like episodes remain to be elucidated.

*Note added in proof.* Patient III-19 died on December 12, 1990. Macroscopic examination of the brain showed a recent massive striate hemorrhage on the left side. The remaining white matter on both sides looked greyish and granular with multiple small lacunes. Detailed neuropathologic data will be presented in a second paper to be submitted for publication in this journal.

#### Acknowledgments

We are greatly indebted to Association pour la Recherche sur la Sclérose en Plaques (ARSEP) for making the MRI studies possible.

We are grateful to all the residents and physicians who helped us, particularly to Drs. A. Abanou, R. Aylward, M.A. Bach, N. Baumann, J. Breton-Gorius, M. Chaussain, F. Danon, D. Dormont, M. Jouas, C. Marsac, J. Tamraz, and A. Tourbah, and to Prs. J.R. Feve, J.C. Homberg, A. Munich, J. Pouget, S. Richard, and M. Samama. We are indebted to Mrs. Jocelyne Ruffie and Nadia Kneisky for their assistance in the preparation of the manuscript and to Dr. B. Youl for helping with the English. We would also like to thank most warmly all the members of the family for their remarkable collaborative support.

#### References

1. Natowicz M, Kelley R: Mendelian etiologies of stroke. *Ann Neurol* 1987;22:175-192
2. Pavlakis SG, Philipps PC, Di Mauro S, De vivo DC, Rowland LP: Mitochondrial myopathy, encephalopathy, lactic acidosis, and stroke-like episodes: A distinctive clinical syndrome. *Ann Neurol* 1984;16:481-488
3. Dubowitz V: *Muscle Biopsy: A Practical Approach*. London, Bailliere-Tindall, 1985, pp 3-20
4. Morgan-Hughes JA, Darveniza P, Kanh SN, Landon DN, Sheratt RM, Land JM, Clark JB: A mitochondrial myopathy characterized by a deficiency in reductible cytochrome b. *Brain* 1977;100:617-640
5. George AE, Deleon MJ, Kalnin A, Rosner L, Goodgold A, Chase N: Leukoencephalopathy in normal and pathologic aging. *Am J Neuroradiol* 1986;7:561-570
6. Babikian V, Ropper AH: Binswanger's disease: A review. *Stroke* 1987;18:2-12
7. Weisberg LA: Diagnostic classification of stroke, especially lacunes (editorial). *Stroke* 1988;19:1071-1073
8. Zannis VI, Breslow JL: Genetic mutations affecting human lipoprotein metabolism, in Harris H, Hirschhorn K (eds):

- Advances in Human Genetics, Volume 14.* New York, Plenum Publishing Corp, 1985, pp 125–135
9. Rodgers GM, Shuman MA: Congenital thrombotic disorders. *Am J Hematol* 1986;21:419–430
  10. Mudd SH, Levy HL, Skovby F: Disorders of transsulfuration, in Scriver C, Beaudet AL, Sly WS, Valle D (eds): *The Metabolic Basis of Inherited Disease*, ed 6. New York, McGraw-Hill Book Co, 1989, vol 1, pp 693–734
  11. Desnick RJ, Sweeley CC: Fabry's disease: Alpha galactosidase A deficiency, in Stanbury JB, Wyngaarden JB, Frederickson DS, Goldstein JL, Brown MS (eds): *The Metabolic Basis of Inherited Diseases*, ed 5. New York, McGraw-Hill Book Co, 1983, pp 906–944
  12. Haan J, Roos RAC, Algra PR, Lanser JBK, Bots GTAM, Vegter-Vandervliet M: Hereditary cerebral haemorrhage with amyloidosis-Dutch type: Magnetic resonance imaging findings in 7 cases. *Brain* 1990;113:1251–1267
  13. Stevens DL, Hewlett RH, Brownell B: Chronic familial vascular encephalopathy. *Lancet* 1977;2:1364–1365
  14. Sonninen V, Savontaus ML: Hereditary multi-infarct dementia. *Eur Neurol* 1987;27:209–215
  15. Sourander P, Walinder J: Hereditary multi-infarct dementia. *Acta Neuropathol (Berl)* 1977;39:247–254

---

KEY WORDS • dementia, vascular • leukoencephalopathy • migraine