

Memory loss due to transient hypoperfusion in the medial temporal lobes including hippocampus

Tanabe H, Hashikawa K, Nakagawa Y, Ikeda M, Yamamoto H, Harada K, Tsumoto T, Nishimura T, Shiraishi J, Kimura K. Memory loss due to transient hypoperfusion in the medial temporal lobes including hippocampus
Acta Neurol Scand 1991; 84: 22–27.

A typical case of transient global amnesia (TGA) was investigated with single photon emission computed tomography (SPECT) and magnetic resonance imaging (MRI) with 1.5-tesla scans. During the amnesic episode, a marked decrease of cerebral blood flow was observed in the areas confined to the territory of the bilateral posterior cerebral arteries including the hippocampus. After the episode, cerebral blood flow returned to normal and a circumscribed lesion was detected in the middle portion of CA 1 field of the left hippocampus. The SPECT findings prove direct evidence that the medial temporal structures are involved in the establishment of new memories, as well as in process of recalling only recently acquired memories, but not in retrieval of memories acquired long ago. The MRI findings indicate that a unilateral partial damage to CA 1 sector of the hippocampus does not develop a definite memory impairment and that high-resolution MRI study on the hippocampus is necessary in TGA patients.

H. Tanabe^{1,3}, K. Hashikawa²,
Y. Nakagawa³, M. Ikeda¹, H. Yamamoto¹,
K. Harada⁴, T. Tsumoto⁵,
T. Nishimura¹, J. Shiraishi³, K. Kimura²

Departments of ¹ Neuropsychiatry, ⁴ Radiology,
² Nuclear Medicine, ⁵ Neurophysiology,
Biochemical Research Center, Osaka University
Medical School, ³ Faculty of Health and
Sport Sciences, Osaka University, Japan

Key words: transient global amnesia; medial temporal lobe; cerebral blood flow; single photon emission computed tomography; hippocampus; magnetic resonance imaging; memory

Hirotsuka Tanabe, Department of
Neuropsychiatry, Osaka University Medical
School, Fukushima, Osaka 553, Japan

Accepted for publication December 6, 1990

Memory is suspected to be processed in certain localized areas of the brain. Particularly, the medial temporal lobe including the hippocampus is considered to be a critical structure for formation of memory (1). Transient global amnesia (2) is a well-recognized clinical entity characterized by a severe, but transient, inability to form new memories without other higher nervous dysfunctions (3). After the amnesic episode, patients recover completely so as to tell examiners what happened to them, this being different from the reported cases (4), who have permanent memory impairment due to irreversible brain damage. In addition, "control tests" are possible in TGA patients, since we can give them the same memory tests during and after the episode. Thus, visualization of impaired or inactive sites during an episode of TGA may give a unique opportunity to localize the sites responsible for the memory-related processes in the human brain. However, the attack takes place unexpectedly and fades quickly so that it is a rare chance to carry out computer-assisted imaging of the brain using radioactive substrates during the episode. In fact, there have been no full reports which performed such imaging techniques during the episode, while there exist some reports which performed comprehensive neuropsychological evaluation during the episode (5–10). Here we

report an observation of a TGA patient with single photon emission computed tomography (SPECT) scans during and after an amnesic episode.

Case report

The patient is a 63-year-old, right-handed woman without vascular risk factors expect for labile hypertension. Her past history has been otherwise unremarkable. For a few days before the attack of TGA, she had been fatigued due to overwork resulting in a dull headache. Her episode of TGA is reported as follows: On the morning of February 8 around 7 AM, 1989, she became suddenly perplexed and repeatedly asked her son the same questions over and over despite repeated explanations. For example, she asked him where her husband was, evidently not remembering that he had been hospitalized with a fracture of his foot one month before. Her speech and behaviour were otherwise normal. At that point, her son, who is a medical doctor, took her immediately to our hospital. On the way to our hospital by car, she repeatedly demanded where they were going, despite the fact that she was always given the same reply. At 10 AM, clinical examination was performed. General and neurological examinations were normal except for her blood pressure of 170/

100 mmHg. The patient was disoriented in time but not space and person. She showed complete inability to form any new memories, but no confabulation was noted. For instance, she could readily name three objects, but could recall none of the objects after distraction or a delay of a couple of minutes. Moreover, she could not remember even the fact that she had seen them. Thus, the patient could not recall nor recognize the events which she had just experienced. In contrast to such severely impaired recent memory, she gave a good account of events from the remote past at least several years before the attack. Also, her immediate memory was preserved: digit spans were seven forward and five backward. She could execute serial subtractions of the digit "7" rapidly and flawlessly, and could abstract proverbs satisfactorily. Social interaction and affective behaviour were also normal. Except for memory, all other clinically evaluated higher cortical functions were normal.

The acute phase lasted until 11:30 AM, when she felt as if she had awoken and she began to partially remember events as they were occurring. At this point, she was concerned about what had happened during the past four and a half hours and could successfully perform the three object recalling test. However, the tasks such as story recall and paired associate learning still disclosed a definite impairment of recent memory; these tasks were normally performed when she was re-tested one week later (Index scores of the Wechsler Memory Scale-Revised (11), performed several months afterwards, were normal: Attention-Concentration, 117; Verbal Memory; 110; Visual Memory, 116; General Memory, 112; and Delayed Memory, 108). Thus the severe anterograde amnesia began to regress at 11:30 AM and her memory function appeared totally recovered at 3 PM about eight hours after the onset of TGA. Her memory for the events which occurred from 11:30 AM to 3 PM was patchy and vague. She recovered completely from the retrograde amnesia, which had covered at least 10 months with fragments of memory during the acute phase; she could recall all of the events which had happened previous to retiring for the night before. At 4 PM, she went to her husband's office and finished her work as usual.

A computed tomographic (CT) scan, performed at 11:15 AM during the episode, revealed no abnormalities. Electroencephalogram (EEG) and external cerebrovascular Doppler ultrasound examinations, carried out one week later, were normal. SPECT using N-isopropyl(¹²³I)-P-iodoamphetamine (IMP-SPECT) scans (12) were performed both during and after the TGA episode (Fig. 1 and Table 1). During the episode, a marked decrease of cerebral blood flow was observed in the areas confined to the

Table 1. I-123 IMP distribution in the brain during & after TGA attack

		After					
		During		1 week		5 month	
		54		53		56	
Whole brain		rt	lt	rt	lt	rt	lt
Slice 1	Cerebellum	84	85	82	79	73	80
Slice 2	Temporal						
	Medial	47	45	59	61	67	71
	Lateral	61	64	62	60	75	73
Slice 3	Thalamus	88	85	74	80	81	79
	Frontal	65	69	70	73	76	74
	Occipital	68	63	74	71	77	73
	Temporal (lateral)	71	70	67	66	75	74

(average counts/voxel/administration dose (mCi))

For quantitative analysis, 12 mm thick 3 slices were made by summation of original 4 mm thick consecutive 3 slices, respectively. Slice 1 corresponds to the level of the cerebellum, slice 2 that of the midbrain, and slice 3 that of the basal ganglia. Fourteen symmetrical regions of interest (16 mm X 16 mm) were analyzed, 2 in the slice 1 for the cerebellar hemisphere, 4 in the slice 2 for the lateral and medial portions of the temporal lobe, and 8 in the slice 3 for the frontal lobe, lateral portion of the temporal lobe, the occipital lobe and the thalamus. The average counts for 4 mm cubic voxel were calculated for each region of interest. For the correction of the small difference of I-123 IMP administration doses, each value was divided by administration dose (mCi).

territory of the bilateral posterior cerebral arteries including the hippocampal formation (arrows in the left column of Fig. 1). After the episode, this abnormal finding disappeared and cerebral blood flow (CBF) returned to normal (An IMP-SPECT scan, performed 5 months later, showed almost the same flow distribution images as just after TGA). Thus, we demonstrated that a transient reduction of flow in the both medial temporal lobes including the hippocampal formation took place during an episode of TGA.

A magnetic resonance imaging (MRI) with 1.5 T scan, carried out one month after the TGA attack, disclosed a circumscribed lesion in the left hippocampus which could not be detected by CT scan (Fig. 2). The brain were cut in 5 mm-thick horizontal and coronal sections. The lesion was observed on only one horizontal and coronal slice. By reference to detailed atlases of the hippocampus (13-15), the lesion was found to be situated in the approximately middle portion of the CA 1 field.

Discussion

TGA occurs in subjects of both sexes, mainly among those aged 50 years or more, and the amnesic episode is characterized as follows (16, 17). Patients suffer sudden anterograde and retrograde memory loss without other neurological signs or symptoms.

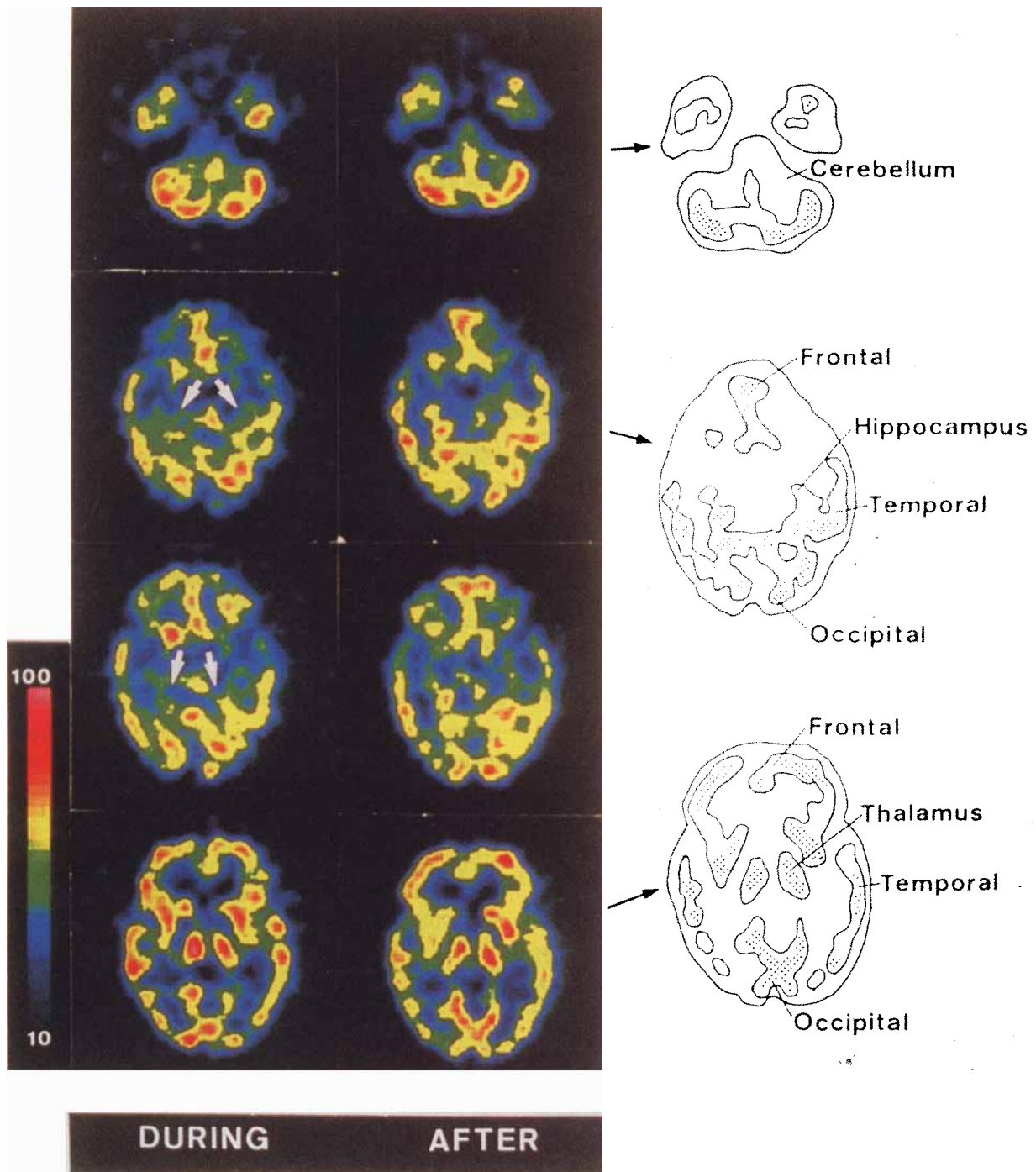


Fig. 1. SPECT using N-isopropyl(¹²³I)-p-iodoamphetamine (IMP-SPECT) during and after the episode of TGA. The images taken during the episode are shown on the left, those taken one week after the attack on the middle and schematic diagrams of three after-TGA images on the right. Data acquisitions were carried out with a newly developed 4-head rotating gamma camera SPECT with a low energy high resolution collimator (12). The spatial resolution was 9.8 mm in full width at half at center. Data acquisition were started 10 min. after the intravenous injection of about 6 mCi I-123 IMP and continued for 35 min. The raw data were reconstructed using a standard filtered-back projection algorithm with a pre-treatment by Wiener filter. The attenuation correction were performed by correction method. Using the set of 2 light projectors for position setting, we could obtain almost the same anatomical slices for two studies. The images shown here were selected from 42 sequential slices at 4 mm pitch. All images were displayed with same colour scale. In the images, pink corresponds to the highest level of cerebral blood flow and blue to the lower level. Compared with the afer-TGA images, the images taken at 1 PM during the episode demonstrate a marked hypoperfusion confined to the territory of the posterior cerebral arteries with preserved blood flow in other areas including the frontal cortex and thalamus. White arrows indicate areas with reduced blood flow. The images of the second row approximately correspond to the level of the horizontal slice of MRI (see Fig. 2). Note the location of the medial temporal lobes including the hippocampus.

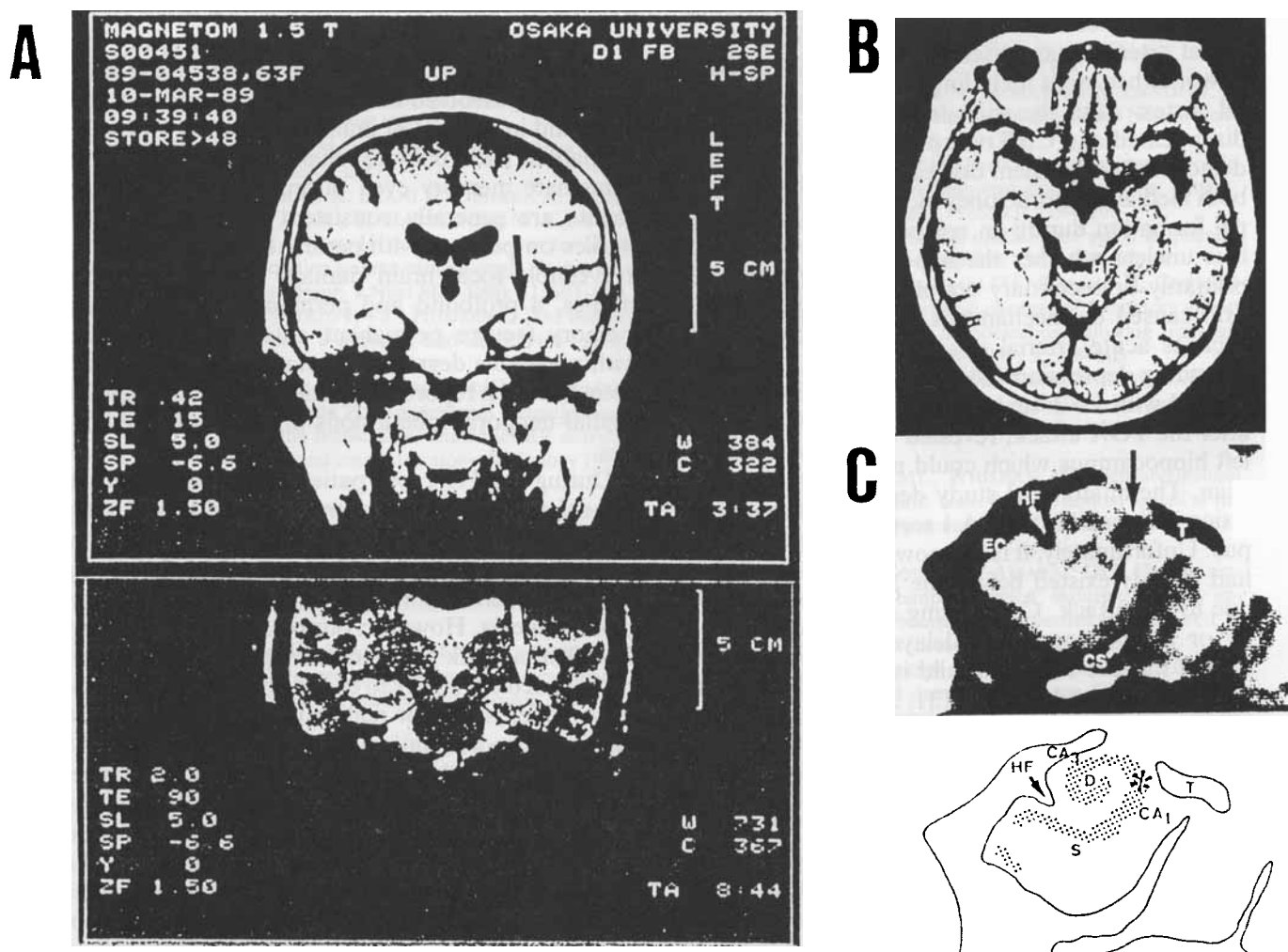


Fig. 2. MRI with 1.5 T scans, carried out one month after the TGA attack, showing a small circumscribed lesion in the left hippocampus. (A) Top: T1-weighted coronal image (TR/TE: 420/50). Bottom: T2-weighted coronal image (TR/TE: 2000/90). Arrows indicate lesions. The rectangle outlines the region shown at magnification in C. (B) T1-weighted horizontal image (TR/TE: 420/50). The level of this image approximately corresponds to the SPECT images of the second row of Fig. 1. Black arrow indicates the lesion and white arrow the hippocampal fissure (HF). (C) Top: close view of the left hippocampus. Bottom: the corresponding diagram. Big black arrows indicate the lesion in the CA 1 field and asterisk represents it. CS, collateral sulcus; EC, entorhinal cortex; T, temporal horn of the lateral ventricle; S, subiculum; D, dentate gyrus; CA1, Field CA 1 of the hippocampus; CA 3, Field CA 3 of the hippocampus.

They retain personal identity and are able to carry on normal activities. However, since the patients are unable to acquire new information, they ask repeated questions about their immediate environment and situation. The retrograde memory loss, extending back for days, months or in some cases even years before the attack, gradually or quickly shrinks as the patients recover. No or only a brief period of permanent retrograde amnesia persists, but memory for events during the acute phase is permanently impaired. The amnesic episodes generally last several hours. Thus, our patient exhibited the typical features of TGA.

TGA is not a rare illness, but the etiology is not known yet (18). The two theories proposed most often are cardiovascular and epileptic causes. The

latter is, however, supported by few authors (19) and two recent studies prove strong evidence against the epileptic etiology. In the first, EEG being recorded at onset of TGA showed no epileptic discharge (20). In the second, EEG from scalp and sphenoidal electrodes during TGA revealed no electrophysiologic dysfunction (21). On the other hand, there have been no reports as yet which proved the former, cerebrovascular etiology, although most authors think that the amnesic episode is caused by transient ischemia affecting the both medial temporal lobes, in particular, the bilateral hippocampal formations (16, 18, 22-25).

In the present study, we performed IMP-SPECT scannings in a typical case of TGA during and after an episode. During the episode, a marked hypoper-

fusion confined to the territory of the posterior cerebral arteries was observed with preserved blood flow in other areas including the thalamus and frontal cortex. After the episode, this abnormal finding disappeared and CBF returned to normal. Thus, we demonstrated transient decrease of blood flow in the both medial temporal lobes including the hippocampal formation during an episode of TGA, although it is unclear whether the hypoperfusion developed primarily or secondary coupled with hypometabolism caused by mechanisms not as yet elucidated, such as acute arterial dyscontrol (17) and Leao's spreading depression (26).

MRI with 1.5 T scanings, performed one month after the TGA attack, revealed a focal lesion in the left hippocampus which could not be shown by CT scan. The anatomical study demonstrated that the lesion is situated in the CA 1 sector of the hippocampus. Unfortunately, it is unknown whether the lesion had already existed before the attack or developed due to the attack. Considering selective vulnerability or the phenomenon "delayed neuronal death" (27) of the CA 1 field to mild ischemia in both animals (28–30) and humans (31, 32), the latter possibility seems to be more probable. It is, however, unclear why the lesion developed only on the left side. In any case, the MRI finding of our patient indicates the necessity of high-resolution MRI study on the hippocampus of TGA patients.

How could our patient have an MRI-verified lesion and no CBF-change after TGA? Usually, a lesion has abnormal low flow. We think that it is a matter of high resolution MRI as compared to lower resolution SPECT (partial volume or compton scatter effect?).

In humans, there is only one case of amnesia following a lesion limited to the hippocampus (31). This amnesic patient R.B. had an ischemic injury that resulted in a bilateral lesion limited to the entire field CA 1 of the hippocampus. The anterograde amnesia of R.B. was permanent, whilst that of our patient was transient. Hence, it appears that a unilateral partial damage to the CA1 sector does not produce permanent disability to lay down new information. From a different viewpoint, R.B.'s recent memory impairment is not so severe as those of our patient and the celebrated patient H.M., in both of whom the bilateral temporal lobes are affected, although transiently in our patient. Consequently, as pointed out by Kritchevsky et al. (9) and demonstrated by the present SPECT study, the area of dysfunction in TGA must involve at least more than just the bilateral CA 1 region of the hippocampus.

The present results indicate that the medial temporal structures including the hippocampus play an essential role in the formation of new memories, because the patient had no memory traces of events

which had happened during the attack when an hypoperfusion was observed in those structures. Also, the results suggest that these structures in the brain may not be involved in retrieval of remote past memory and in process of immediate memory, because the patient had ability to recall the remote past and immediate memory even during the attack. These results are generally consistent with the previous studies on patients with permanent amnesia due to irreversible focal brain damage (33–37). In these studies, a profound and permanent loss of recent memory (severe permanent anterograde amnesia) with a variable degree of permanent retrograde amnesia has been reported in patients who had bilateral medial temporal lobe lesions due to various etiologies.

During the TGA, our patient appeared perplexed and asked series of questions repeatedly as if to try to orient herself, but she did not definitely realize her inability to acquire new information, like the above-mentioned patients with severe permanent anterograde amnesia. However, our patient spontaneously described a blank in her memory precisely after having regained the ability to encode new memory, while these patients cannot realize their memory blanks. Moreover, in our patient, disappearance of the hypoperfusion in the medial temporal lobes corresponded to resolution of the amnesia. Hence, the present study directly supports the hypothesis that the medial temporal structures are involved in the establishment of new memory as well as in process of recalling only recently acquired memories, but not in retrieval of memories acquired long ago.

Acknowledgements

We thank Dr. D. G. Amaral for his helpful advice.

References

1. SQUIRE LR. Memory and brain. New York; Oxford University Press, 1987.
2. FISHER CM, ADAMS RD. Transient global amnesia. *Acta Neurol Scand* 1964; (Suppl 9): 1–83.
3. CAPLAN LR. Transient global amnesia: criteria and classification. *Neurology* 1986; 36: 441.
4. MILNER B, CORKIN S, TEUBER HL. Further analysis of the hippocampal amnesic syndrome: 14-year follow-up study of H.M. *Neuropsychologia* 1968; 6: 215–234.
5. REGARD M, LANDIS T. Transient global amnesia: neuropsychological dysfunction during attack and recovery in two "pure" cases. *J Neuro Neurosurg Psychiatry* 1984; 47: 668–672.
6. GALLASSI R, LORUSSOS, STRACCIARI A. Neuropsychological findings during a transient global amnesia attack and its following. *Ital J Neurol Sci* 1986; 7: 45–49.
7. STRACCIARI A, REBUCCI GG, GALLASSI R. Transient global amnesia: neuropsychological study of a "pure" case. *J Neurol* 1987; 234: 126–127.
8. KRITCHEVSKY M, SQUIRE LR, ZOUZOUNIS JA. Transient global amnesia: characterization of anterograde and retrograde amnesia. *Neurology* 1988; 38: 213–219.

9. KRICHEVSKY M, SQUIRE LR. Transient global amnesia: evidence for extensive, temporally graded retrograde amnesia. *Neurology* 1989; 39: 213–218.
10. HODGES JR, WARD CD. Observations during transient global amnesia: a behavioural and neuropsychological study of five cases. *Brain* 1989; 112: 595–620.
11. WECHSLER D. Wechsler Memory Scale-Revised. New York: Psychological Corporation, 1987.
12. KIMURA K, HASHIKAWA K, ETANI H, UEHARA A, MORIWAKI H, KOZUKA T, ISAKA Y, MATSUMOTO M, KAMADA T, MORINAGA H, TABUCHI H. A new apparatus for brain imaging: four-head rotating gamma camera single photon emission computed tomograph. *J Nucl Med* 1990; 31: 603–609.
13. NIEUWENHUYNS R, VOOGD J, VAN HUIJZEN C. The human central nervous system: a synopsis and atlas. New York: Springer-Verlag, 1978.
14. NAIDICH TP, DANIELS DL, HAUGHTON VM, WILLIAMS A, POJUNAS K, PALACIOS E. Hippocampal formation and related structures of the limbic lobe: anatomic-MR correlation. I. Surface features and coronal sections. *Radiology* 1987; 162: 747–754.
15. AMARAL DG. Memory: anatomical organization of candidate brain regions. In: PLUM F ed. *Handbook of physiology* (vol. 5). Bethesda MD: American Physiological Society, 1987.
16. ROWAN AJ, PROTASS LM. Transient global amnesia: and electroencephalographic findings in 10 cases. *Neurology* 1979; 29: 869–872.
17. HINGE HH, JENSEN TS, KJAER M, MARQUARDSEN J, DE FINE OLIVARIUS B. The prognosis of transient global amnesia: results of a multicenter study. *Arch Neurol* 1986; 43: 673–676.
18. CAPLAN LR. Transient global amnesia. In: FREDERIKS JAM ed. *Handbook of Clinical Neurology* (vol. 45). Amsterdam: Elsevier, 1985: 205–218.
19. FISHER CM. Transient global amnesia: precipitating activities and other observations. *Arch Neurol* 1982; 39: 605–608.
20. COLE AJ, GLOOR P, KAPLAN R. Transient global amnesia: the electroencephalogram at onset. *Ann Neurol* 1987; 39: 605–608.
21. MEADOR KJ, LORING DW, KING DW, NICHOLS FT. The P3 evoked potential and transient global amnesia. *Arch Neurol* 1988; 45: 465–467.
22. LOGAN M, SHERMAN DG. Transient global amnesia. *Stroke* 1983; 14: 1005–1007.
23. COLOMBO A, SCARPA M. Transient global amnesia: pathogenesis and prognosis. *Eur Neurol* 1988; 28: 111–114.
24. MATIAS-GUIU J, PICO M, BONAVENTURA I, MARTIN R, MONASTERIO J. Platelet aggregation in transient global amnesia. *Ital J Neurol Sci* 1989; 10: 171–174.
25. GUIDOTTI M, ANZALONE N, MORABITO A, LANDI G. A case-control study of transient global amnesia. *J Neurol Neurosurg Psychiatry* 1989; 52: 320–323.
26. OLESEN J, JORGENSEN MB. Leao's spreading depression in the hippocampus explains transient global amnesia: a hypothesis. *Acta Neurol Scand* 1986; 73: 219–220.
27. KIRINO T. Delayed neuronal death in the gerbil hippocampus following ischemia. *Brain Res* 1982; 239: 57–69.
28. WESTERBERG E, MONAGHAN DT, KALIMO H, COTMON CW, WIELOCH TW. Dynamic changes of Excitatory amino acid receptors in the rat hippocampus following transient cerebral ischemia. *J Neurosci* 1989; 9: 798–805.
29. ARAKI T, KATO H, KOGURE K. Selective neuronal vulnerability following transient cerebral ischemia in the gerbil: distribution and time course. *Acta Neurol Scand* 1989; 80: 548–553.
30. AUER RN, JENSEN ML, WHISHAW IQ. Neurobehavioral deficit due to the ischemic brain damage limited to half of the CA 1 sector of the hippocampus. *J Neurosci* 1989; 9: 1641–1647.
31. ZOLA-MORGAN S, SQUIRE L, AMARAL DG. Human amnesia and the medial temporal region: enduring memory impairment following a bilateral lesion limited to field CA 1 of the hippocampus. *J Neurosci* 1986; 6: 2950–2967.
32. PETITO CK, FELDMANN E, PULSINELLI WA, PLUM F. Delayed hippocampal damage in humans following cardio-respiratory arrest. *Neurology* 1987; 1281–1286.
33. DEJONG RN, ITABASHI HH, OLSON JR. Memory loss due to hippocampal lesions: report of a case. *Arch Neurol* 1969; 20: 339–348.
34. BENSON BF, MARSDEN CD, MEADOW JC. The amnesic syndrome of posterior cerebral artery occlusion. *Acta Neurol Scand* 1974; 50: 133–145.
35. CUMMINGS JL, TOMIYASU U, READ S, BENSON F. Amnesia with hippocampal lesions after cardiopulmonary arrest. *Neurology* 1984; 34: 679–681.
36. DUYCKAERTS C, DEROUESNE C, SIGNORET JL, GRAY F, ESCOUROLLE P. Bilateral and limited amygdalohippocampal lesions causing a pure amnesic syndrome. *Ann Neurol* 1985; 18: 314–319.
37. SCOVILLE WB, MILNER B. Loss of recent memory after bilateral hippocampal lesions. *J Neurol Neurosurg Psychiatry* 1957; 20: 11–21.