

Pleomorphic xanthoastrocytoma presenting with life-threatening hemorrhage in a child

Case report

JOSHUA J. WIND, M.D., P. BENJAMIN KERR, M.D., JENNIFER A. SWEET, M.D.,
AND VIVEK R. DESHMUKH, M.D.

Department of Neurosurgery, The George Washington University School of Medicine, Washington, DC

Pleomorphic xanthoastrocytomas are glial-based tumors that arise most frequently in young patients and usually follow a more benign and indolent clinical course than their other glial-based tumor counterparts. These tumors most frequently present with seizures, and only 3 previous case reports exist of hemorrhagic tumor as the clinical presentation. The authors present the first case of life-threatening intracerebral hemorrhage from pleomorphic xanthoastrocytoma in a child. (DOI: 10.3171/2008.10.PEDS0837)

KEY WORDS • intracerebral hemorrhage • intraparenchymal hemorrhage • pleomorphic xanthoastrocytoma

PLEOMORPHIC xanthoastrocytomas are low-grade glia-based tumors found in young patients. First described in 1979 by Kepes and colleagues,⁵ these lesions often have an insidious onset. Symptoms due to seizures are the first clinical presentation in 71% of patients, but symptoms related to a local mass effect are also possible.⁴ Despite the ominous histological characteristics, PXAs are classically considered to be associated with a more favorable prognosis than other gliomas. Gross-total resection of these tumors typically results in good long-term survival, with a reported 10-year survival rate of up to 70%.⁴

We present our experience with a patient who presented with a life-threatening intraparenchymal hemorrhage caused by a PXA. This is only the fourth reported case of hemorrhage from a PXA, and the first such presentation in a child.

Case Report

History and Presentation. This previously healthy, right-handed 5-year-old girl with a medical history of non-surgically treated intraventricular hemorrhage at birth collapsed while playing at school. She was taken to a local

hospital where CT scanning revealed a large intraparenchymal hemorrhage in the left temporal lobe and basal ganglia with significant midline shift and extension of the hemorrhage into the left lateral ventricle. The patient was flown emergently to our tertiary care facility for further care. On arrival her trachea was intubated and she was not arousable to voice. Her left pupil was dilated to 7 mm and was nonreactive, and her right pupil was 4 mm and reactive. She was localizing stimuli and spontaneously moving her left upper and lower extremities, but she did not move in response to painful stimuli on her right side.

Mannitol was administered and an emergency EVD placement was performed at her bedside. The child underwent CT angiography of her head and was subsequently taken directly to surgery. The angiogram was negative for the presence of a vascular malformation but showed further extension of the hemorrhage, effacement of the basilar cisterns, and transtentorial herniation (Fig. 1).

Operation and Postoperative Course. A left hemi-craniectomy was performed. Through a small corticectomy in the inferior temporal gyrus, the hematoma was evacuated to achieve brainstem decompression. Intraoperative inspection with an operating microscope revealed a

Abbreviations used in this paper: EVD = external ventricular drain; PXA = pleomorphic xanthoastrocytoma.

This article contains some figures that are displayed in color online but in black and white in the print edition.

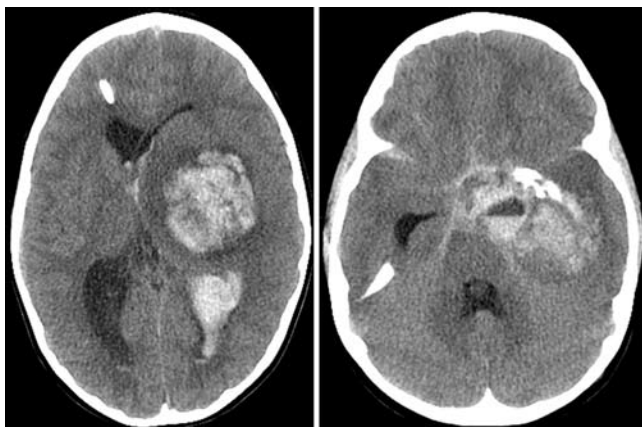


FIG. 1. Unenhanced axial CT scans of the brain after initial placement of ventriculostomy. These scans demonstrate a large hemorrhagic mass with substantial subfalcine herniation, transtentorial herniation, and brainstem compression.

hemorrhagic tumor. A tumor specimen was sent for histological confirmation. Postoperatively the patient was monitored in the pediatric intensive care unit with the EVD in place. Postoperative CT scans revealed decompression of the brainstem with improved midline shift. The patient's pupils were symmetrical postoperatively and she improved to speaking normally and following commands on the left side, with withdrawal on right.

Second Operation. On histological confirmation of a PXA, the patient underwent resection 3 weeks after initial surgery. The original craniectomy flap was reopened for exposure of the tumor. The anterior temporal lobe was resected to ~4 cm from the anterior tip, and the tumor was dissected medially to margin of the third ventricle and the pia-arachnoid membrane overlying the brainstem, basal cisterns, third cranial nerve, internal carotid artery, and middle cerebral artery. After resection, the bone flap was replaced. Comparison of pre- and postoperative MR images demonstrated gross-total resection (Fig. 2A and B). After a trial of EVD closure failed, the patient underwent uneventful placement of a ventriculoperitoneal shunt. She was discharged to a rehabilitation center on postoperative Day 33. On discharge, she could talk fluently and follow commands on her left side, and withdraw

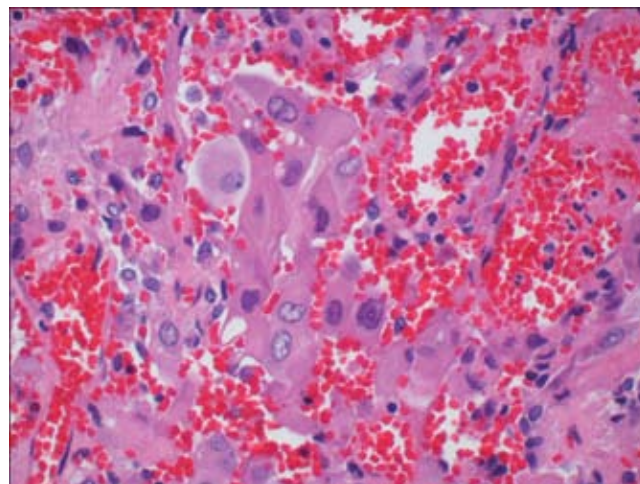


FIG. 3. Representative photomicrograph demonstrating pleomorphic nuclei with rare mitotic bodies. Areas of hemorrhage and necrosis are interspersed. H & E, original magnification $\times 200$.

both upper and lower extremities on the right. Repeated MR images obtained 9 months after the initial surgery demonstrated trace residual enhancement in the medial aspect of the tumor resection cavity, which could represent a small amount of residual tumor or scarring (Fig. 2C). The patient will undergo follow-up with serial MR imaging to evaluate this area of enhancement.

Histological Analysis. Histopathological analysis revealed pleomorphic cells that were focally positive for glial fibrillary acidic protein; the MIB-1 index was low (2–3%). Necrosis was present in this specimen, but it was not possible to determine whether this was a characteristic intrinsic to the tumor or secondary to hemorrhage. There was no evidence of vascular proliferation (Fig. 3).

Discussion

The subset of glial-based tumors known as PXAs are a relatively recent classification of tumor, first described in 1979⁵ and added to the World Health Organization classification schema in 1993.⁶ This is a rare tumor type, accounting for 1% of all astrocytic tumors. Although most data concerning the natural history of these neoplasms and their

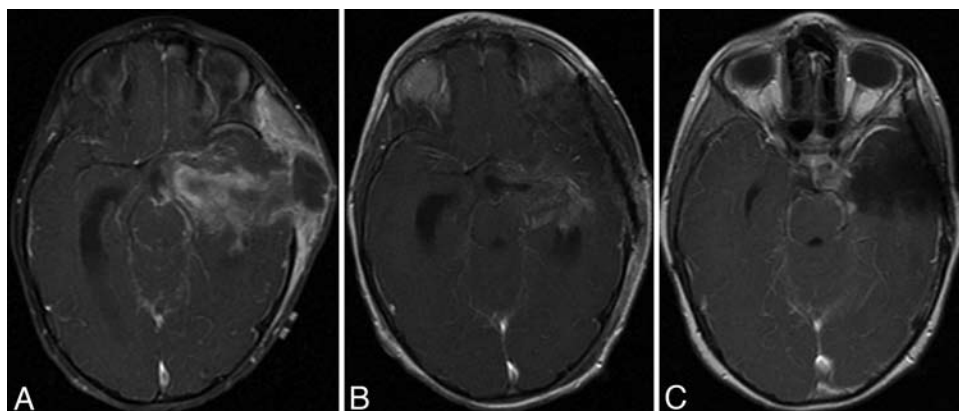


FIG. 2. Contrast-enhanced, axial T1-weighted MR images obtained before the final resection (A), after final resection (B), and 9 months after resection (C).

Pleomorphic xanthoastrocytoma presenting with hemorrhage

response to various types of therapy is derived from case reports and small series, there are certain trends associated with this histopathological entity.

Pleomorphic xanthrocytomas often present within the first 3 decades of life^{3,4} and seem to have a predilection for the temporal lobe. These lesions classically follow a more benign course than other astrocytic tumors, with reported 10-year survival rates of as much as 70%.⁴ There are reported cases of malignant transformation of PXAs; a subclassification of anaplastic PXA is used to describe some of the more aggressive variants.^{1,8,9}

The mainstay of management for PXA is resection.^{3,4} Adjuvant radiotherapy and chemotherapy are often used in recurrent, unresectable lesions, or cases of anaplastic variants of the tumor, but there are not yet enough data to support an evidenced-based approach to their use.

The majority of PXAs have an insidious onset, most frequently in the setting of a long history of seizure disorder. Pleomorphic xanthrocytomas presenting with tumor hemorrhaging have been reported previously. Levy et al.⁷ described the case of a 46-year-old woman who presented with hemorrhagic PXA and died. Deshmukh et al.² reported on a 38-year-old woman who presented with hemorrhagic PXA and neurological deterioration who was discharged in good neurological condition after she underwent tumor resection and surgical evacuation of the hematoma. Yoshida and colleagues¹⁰ published their experience with a hemorrhagic presentation in a 61-year-old woman who had a good recovery after hematoma evacuation and tumor resection. The present study is the fourth known case of a hemorrhagic presentation of a PXA and the first reported in a child.

Pleomorphic xanthrocytomas are classically superficially located, with frequent leptomeningial involvement. It is postulated that invasion of leptomeningial vessels could contribute to the pathogenesis of tumor hemorrhage; however, no explanation has yet been provided as to why tumor hemorrhage is such an uncommon event.

Conclusions

Pleomorphic xanthrocytomas are clinicopathological entities normally associated with an insidious onset and a favorable prognosis after resection. We present a case of an abrupt presentation of PXA in the form of life-threatening hemorrhagic tumor in a child. Pleomorphic xanthrocy-

tomas should be recognized as a rare cause of intracerebral hemorrhage in children.

Disclaimer

The authors report no conflict of interest concerning the materials or methods used in this study or the findings specified in this paper.

References

1. Chakrabarty A, Mitchell P, Bridges LR, Franks AJ: Malignant transformation in pleomorphic xanthoastrocytoma—a report of two cases. **Br J Neurosurg** **13**:516–519, 1999
2. Deshmukh VR, Hsu FPK, Klopfenstein JD, Coons SW, Spetzler RF: Pleomorphic xanthoastrocytoma presenting with intraparenchymal and subdural hematoma: case report. **BNI Q** **20**:18, 2004
3. Fouladi M, Jenkins J, Burger P, Langston J, Merchant T, Heide-man R, et al: Pleomorphic xanthoastrocytoma: favorable outcome after complete surgical resection. **Neuro-oncol** **3**:184–192, 2001
4. Giannini C, Scheithauer BW, Burger PC, Brat DJ, Wollan PC, Lach B, et al: Pleomorphic xanthoastrocytoma: what do we really know about it? **Cancer** **85**:2033–2045, 1999
5. Kepes JJ, Rubinstein LJ, Eng LF: Pleomorphic xanthoastrocytoma: a distinctive meningocerebral glioma of young subjects with relatively favorable prognosis. A study of 12 cases. **Cancer** **44**:1839–1852, 1979
6. Kleihues P, Burger PC, Scheithauer BW (eds): **Histological Typing of Tumours of the Central Nervous System, ed 2**. New York: Springer-Verlag, 1993
7. Levy RA, Allen R, McKeever P: Pleomorphic xanthoastrocytoma presenting with massive intracranial hemorrhage. **AJNR Am J Neuroradiol** **17**:154–156, 1996
8. Marton E, Feletti A, Orvieto E, Longatti P: Malignant progression in pleomorphic xanthoastrocytoma: personal experience and review of the literature. **J Neurol Sci** **252**:144–153, 2007
9. Nakajima T, Kumabe T, Shamoto H, Watanabe M, Suzuki H, Tominaga T: Malignant transformation of pleomorphic xanthoastrocytoma. **Acta Neurochir (Wien)** **148**:67–71, 2006
10. Yoshida D, Kogiku M, Noha M, Takahashi H, Teramoto A: A case of pleomorphic xanthoastrocytoma presenting with massive tumoral hemorrhage. **J Neurooncol** **71**:169–171, 2005

Manuscript submitted March 21, 2008.

Accepted October 30, 2008.

Address correspondence to: Joshua J. Wind, M.D., The George Washington University Medical Center, 2150 Pennsylvania Avenue, NW, Suite 7420B, Washington, DC 20037. email: jwind@gwu.edu.