

ORIGINAL ARTICLE

# Adult Cases of Leukoencephalopathy, Cerebral Calcifications, and Cysts: Expanding the Spectrum of the Disorder

Bette Kay Kleinschmidt-DeMasters, MD, Thomas J. Cummings, MD, Christine M. Hulette, MD, Joel C. Morgenlander, MD, and John R. Corboy, MD

## Abstract

Leukoencephalopathy with cerebral calcifications and cysts (LCC) was first reported in children who developed cognitive decline and variable extrapyramidal, cerebellar, and pyramidal signs, with or without seizures. Leukoencephalopathy with cerebral calcifications and cysts is characterized by progressive formation of brain cysts that can generate a mass effect simulating a neoplasm. Retinal changes that overlap with Coats disease, a microangiopathy with retinal telangiectasias and exudates, may also occur. We and others have reported LCC cases in adults. Neuroimaging shows diffuse leukoencephalopathy, multifocal calcifications especially of deep gray and white matter, multifocal enhancement, and variably sized cysts that may require surgical decompression. Biopsies adjacent to cysts have shown angiomatous and/or severely hyalinized blood vessels surrounded by myelin loss and gliosis, calcifications, and Rosenthal fibers. We report 2 additional adult-onset cases of LCC. Case 1 is a 40-year-old man who developed neurological symptoms and cirrhosis and died of acute gastrointestinal bleeding; he had numerous retinal microinfarcts at autopsy. Case 2 is a 55-year-old woman who was found by chance to have LCC; one and a half years later, her course remains benign. These cases expand the spectrum of adult-onset LCC, the etiology of which is unknown.

**Key Words:** Angiomatous malformation, Cerebral calcification, Cerebroretinal microangiopathy, Leukoencephalopathy, Pilocytic astrocytoma, Rosenthal fibers, Vasculitis, Vasculopathy.

## INTRODUCTION

Leukoencephalopathies are seldom considered in the clinical or pathological differential diagnosis of volume-expanding processes such as brain neoplasms. Indeed, most leukoencephalopathies result in shrinkage of the white matter and, eventually, the overall size of the brain. Only rare leukoencephalopathies produce megalencephaly.

In 1996, Labrune et al (1) reported on 3 pediatric patients with the unique triad of progressive cerebral and cerebellar calcifications, diffuse abnormal white matter sig-

nal on magnetic resonance imaging (MRI), and large space-occupying cysts in the brain that generate a mass effect. The authors felt that this was a “diffuse cerebral microangiopathy, resulting in microcystic and then macrocystic parenchymal degeneration” (1). Nagae-Poetscher et al (2) added 3 more pediatric cases in 2004, one of whom had retinopathy, skin, and hair changes, in addition to the leukoencephalopathy and interhemispheric cyst, suggesting some overlap between leukoencephalopathy with cerebral calcifications and cysts (LCC) and Coats disease, a pediatric disorder with retinal telangiectasias, retinal exudates, intracranial calcifications, sparse hair, and dystrophic nails, but no brain cysts. Detailed neuroimaging studies suggested that the disorder was caused by increased water content in white matter rather than a demyelinating process (2). By 2006, Linnankivi et al (3) had identified 13 more pediatric patients, thereby cementing the overlap between LCC and Coats/Coats plus disease (4); they suggested a new name for the condition, *cerebroretinal microangiopathy with calcifications and cysts* (3). Their report underscored the variability of neurological and neuroimaging features in the pediatric population, as well as the presence of systemic signs in some patients. Extensive testing of these patients has not revealed an etiology of this disorder.

In 2006, we reported the first case of LCC with onset in later adult life (5). To our knowledge, only 2 other reports of later adult-onset disease have appeared since that time (6, 7). Unlike the pediatric-onset cases of LCC/cerebroretinal microangiopathy with calcifications and cysts, almost nothing is known about the possible variability of clinical and pathological changes in patients with later adult-onset disease. We report on 2 new individuals with onset and diagnosis after age 40 years and provide greater detail of the morphological aspects of the disorder.

## CASE SUMMARIES

### Case 1

A 42-year-old white man presented in 2004 at age 40 years with an undefined multisystem illness that included neurological manifestations. The patient worked as a technical hydraulics and industrial equipment salesperson. He denied recent travel. He had 2 dogs, 2 turtles, a guinea pig, and no cats. The patient denied alcohol, drug, or tobacco use. He was in good health until late 2004 when he developed severe cramping abdominal pain. He did not experience symptoms of cardiovascular disease. Vital signs were normal, and blood pressure was recorded as 137/71 mm Hg or lower on several

From the Departments of Pathology (BKKD), Neurology (BKKD, JRC), Neurosurgery (BKKD), University of Colorado, Denver, Anschutz Medical Campus, Aurora, Colorado; Denver Veterans Affairs Medical Center (JRC); and the Departments of Pathology (TJC, CMH) and Medicine (Neurology) (JCM), Duke University Health System, Durham, North Carolina.

Send correspondence and reprint requests to: Bette Kay Kleinschmidt-DeMasters, MD, UCDHSC, Department of Surgical Pathology, Mail Stop B216, 12631 E. 17th Ave, Aurora, CO 80045; E-mail: bk.demasters@ucdenver.edu

occasions. Cardiology consultation was not obtained. The patient underwent an abdominal computerized tomography (CT) scan that showed diffuse colitis, cirrhosis, portal hypertension, and retrovesicular fluid. The etiology of this was unknown. Serological tests for hepatitis were negative. Infectious disease consultation failed to uncover an infectious cause of the patient's symptoms. The patient underwent colonoscopy for further evaluation, which showed patchy mucosal erythema, petechiae, and edema. Colon biopsies showed increased vascularity of the colonic lamina propria. At that time, the patient also reported a right footdrop that had been present for approximately 2 weeks. A head CT scan showed a left parietal ring-enhancing lesion with calcification. A chest CT, bone-scan, and human immunodeficiency virus test were all normal. The patient had a maternal cousin with a very similar presentation and similar MRI findings. The cousin also underwent stereotactic brain biopsy, which apparently showed only gliosis and necrosis. The cousin also had colitis of unknown etiology and died at age 35 years. There were several other family members who had had similar presentations of either stroke or intracranial lesion that had not been further evaluated before their deaths. The patient had a daughter who died at 2 weeks of age. The child had had hypotonia, arthrogryposis, and respiratory distress. Muscle biopsy at autopsy had suggested neurogenic atrophy in that child, and a type of spinal muscular atrophy had been considered.

Extensive workup of the patient was undertaken. It included a muscle biopsy for suspected mitochondrial disorder. Light microscopic examination showed rare atrophic fibers, and focal large mitochondrial aggregates were seen by electron microscopy, but no specific diagnosis could be rendered. A liver biopsy showed irregular portal and periportal fibrosis. No vascular proliferation was seen. Electron microscopy showed mitochondria with paracrystalline inclusions. He also developed diabetes mellitus. An MRI scan of the brain revealed multiple, irregular, and heterogeneously enhancing lesions scattered throughout the brain (Figs. 1A, B). In 2004, he underwent brain biopsy that disclosed multifocal vascular proliferation associated with necrosis, gliosis, and macrophage infiltration (Fig. 1C). A second brain biopsy was performed because of concern for tumor when an enlarging mass caused increased symptoms as steroids were being tapered. The disease continued to progress, and repeat MRI scan in 2005 showed persistence of these changes but with an additional heterogeneously enhancing lesion in the right frontal lobe that extended to the ependymal surface of the posterior body of the right lateral ventricle. This was associated with extensive vasogenic edema, causing a significant mass effect with effacement of the body of the right ventricle and nearby sulci. There was also a new, mild, 3- to 4-mm midline shift to the left. The patient had cognitive deficits in attention, language, and memory, along with slurred speech, spastic weakness, and ataxia. Throughout his course, only the use of Decadron seemed to lessen neurological symptoms and signs, but his course became progressive despite its use.

Visual-evoked potentials disclosed mild prolongation of P100 latency to 116 and 120 milliseconds, whereas somatosensory-evoked potential studies were normal. Laboratory tests included acellular cerebrospinal fluid with normal

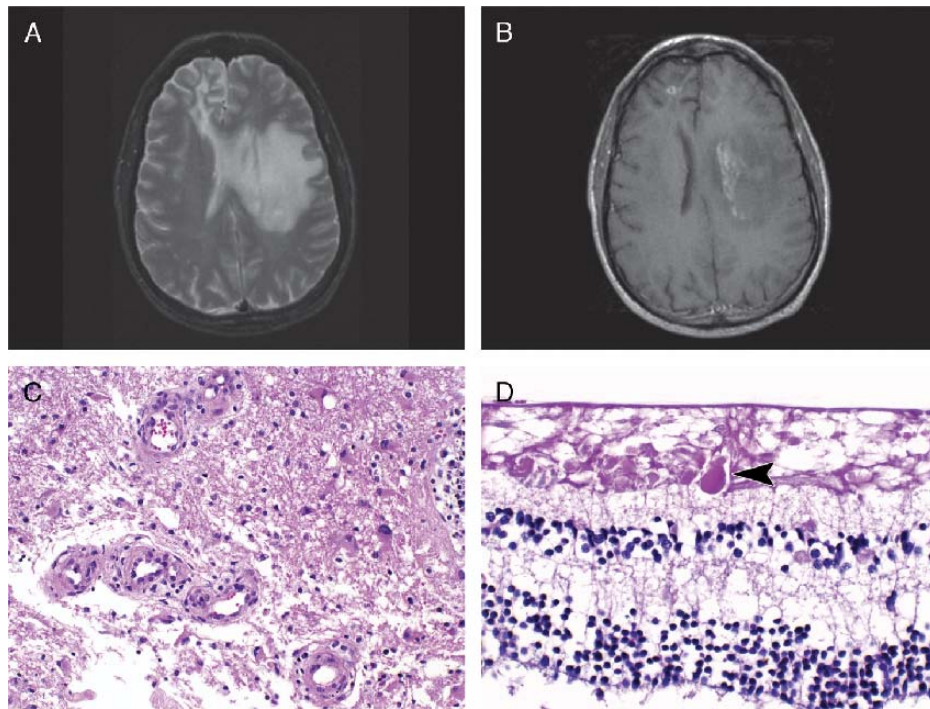
immunoglobulin G index and absent oligoclonal bands and normal human immunodeficiency virus serology, rheumatologic serologies, hereditary hemorrhagic telangiectasia genetic test,  $\alpha$ -glucosidase in fibroblasts, mitochondrial DNA Southern blot, and point mutation screen in muscle, plasma lactate, and urine organic acids. Nonspecific amino acid elevations in blood and urine were found. Testing for cerebral autosomal dominant arteriopathy with subcortical infarcts and leukoencephalopathy (CADASIL) demonstrated a polymorphism not known to be associated with CADASIL. There was a Complex 1 defect in muscle oxidative phosphorylation that may have been secondary to the underlying disease process. Follow-up muscle biopsy had vacuolar change of uncertain cause. Brain biopsy tissue for adrenal cholesterol fatty acid profile was negative.

The patient was readmitted to the hospital in February 2006 for aspiration pneumonia, right common femoral vein deep venous thrombosis, and worsened neurological status. He continued to deteriorate and was placed in hospice care. He developed an acute lower gastrointestinal bleed and died in April 2006.

Permission for full autopsy was obtained, and general examination confirmed acute pneumonia, pulmonary edema, ascites, and pleural effusions. There were mild hypertensive-type changes in the kidneys (i.e. arterial and arteriolar nephrosclerosis), and changes suggestive of severe hypertension during life were absent. There was micronodular cirrhosis (liver weight, 740 g; normal median, 1,840 g). The heart was mildly enlarged and weighed 440 g, but the left ventricle was not hypertrophied or dilated. There was mild to moderate coronary atherosclerosis with maximal 50% stenosis of the right and left anterior descending arteries. No vascular malformations or increased vascularity of the colonic mucosa could be discerned, but severe autolysis precluded optimal study. Microscopic examination of the eyes disclosed numerous bilateral microinfarcts of the retinal nerve fiber layer ("cotton wool" spots) inferior to the macula and involving the peripapillary retina (Fig. 1D) and chronic, mild, bilateral, nongranulomatous choroiditis. Retinal telangiectasias were not seen. These changes had not caused symptoms premortem.

The brain weighed 1,380 g and showed 2 small surface hemorrhagic lesions at the sites of his previous biopsies. There was diffuse cerebral swelling, with brainstem and bilateral uncal herniations. Coronal sections disclosed multiple cystic defects and softening in the left frontal lobe white matter, without true necrosis. The largest lesion was approximately 3 cm in diameter, spared the cortical ribbon, and extended from the orbitofrontal cortex caudally to the level of the genu of the corpus callosum. An additional 1-cm-diameter white matter lesion was seen in the right frontal lobe. There were additional 3-cm-diameter cystic lesions posteriorly at the level of the thalamus in bilateral white matter; the left posterior lesion showed hemosiderin staining, consistent with the previous biopsy site. A 2-cm-cystic lesion was identified in the left inferior occipital lobe. Brainstem, cerebellum, and spinal cord were grossly unremarkable.

Microscopic examination of Luxol fast blue-hematoxylin and eosin-stained sections demonstrated severe pallor, myelin loss, and focal cavitation/cystic change of the cerebral



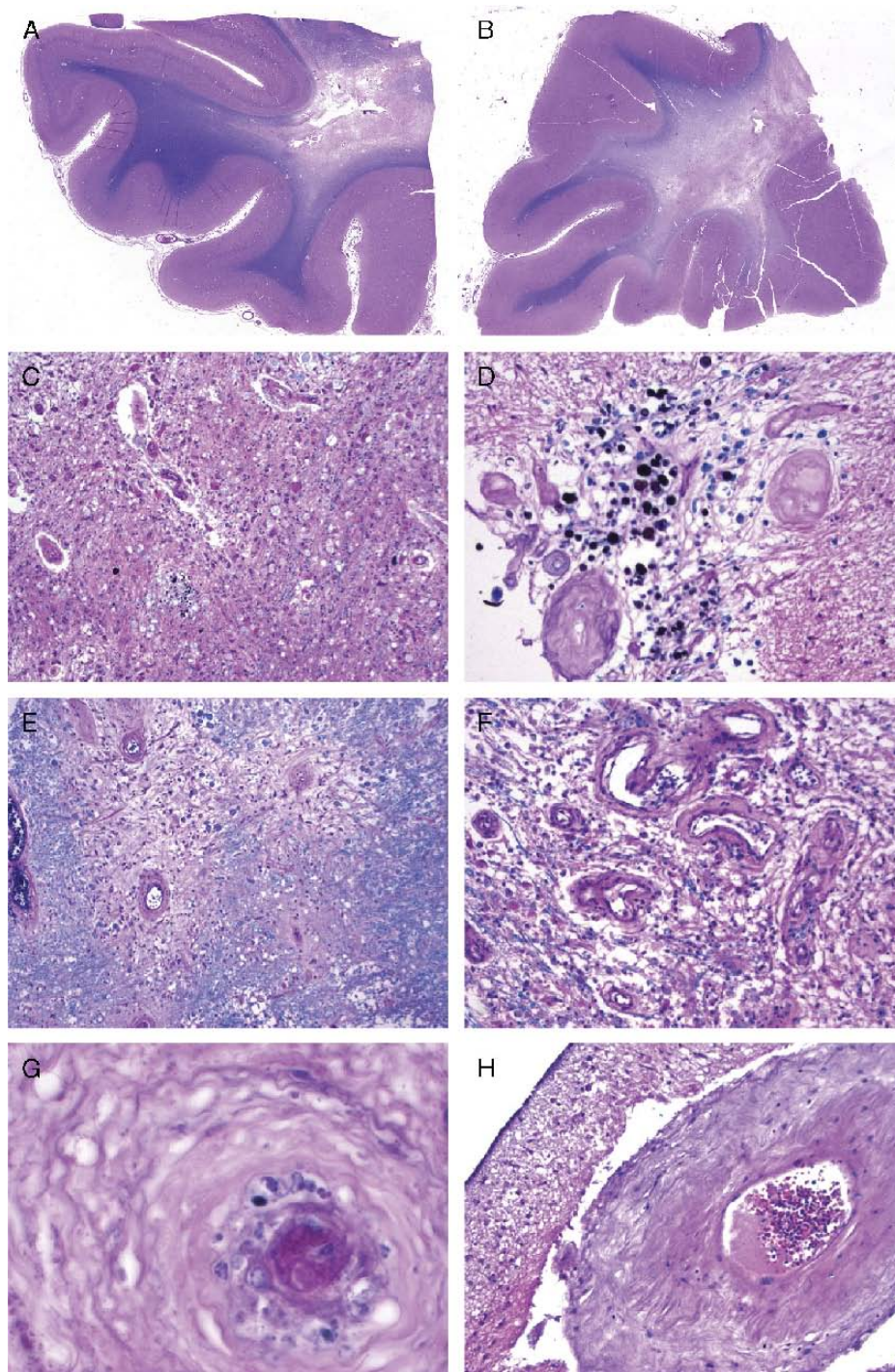
**FIGURE 1.** Case 1. **(A)** Axial T2-weighted magnetic resonance (MR) image shows multiple lesions along the ependymal surface. There is extensive T2 signal abnormality in the adjacent white matter that extends to the precentral and postcentral gyrus, left external capsule, and posterior limb of the left internal capsule. **(B)** Axial T1-weighted MR imaging with gadolinium enhancement shows abnormal areas of heterogeneous and irregular enhancement in the left frontal, left occipital, and anterior right frontal lobes. There is a 6-mm midline shift. Hypointensity within the white matter is seen adjacent to the largest lesion within the left frontal lobe. **(C)** Brain biopsy performed soon after clinical presentation disclosed multifocal vascular proliferation associated with necrosis, gliosis, and macrophage infiltration. Hematoxylin and eosin (H&E), original magnification: **(C)** 20 $\times$ . **(D)** Microscopic examination of the eye at autopsy showed an infarct of the nerve fiber layer of the retina (“cotton wool” spot). The arrowhead indicates a cytooid body. H&E, original magnification: **(D)** 40 $\times$ .

white matter (Fig. 2A). This particularly involved deeper white matter and manifested irregular involvement of arcuate fibers (Figs. 2A, B). There were patchy rarefaction and gliosis in the noncystic areas (Fig. 2C) that were accompanied by dystrophic microcalcifications (Fig. 2D) and numerous macrophages. Many of the smaller areas of white matter damage were centered around abnormal vessels (Fig. 2E). Although these areas showed necrosis, macrophage influx, and extensive astrocytosis, there were no Rosenthal fibers. Small-vessel vasculopathy in white matter and deep gray matter areas was striking and heterogeneous; there were small hyalinized vessels with remote occlusion and perivascular dystrophic mineralization (Fig. 2D), delicate patent angiomatous vessels (Fig. 2F), and severely hyalinized and altered larger-caliber arteries (Fig. 2G) and veins (Fig. 2H). The venous alterations were particularly prominent in the deep periventricular striate veins (Fig. 2H). Thrombosed fibrotically thickened vessels were particularly prominent in the left basal ganglia and right cingulate gyrus. Only small areas of patchy myelin pallor were identified in temporal lobe, right parietal lobe, and left cerebellum in regions remote from the abnormal vasculature. The pattern of involvement lacked bilateral symmetry. No cortical gray matter involvement was identified, and leptomeningeal vessels were completely normal. None of the abnor-

mal vessels in deep white or gray matter areas showed evidence of vasculitis. Congo red stain for amyloid on multiple sections of affected cortex, subcortical nuclei, and brainstem failed to reveal any evidence of vascular or intraparenchymal amyloid. Electron microscopy had been performed on the brain biopsy obtained during life. The destruction of smooth muscle cells and the deposition of granular osmiophilic material characteristic of CADASIL were absent. Mitochondria were unremarkable; specifically, the mitochondrial aggregates and inclusions that had been seen in the skeletal and liver biopsies, respectively, were not identified. The autopsy brain was fixed in formalin and the resulting artifactual distortion together with postmortem autolysis precluded electron microscopy on the autopsy tissue. Granular nonamyloid material in the media characteristic of CADASIL was absent. The anatomical distribution of vessel changes, coupled with the angiomatous features, excluded simple severe arteriosclerosis. Descending, asymmetrical, secondary corticospinal tract Wallerian tract degeneration could be traced throughout the brainstem and spinal cord.

## Case 2

This 55-year-old woman was healthy until she was involved in an automobile accident as a seat-belted passenger

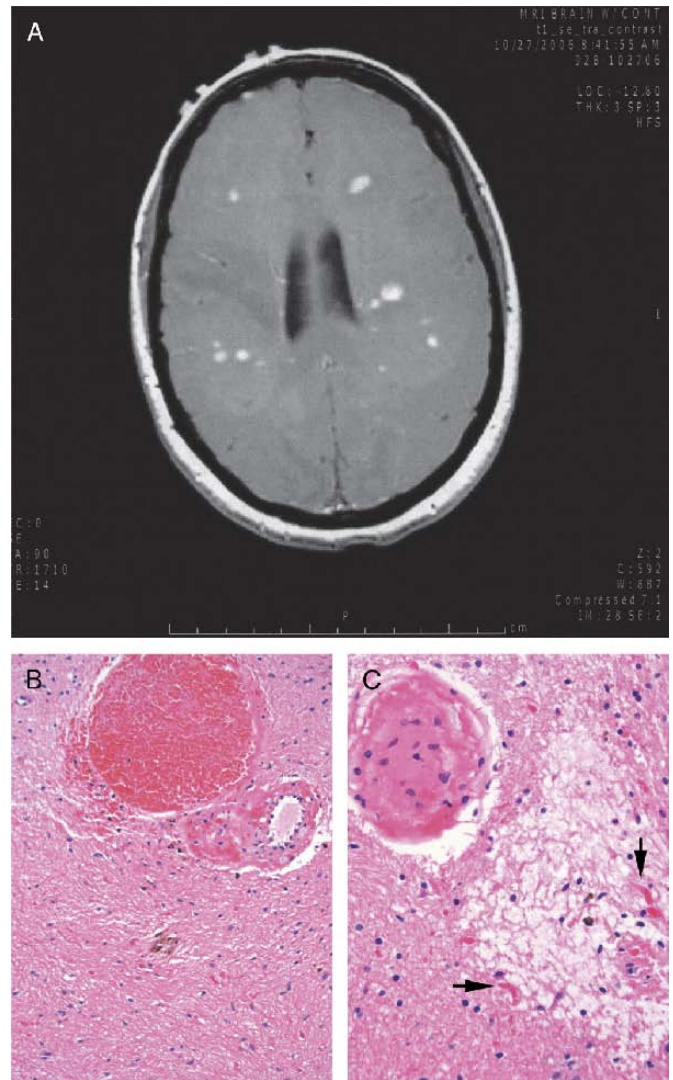


**FIGURE 2.** Case 1. Whole-mount sections stained for myelin illustrate partially cavitated, partially demyelinating lesions in the subcortical white matter of the left occipital lobe **(A)** and right orbital frontal cortex **(B)**. Luxol fast blue (LFB)/hematoxylin and eosin (H&E), original magnification: **(A, B)** approximately 2×. **(C)** Patchy rarefaction and gliosis found in noncystic areas. LFB/H&E, original magnification: **(C)** 40×. **(D)** Higher power of central region in **(C)** illustrates prominent dystrophic mineralization and markedly hyalinized and thickened blood vessels in this area. LFB/H&E, original magnification: **(D)** 100×. **(E)** Photomicrograph showing that in noncavitated areas, the myelin damage often was maximal around the severely altered small blood vessels. LFB/H&E, original magnification: **(E)** 40×. **(F)** Case 1 illustrated. Photomicrograph shows that some of the altered vessels in the white matter are delicate patent angiomatous vessels. LFB/H&E, original magnification: **(F)** 100×. **(G)** Large-caliber artery with extensive hyalinization. LFB/H&E, original magnification: **(G)** 600×. **(H)** A markedly hyalinized vein near the ventricular surface (upper left). LFB/H&E, original magnification: **(H)** 100×.

in August 2006. She experienced transient loss of consciousness and went to the emergency department at an outside hospital from which she was sent home that night. She returned the next day with nausea, vomiting, and headache, and was admitted to the hospital. A head CT scan performed at the outside hospital reportedly showed “abnormalities” but no calcium, although the actual scan was not available for review at our institution. An MRI scan was then performed (reviewed at our institution), which showed dramatic changes including widespread leukoencephalopathy of the cerebral white matter, more prominent anteriorly than posteriorly, with multifocal cysts up to 1 cm in diameter. Numerous punctate enhancing lesions were distributed throughout the cerebrum (Fig. 3A). The cerebellum was uninvolved by cysts, enhancement, or white matter changes. There was a small amount of mass effect and edema associated with these cerebral changes, and there was a mild downward displacement of the tonsils. Because of concern at the outside hospital that this striking imaging finding represented a neoplastic or infectious condition, extensive evaluation was undertaken. Cerebrospinal fluid and neurological examination were normal. Evaluation for *Cryptococcus* and toxoplasmosis was negative. The CT scans of the abdomen, pelvis, and thorax were unremarkable. An MR angiogram of the neck showed only minimal stenosis. The patient was treated with Decadron at the outside hospital (dose unknown) because of the mass effect, and her symptoms resolved; the role of the Decadron treatment in this was unclear. A repeat brain MRI scan 2 months later was essentially unchanged; this prompted a right frontal lobe brain biopsy that was referred to us for consultation.

The brain biopsy disclosed angiomatous small blood vessels with relatively thin walls with minimal hyalinization but with focal fibrinoid vascular necrosis and microhemorrhages (Fig. 3B). There were thrombosed small vessels that were surrounded by foci of rarefaction (Fig. 3C), gliosis, and numerous Rosenthal fibers (Fig. 3C). No calcifications were identified, but much of the small biopsy was composed of uninvolved cortical gray matter. Congo red stains were negative for amyloid. Periodic acid-Schiff stain and immunostaining for muscle-specific actin showed no periodic acid-Schiff-positive material in the media of blood vessels or disruption of the normal pattern of smooth muscle cells in small blood vessels. Electron microscopy (Hitachi model H7650, Tokyo, Japan) performed on tissue taken from the paraffin block in areas specifically targeted for abnormal blood vessels further confirmed that small blood vessels possessed no granular osmophilic material suggestive of CADASIL.

The patient was referred to the University of Colorado Health Sciences Center for additional evaluation by one of the authors (John R. Corboy). Medical history was notable for mild hypertension, but the changes seen on MRI scan were interpreted inconsistent with any known hypertensive manifestation in the central nervous system. The patient described recent headaches, but denied seizures, other episodes of loss of consciousness beyond that experienced in the automobile accident, numbness, tingling, weakness, or loss of bowel or bladder control. Extensive review of her medical and neuroimaging records suggested that she had asymptomatic



**FIGURE 3.** Case 2. **(A)** Axial magnetic resonance imaging scan demonstrates numerous punctate enhancing lesions distributed throughout the cerebrum. T1-weighted scan with contrast. **(B)** Photomicrograph of the brain biopsy showing angiomatous small blood vessels with relatively thin walls and minimal hyalinization but with focal fibrinoid vascular necrosis and microhemorrhage. Hematoxylin and eosin (H&E), original magnification: **(B)** 200 $\times$ . **(C)** Thrombosed small vessels in the biopsy are surrounded by foci of rarefaction, gliosis, and Rosenthal fibers (arrows). H&E, original magnification: **(C)** 200 $\times$ .

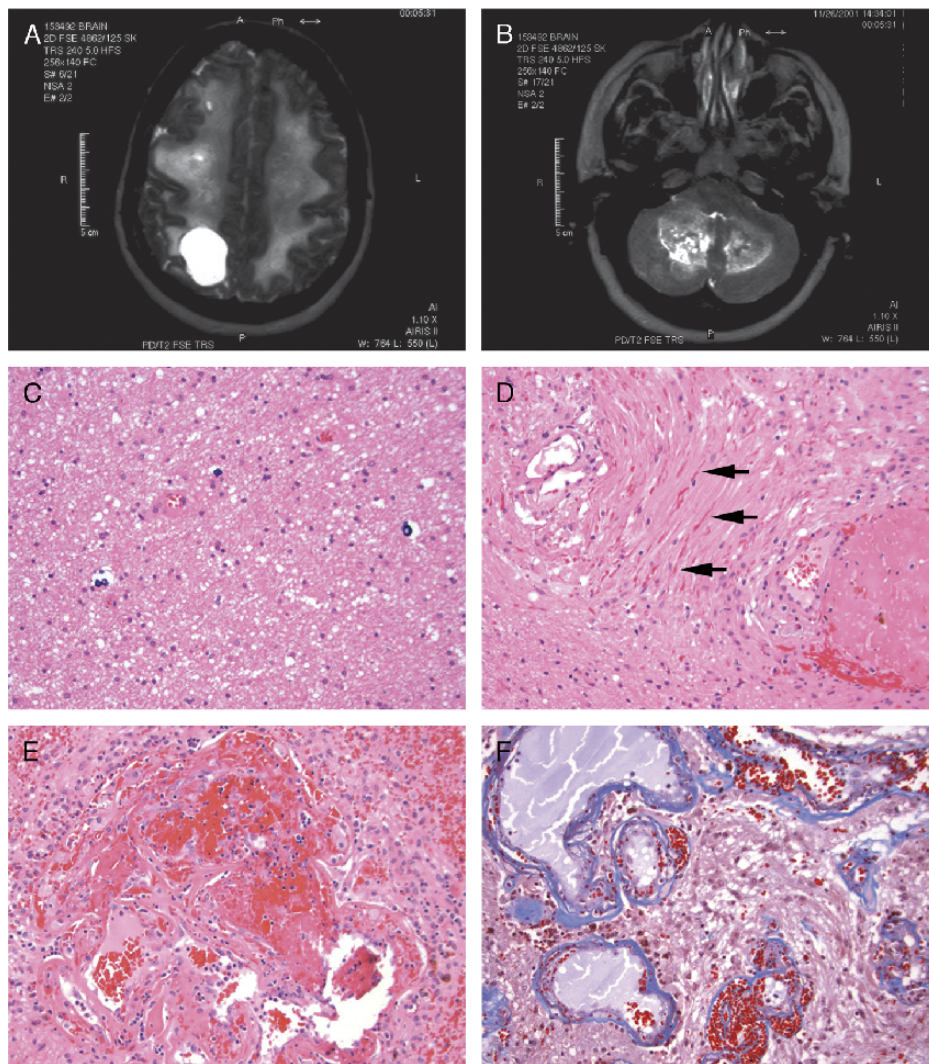
leukoencephalopathy with cysts and the aforementioned vascular alterations. The cysts were small and apparently unassociated with discernible calcifications. Because of the overlap of LCC with retinal conditions (i.e. Coats exudative retinopathy), she was referred to a neuro-ophthalmologist for a retinal examination, which was negative.

The patient had been followed since that time by her primary care physician, with last visit in late April 2008. She remains well, and no additional neuroimaging studies have been performed at this time.

**Case 3**

This case was previously reported (5). The features of this case are summarized for direct comparison to those of Cases 1 and 2; the severity and duration seem intermediate between the new cases. This 44-year-old woman developed daily headaches that worsened over a short interval; over the next 6 years, she developed progressive ataxia, seizures, and mild cognitive dysfunction. Her headaches partially responded to corticosteroids. She did not have systemic manifestations or chronic hypertension. Head CT and brain MRI demonstrated extensive cerebral and cerebellar white matter leukoencephalopathy, cysts, and calcifications, with multifocal areas of enhancement (Figs. 4A, B) (5). A mass effect fluctuated over time to include both sides of the brain. She had papilledema, Type I Chiari malformation, and a cervical

syrinx. In addition to the diagnostic studies previously described (5), genetic testing for CADASIL (Athena Diagnostics, Worcester, MA) was negative. Biopsy showed features of diffuse gliosis and microcalcifications (Fig. 4C), thrombosis (Fig. 4D), and fibrinoid necrosis (Fig. 4E) of deep white matter vessels, but no vasculitis. Profuse Rosenthal fibers were seen (Fig. 4D). Vessels were closely juxtaposed but lacked true features of a cavernous malformation (Fig. 4F). Congo red stains were negative for amyloid. Periodic acid-Schiff stain and immunostaining for muscle-specific actin (Enzo Diagnostics, Farmington, NY; 1:40 dilution) showed no periodic acid-Schiff-positive material in the media of blood vessels or disruption of the normal pattern to smooth muscle cells of small blood vessels. Electron microscopy performed on tissue taken from the paraffin block further



**FIGURE 4.** Case 3. Neuroimaging studies reveal extensive cerebral (A) and cerebellar (B) white matter leukoencephalopathy, cysts, and calcifications with multifocal areas of enhancement. T1-weighted image after the injection of contrast. (C) Photomicrograph of the brain biopsy shows diffuse gliosis and microcalcifications. Hematoxylin and eosin (H&E), original magnification: (C) 100×. (D) Vessels within white matter show thrombosis (right side of field) and are surrounded by numerous Rosenthal fibers (arrows). H&E, original magnification: (D) 100×. (E) Fibrinoid necrosis of deep white matter vessels but without features of amyloid angiopathy, vasculitis, or CADASIL. H&E, original magnification: (E) 100×. (F) Some abnormal white matter vessels are closely juxtaposed but lacked true features of a cavernous malformation. Trichrome stain, original magnification: (F) 100×.

confirmed that small blood vessels possessed no granular osmophilic material suggestive of CADASIL. Her clinical course is described in the article by Corboy et al (5). No autopsy was performed.

## DISCUSSION

These 3 patients all seem to have adult-onset LCC. The clinical manifestations of this disorder in children are quite variable, and they also seem to be variable in adults. Although LCC in adults has some clinical and histological features suggestive of CADASIL, amyloid angiopathy, or chronic hypertension, these diagnoses were excluded by clinicopathological criteria, genetic testing, and ultrastructural studies.

The 2 new adult patients reported on here expand the clinical and pathological spectrum of features of LCC; Case 1 manifested an accelerated and severe clinical scenario with death within 2 years; Case 2 thus far has exhibited surprisingly almost no clinical symptoms despite the striking neuroimaging abnormalities. Indeed, one of the remarkable aspects of the disorder can be the “disconnect” between the highly worrisome MR findings and the relative limited nature of clinical abnormalities, at least early in the disorder. Case 2 first came to medical attention serendipitously after a motor vehicle accident, with only modest neurological complaint and deficits; she has continued to exhibit a benign clinical course without discernible deterioration for the past one and a half years. These 2 new adult cases bracket Case 3, a woman who had a progressive, but at least 6-year disease course before succumbing to an intracerebellar bleed during anticoagulation.

Long survival with LCC was shown by Linnankivi et al (3) in pediatric patients, and was corroborated in another 2006 report that briefly described a 20-year-old woman with LCC who had presented with a seizure at age 1 month, developed progressive ataxia, generalized dystonia, spasticity, dysarthria, and cognitive decline at age 14 months, but 2 decades later was still alive, albeit wheelchair-bound and severely demented (8).

To our knowledge, there are only 3 adult-onset LCC cases reported (5–7). All 3 adults had been extensively investigated to exclude other causes, and none had retinopathy, suggesting that late adult-onset cases may represent the more limited end of the disease scale.

As described in the original report, the essential feature of LCC seems to be “diffuse cerebral microangiopathy, resulting in microcystic, then macrocystic, parenchymal degeneration” (1). Depending on the anatomical location and distribution of these vessel and cyst changes, there can be widely varying cerebral, cerebellar, and even spinal cord manifestations; Case 3 had a cervical syrinx. As our 3 adult cases illustrate, there seems to be variability in time course and progression of the disease in patients with late-onset LCC, similar to the diversity in time course and progression in young-onset LCC (3).

Our 3 cases and the cases reported by Sener et al (6) and Wargon et al (7) in adults had parenchymal brain cysts. This feature is likely to prompt clinical confusion with a neoplasm, particularly if the cyst causes dramatic and al-

ternating fluid shifts in the brain over time, as in Case 3. The additional histological finding of angiomatous blood vessels and Rosenthal fibers near the cysts makes distinction of LCC from pilocytic astrocytoma nearly impossible without corroborating neuroimaging information.

We describe some variation in the morphological features of adult-onset LCC. The degree of vascular thickness and hyalinization was variable; our end-stage severe Case 1 was found at autopsy to have multifocal, exceedingly thickened, and thrombosed vessels surrounded by marked astrocytosis, macrophages, and focal necrosis. There were no Rosenthal fibers in this case; their absence is perhaps not surprising because Rosenthal fibers are generally associated with more chronic, indolent, and less fulminant astrocytic proliferative processes. Case 3 had an intermediate 6-year time course, more delicate angiomatous vasculature, and vessel hyalinization and thickening were less severe than those in Case 1. In Case 3, there were surrounding extensive astrocytosis, more calcifications, and larger numbers of Rosenthal fibers than those in Case 1. The vessels in the biopsy in Case 2 (the most clinically benign case) showed characteristic angiomatous and microthrombotic changes but little hyalinization. This patient had numerous small punctate lesions by neuroimaging, suggesting that her disease was less advanced. The angiomatous vessels in the biopsy were surrounded by moderate numbers of Rosenthal fibers, and both neuroimaging and biopsy showed leukoencephalopathy. The original CT scan report did not indicate that calcifications were present, although we were unable to obtain that study for confirmation of this interpretation. We did not identify microcalcifications in the biopsy, but the tissue specimen was small. We hypothesize that the degree of these secondary reactive changes, which we consider to be calcification and Rosenthal fiber formation, may relate to the time course and severity of LCC.

Case 1 seems to be the first adult-onset patient reported with systemic signs that parallel those described in pediatric patients by Linnankivi et al (3) and Briggs et al (9). Case 1 presented at age 40 years and, over the course of the next 2 years, had cirrhosis and gastrointestinal symptoms that led to a biopsy of the colon, in which increased vascularity of the lamina propria was observed. The patient ultimately died of acute gastrointestinal bleeding, an occurrence that Briggs et al (9) emphasized in their report as a *life-threatening* risk for pediatric patients with this condition. Furthermore, unlike the previous late adult-onset cases, he had retinopathy at autopsy. Both Cases 1 and 3 also seemed, at least in part, to respond to steroid therapy.

The etiology of LCC/cerebroretinal microangiopathy with calcifications and cysts is not known. Wargon et al (7) speculated that LCC might belong in the same family as similar small-vessel disorders such as CADASIL, cerebral autosomal recessive arteriopathy with subcortical infarcts and leukoencephalopathy (10, 11), hereditary endotheliopathy with retinopathy, nephropathy, and stroke (12), and familial amyloid angiopathy (7). None of our cases had any features of amyloid angiopathy or CADASIL anywhere in the tissues, including the full autopsy examination in Case 1. Although all of these disorders share involvement of small-sized

vessels, each has an etiopathogenesis distinct from that of LCC. To date, all attempts to elucidate a thrombogenic, mitochondrial, or endocrinological cause for LCC have been unfruitful. No genetic information exists on any adult cases of this disorder, and hence, we cannot discern whether adult cases represent a single genetic condition or phenocopies. Briggs et al (9) speculated that because *FZD4*, *LRP5*, and *NDP* are genes involved in retinal vascular development, and because mutations in these genes can lead to several rare genetic disorders that also show retinopathy, these are possible candidate genes to explore in LCC/cerebroretinal microangiopathy with calcifications and cysts.

An additional clue to etiopathogenesis may be that the leukoencephalopathy seems to be intimately associated with and secondary to the vascular changes in the disorder, that is, the *diffuse cerebral microangiopathy* (1). Leukoencephalopathy is not necessarily a prerequisite to cyst development in association with vascular disorders in the brain, however. For example, in a report of 5 cases of parenchymal cystic changes that were discovered in the brain after review of CT or MRI studies on a large cohort of patients with cerebral aneurysms (13), all of the cysts were perianeurysmal. These patients had cysts that ranged from 1.5 to 3.5 cm in diameter; there were multiple clustered cysts in 3 patients, and they were associated with thrombosis and calcifications in 2 patients. Hemosiderin deposits were identified in association with the cyst(s) in only 1 of 5 of these patients, prompting the authors to speculate that “other mechanisms such as abnormal angiogenesis factors,” rather than previous hemorrhage, were the reason for the development of cysts (13). Whether “abnormal angiogenesis factors” play any role in LCC/cerebroretinal microangiopathy with calcifications and cysts awaits further studies.

#### ACKNOWLEDGMENTS

*Presented in part at the Sixteenth International Congress of Neuropathology, held September 10–15, 2006, in*

*San Francisco, CA. The authors thank Ms Lisa Litzenberger for photographic expertise and Dr Gary Mierau, PhD, for performing electron microscopy on Cases 2 and 3.*

#### REFERENCES

1. Labrune P, Lacroix C, Goutieres F, et al. Extensive brain calcifications, leukodystrophy, and formation of parenchymal cysts: A new progressive disorder due to diffuse cerebral microangiopathy. *Neurology* 1996;46:1297–301
2. Nagae-Poetscher LM, Bibat G, Philippart M, et al. Leukoencephalopathy, cerebral calcifications, and cysts. New observations. *Neurology* 2004;62:1206–9
3. Linnankivi T, Vallanne L, Paetau A, et al. Cerebroretinal microangiopathy with calcifications and cysts. *Neurology* 2006;67:1437–43
4. Crow YL, McMenamin J, Haenggeli CA, et al. Coats' plus: A progressive familial syndrome of bilateral Coats' disease, characteristic cerebral calcification, leukoencephalopathy, slow pre- and post-natal linear growth and defects of bone marrow and integument. *Neuropediatrics* 2003;35:10–19
5. Corboy JR, Gault J, Kleinschmidt-DeMasters BK. An adult case of leukoencephalopathy with intracranial calcifications and cysts. *Neurology* 2006;67:1890–92
6. Sener U, Zorlu Y, Men S, et al. Leukoencephalopathy, cerebral calcifications, and cysts. *AJNR Am J Neuroradiol* 2006;27:200–3
7. Wargon I, Lacour M-C, Adams D, Denier C. A small deep infarct revealing leukoencephalopathy, calcifications and cysts in an adult patient. *J Neurol Neurosurg Psychiatry* 2008;79:224–25
8. Brenner C, Del Negro MC, Borigato EMV, Miranda RV. Leukoencephalopathy with cerebral calcifications and cysts. *Neurology* 2006;66(9):E32
9. Briggs TA, Abdel-Salam GMH, Balicki M, et al. Cerebroretinal microangiopathy with calcifications and cysts (CRMCC). *Am J Med Genet* 2008;146A:182–90
10. Arima K, Yanagawa S, Ito N, Ikeda S. Cerebral arterial pathology of CADASIL and CARASIL (Maeda syndrome). *Neuropathology* 2003;23:327–34
11. Yanagawa S, Ito N, Arima K, Ikeda S. Cerebral autosomal recessive arteriopathy with subcortical infarcts and leukoencephalopathy. *Neurology* 2002;58:817–20
12. Jen J, Cohen AH, Yue Q, et al. Hereditary endotheliopathy with retinopathy, nephropathy, and stroke (HERNS). *Neurology* 1997;49:1322–30
13. Sato N, Sze G, Awad IA, et al. Parenchymal perianeurysmal cystic changes in the brain: Report of five cases. *Radiology* 2000;215:229–33