

Focal Capsular Vascular Lesions Can Selectively Deafferent the Prerolandic or the Parietal Cortex: Somatosensory Evoked Potentials Evidence

François Mauguière, MD,* and John E. Desmedt, MD†

Four patients with a unilateral focal vascular accident involving the internal capsule (but not the cortex) were studied electrophysiologically. Averaged somatosensory evoked potentials (SEPs) to electrical stimulation of the median nerve on the left or the right side were analyzed. In the 3 patients with hemiparesis and normal somatic sensation, the precentral P22 and N30 SEP components were lost, whereas the parietal components were preserved. In another patient with clinical somatosensory loss unaccompanied by any central motor impairment, the precentral SEP components were preserved, whereas the parietal SEP components were lost. Thus, a small capsular lesion can eliminate distinct cortical SEP components by selectively involving either the axons of the thalamic VPLc nucleus going to parietal receiving cortex or the axons of thalamic VPLo going to motor area 4. These findings extend to subcortical lesions the diagnostic value of SEPs in patients with dissociated clinical motor and sensory signs.

Mauguière F, Desmedt JE. Focal capsular vascular lesions can selectively deafferent the prerolandic or the parietal cortex: somatosensory evoked potentials evidence. *Ann Neurol* 1991;30:71-75

Averaged scalp somatosensory evoked potentials (SEPs) to median nerve stimulation reveal compound profiles [1-8] and their distinct short-latency components reflect evoked responses of either precentral (components P22, N30) or postcentral (N20, P27) cortical areas respectively because they undergo selective alterations or loss in patients with focal cortical lesions [9-12]. Persistence of the precentral P22-N30 SEP components after destruction of parietal cortex implies that these components can be activated directly through distinct projections [9] from the thalamic ventro-postero-lateralis pars oralis nucleus to motor area 4 [13-16] in the absence of parietofrontal connections. There is no evidence as to whether the thalamocortical fibers projecting respectively to either precentral or postcentral cortex are anatomically segregated in the internal capsule. In this report, we describe 4 patients in whom a small focal capsular lesion selectively involved one of these two sets of thalamocortical fibers. These results reveal (1) an anatomical segregation of thalamocortical somatosensory axons on their way to precentral or postcentral cortex and (2) the diag-

nostic value of SEPs in patients with subcortical lesions and dissociated clinical motor and sensory signs.

Methods

The extent of the focal lesion was documented by computed tomography (CT), nuclear magnetic resonance (NMR), or both. Clinical somatosensory deficits were carefully assessed at the time of SEP recording (see [8]). SEPs were evoked by 0.2-msec electrical pulses delivered to the right or to the left median nerve at the wrist (cathode located proximally, intensity adjusted to elicit a slight thumb twitch). Intervals between stimuli varied randomly between 500 and 600 msec. The proximal arm was grounded. Eight recording electrodes (impedance less than 5 k Ω) were placed bilaterally over the scalp. The afferent volley was monitored over the brachial plexus at Erb's point. The recording channels were referred to the earlobe. A system bandpass of 1.6 to 3,200 Hz and 136- μ sec bins (computer sampling time) were used for averaging. Throughout the recording session, the electroencephalogram (EEG) was monitored, and EEG samples with excess interference from muscles or eye blinks were automatically edited out from the average. SEP components were labeled for polarity (N for negative, P for positive) and modal peak

From the *Department of Electroencephalography and Epileptology, Faculty of Medicine Lyon-Nord, Hôpital Neurologique, Lyon, France, and the †Brain Research Unit, University of Brussels Faculty of Medicine, Brussels, Belgium.

Received Aug 20, 1990, and in revised form Dec 31. Accepted for publication Jan 7, 1991.

Address correspondence to Dr Desmedt, Brain Research Unit, 115 Boulevard de Waterloo, Brussels 1000, Belgium.

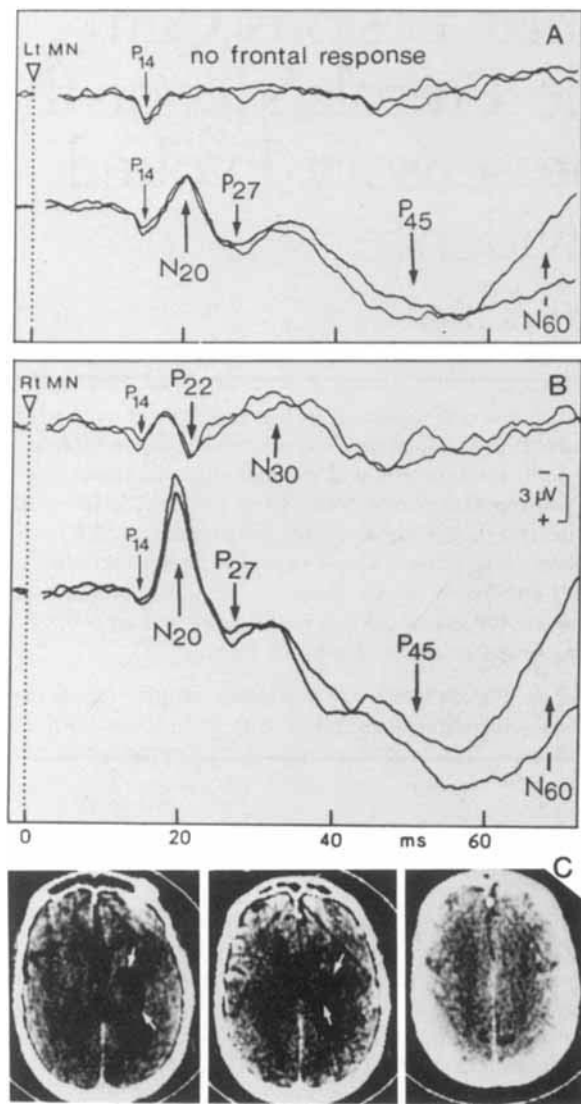


Fig 1. Patient 1; small hematoma in left internal capsule with no involvement of cortex. Somatosensory evoked potentials (SEPs) to stimulation of left (A) or right (B) median nerve at the wrist. For each frame, the upper traces present SEPs recorded at contralateral frontal scalp and the lower trace, SEPs at contralateral parietal scalp. SEP components are labeled. No cortical frontal response to stimulation on the affected side (A, upper trace). (C) Computed tomographic scans.

latency in normal adults of standard body size. Two averages of 2,000 trials each were compared for stimulation on either the left or the right side. Ethics committees approved the study and subjects gave informed consent.

Patient Reports

Patient 1

This 58-year-old right-handed woman presented with a sudden left hemiplegia with rotation of eyes and head to the right. Touch, joint, vibration, temperature sensations, as well as stereognosis were preserved on the left side. There was left tactile extinction on bilateral stimulation of the hands and

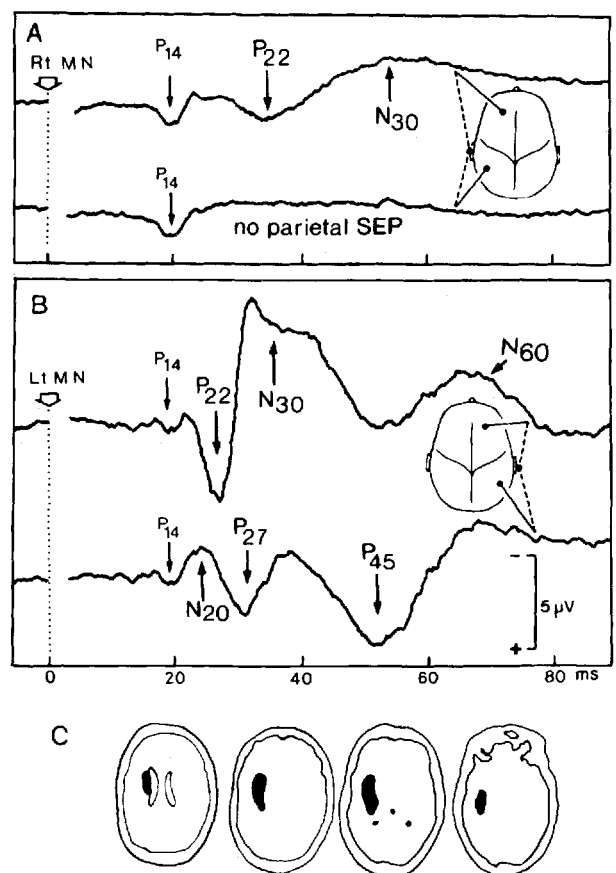


Fig 2. Patient 2; small hematoma in left internal capsule with no involvement of cortex. Somatosensory evoked potentials to stimulation of right (A) or left (B) median nerve at the wrist. Same presentation as Figure 1. No cortical parietal response to stimulation on the affected side (A, lower trace). (C) Drawings of computed tomographic scans.

left visual and auditory neglect. CT scans showed the integrity of the cerebral cortex including the rolandic regions, and a right capsular ischemic lesion in the anterior choroid artery territory (Fig 1C). SEPs were recorded 14 days after the vascular accident when the right hemiplegia was still severe.

SEPs to median nerve stimulation on the normal (right) side disclosed a P14 farfield and contralateral parietal N20, P27, P45, and N60 components, as well as precentral P22 and N30 components (Fig 1B). SEPs to median nerve stimulation on the affected (left) side showed normal P14 farfield, loss of precentral responses, and fairly preserved parietal N20, P27, P45, and N60.

Patient 2

This 57-year-old right-handed man suffered from untreated hypertension and presented with a sudden right hemiplegia with aphasia. CT scans showed a left capsular hematoma (Fig 2C). Clinical examination 1 month later disclosed a right brachiofacial anesthesia with loss of touch and joint sensations, astereognosis, and reduced vibration sensations. Motor aphasia and homonymous hemianopsia were present.

SEPs were recorded 2 years later when the blood pressure

had been stabilized through antihypertensive therapy. The neurological condition and verbal performance had improved to a small but significant extent, and there had been no clinical evidence for any progression of the cerebrovascular disease that has actually remained stable up to now. The right hemiplegia was still severe, and there was a right hemihypoesthesia for touch, joint, vibration, pain, and temperature. The right hand had a severe astereognosis as well as ataxia in the absence of visual control ("main instable ataxique" of Alajouanine [17]). Stimulation of the median nerve on the normal (left) side elicited normal SEPs with all classical components (Fig 2B). SEPs to stimulation of the median nerve on the affected (right) side showed loss of parietal responses, but persistence of a slowed and somewhat delayed precentral positivity, which was identified as P22. This was followed by a negativity identified as a frontal N30 (Fig 2A).

Patient 3

This 49-year-old right-handed woman woke up in the morning with a right hemiparesis, which regressed in about 3 months. Five years later, she presented after another accident of sudden onset with right hemiparesis and severe left cephalalgia. CT scans showed a left capsular hematoma (Fig 3C). Arteriography further disclosed a left caudate angioma. SEPs were recorded 1 month after the second episode at which time she had a right hemiparesis with hemihypoesthesia. Touch, joint, vibration, temperature, and pain sensations were clearly reduced but not lost on the right side. The right hand had astereognosis and impaired graphesthesia. SEPs to stimulation of the median nerve on the affected (right) side showed loss of precentral components and fairly preserved parietal responses (Fig 3A).

Patient 4

This 76-year-old right-handed man suddenly developed a right ataxic syndrome with unsteadiness of the right foot and clumsiness of the right hand (main instable ataxique [17]). At the time of SEP recording 9 days later, there was no hemiparesis nor any cerebellar sign. The tendon reflexes were symmetrical. All somatic sensations were normal. CT scans showed a small left capsulothalamic hematoma (Fig 4C) and NMR, 4 weeks later, disclosed residual hypersignal (Fig 4D). SEPs to stimulation of the median nerve on the affected (right) side showed loss of frontal responses and fairly preserved parietal response with slowed time course (Fig 4A).

Discussion

Distinct parietal and frontal short-latency SEP components have been disclosed in scalp topographical mapping [18–22], and critical evidence for either precentral or postcentral location of their neural generators relies essentially on their selective loss in neurological patients with well-defined focal lesions [9, 10]. The combined evidence suggests parietal generators located in area 3b for component N20 and in area 1 for P27, both components being lost in patients with a parietal lesion. In front of the central fissure, component P22 manifests a motor area 4 generator, whereas N30 appears to involve several generators that can presumably

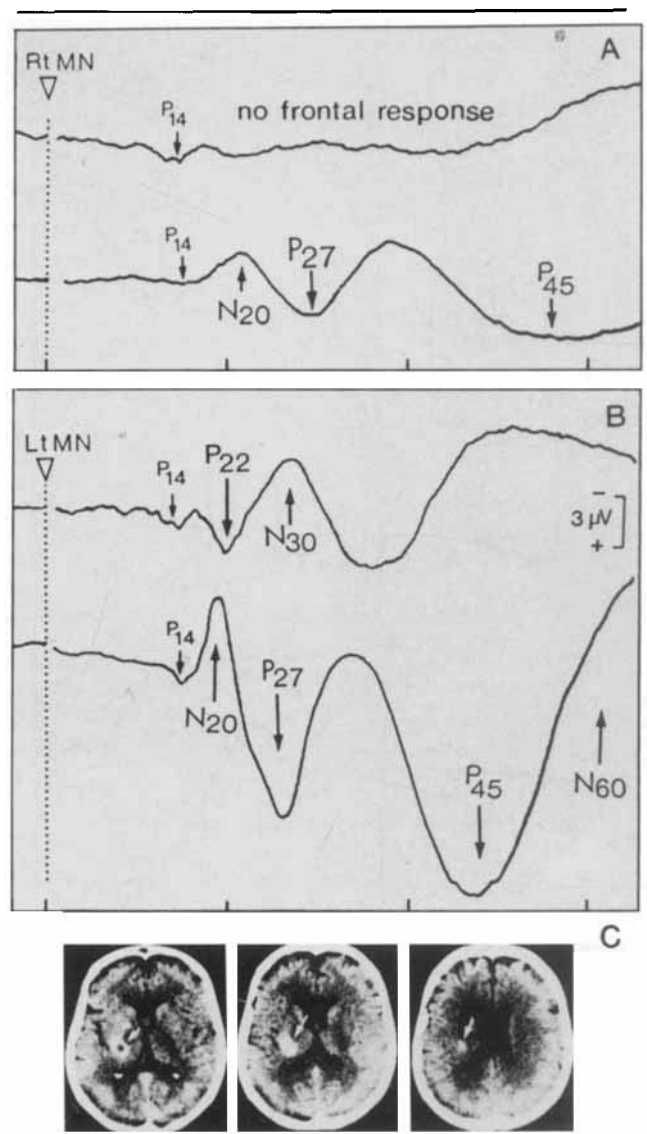


Fig 3. Patient 3; small hematoma in left internal capsule with no involvement of cortex. Same presentation as Figure 1. No cortical precentral response to stimulation on the affected side (A, upper trace). (C) Computed tomographic scans.

be located in premotor and supplementary motor areas because N30 persists after frontal lobectomy or postcentral lesions [9]. Motor area excitation plays a role in the activation of N30 through known corticocortical connections [23, 24]. When assessing N30 in patients, it should be remembered that this frontal component is vulnerable to short interstimulus intervals and also deteriorates rather early in chronological aging [5]. Therefore, it is desirable to compare the N30 elicited by right or left stimulation in patients with a unilateral lesion.

The present results help assess the clinical significance of the known corticocortical connections from parietal areas 1, 2, 5, and 7 to precentral areas 4 and

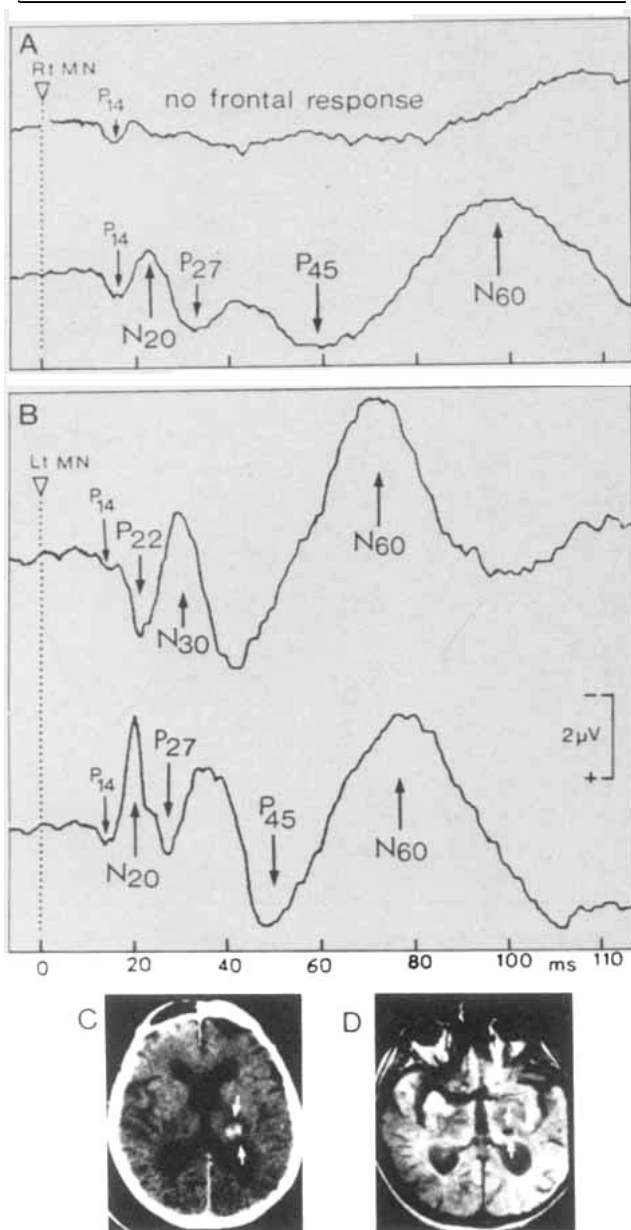


Fig 4. Patient 4; small hematoma in left internal capsule with no involvement of cortex. Same presentation as Figure 1. No cortical precentral response to stimulation on the affected side (A, upper trace). (C) Computed tomographic scan. (D) Nuclear magnetic resonance, 4 weeks later.

6 [15, 16, 23, 24]. In patients with a complete parietal lesion, these connections are lost, but the precentral P22 and N30 are still recorded, which suggests that these short-latency SEP responses are evoked, not by corticocortical connections from parietal cortex, but directly through thalamic projections from VPL_o to motor cortex [9]. The present results validate this interpretation by showing that precentral P22 and N30 can be lost in patients with a capsular lesion but intact precentral and postcentral cortex (Figs 1, 3, 4), in whom

the (preserved) parietofrontal connections indeed appear unable to elicit the short-latency precentral SEPs. We think that the function of these corticocortical connections is rather to mediate longer latency interactions such as manifested by P100 cognitive components [22].

The results also document an issue that had not been clarified in anatomical studies on primates, namely, whether the thalamocortical fibers projecting respectively to precentral or postcentral cortex might present any degree of anatomical segregation in their course through the internal capsule. We found that either of these two sets of fibers could be fairly selectively involved by a small subcortical vascular lesion. SEP evidence in our patients indicates that one set of fibers was blocked or lesioned resulting in the loss of the corresponding cortical SEP responses, whereas the other set of fibers still evoked fairly preserved cortical responses. In all patients except Patient 2, the anatomical integrity of the cortex could be documented by neuroimaging methods at the time of SEP recording. In Patient 2, the arterial pressure was stabilized by therapy and there had been no clinical evidence for any progression of the cerebrovascular disease during the delay of 2 years between CT scan and SEP recording. The clinical status of this patient has recently been found unchanged, 11 years after the vascular accident. Therefore, the loss of parietal SEP response and clinical hypoesthesia in Patient 2 can be assumed to reflect cortical deafferentation through a single subcortical lesion (capsular hematoma) inflicted during the acute episode.

Although the diagnostic value of SEPs in focal cortical lesions seems well established, their usefulness in capsular lesions had hitherto not been documented. Indeed, posterior thalamic or capsular lesions frequently result in the loss of all cortical SEPs [8, 25]. Our present data reveal the diagnostic value of SEPs for documenting dissociated clinical motor and sensory signs in patients with capsulothalamic lesions.

This research was supported by grants from the Faculty of Medicine Lyon-Nord of the University Claude Bernard and from the Belgian Fund for Medical Scientific Research.

References

- Noel P, Desmedt JE. Cerebral SEPs after vascular lesions of the brainstem and diencephalon. *Brain* 1975;98:113-128
- Green JB, McLeod S. Short-latency SEPs in patients with neurological lesions. *Arch Neurol* 1979;36:846-851
- Chiappa KH, Choi SK, Young RR. Short-latency SEPs following median nerve stimulation in patients with neurological lesions. In: Desmedt JE, ed. *Progress in clinical neurophysiology*, vol 7. Basel: Karger, 1980:264-281
- Anziska B, Cracco RQ. Short-latency SEPs to median nerve stimulation. *Electroenceph Clin Neurophysiol* 1981;52:531-539
- Desmedt JE, Cheron G. Noncephalic reference recording of

- early SEPs to finger stimulation in adult or aging man: differentiation of widespread N18 and contralateral N20 from pre-rolandic P22 and N30. *Electroencephalogr Clin Neurophysiol* 1981;52:553–570
6. Yamada T, Kimura J, Wilkinson JT, et al. Short- and long-latency median nerve SEPs. *Arch Neurol* 1983;40:215–220
 7. Lüders H, Lesser R, Hahn J, et al. Subcortical SEPs to median nerve stimulation. *Brain* 1983;106:341–372
 8. Mauguière F, Desmedt JE. Thalamic pain syndrome of Dejerine-Roussy. *Arch Neurol* 1988;45:1312–1320
 9. Mauguière F, Desmedt JE, Courjon J. Astereognosis and dissociated loss of frontal and parietal components of SEPs in hemispheric lesions. *Brain* 1983;106:271–311
 10. Slimp JC, Tamas LB, Stolov WC, et al. SEPs after removal of somatosensory cortex in man. *Electroencephalogr Clin Neurophysiol* 1986;65:111–117
 11. Tsuji S, Murai Y, Kadoya C. Topography of SEPs to median nerve stimulation in patients with cerebral lesions. *Electroencephalogr Clin Neurophysiol* 1988;71:280–288
 12. Ebner A, Deuschl G. Frontal and parietal components of enhanced SEPs. *Electroencephalogr Clin Neurophysiol* 1988;71:170–179
 13. Lemon RN, van der Burg J. Short-latency peripheral inputs to thalamic neurones projecting to the motor cortex in the monkey. *Exp Brain Res* 1979;36:445–462
 14. Tanji J, Wise SP. Submodality distribution in the sensorimotor cortex of the unanesthetized monkey. *J Neurophysiol* 1981;45:467–481
 15. Jones EG. The nature of afferent pathways conveying short-latency inputs to the primate motor cortex. In: Desmedt JE, ed. *Motor control in health and disease*. New York: Raven Press, 1983:263–285
 16. Mountcastle VB. Central nervous system mechanisms in mechanoreceptive sensibility. In: *Handbook of physiology, sect 1. The nervous system, vol 3*. Bethesda: American Physiological Society, 1984:789–878
 17. Alajouanine T, Thurel R, Ombredane A. Somatognosie et apraxie du membre supérieur gauche. *Rev Neurol (Paris)* 1934;41:695–703
 18. Desmedt JE, Bourguet M. Color imaging of scalp topography of parietal and frontal components of SEPs to stimulation of median or posterior tibial nerve in man. *Electroencephalogr Clin Neurophysiol* 1985;62:1–17
 19. Deiber MP, Giard MH, Mauguière F. Separate generators with distinct orientations for N20 and P22 SEPs to finger stimulation. *Electroencephalogr Clin Neurophysiol* 1986;65:321–334
 20. Desmedt JE, Nguyen TH, Bourguet M. Color imaging of human evoked potentials with reference to the N20, P22, P27 and N30 somatosensory responses. *Electroencephalogr Clin Neurophysiol* 1987;68:1–22
 21. Mauguière F, Desmedt JE. Bilateral SEPs in 4 patients with long-standing surgical hemispherectomy. *Ann Neurol* 1989;26:724–731
 22. Desmedt JE, Tomberg C. Mapping early SEPs in selective attention. *Electroencephalogr Clin Neurophysiol* 1989;74:321–346
 23. Jones EG, Powell TP. An anatomical study of convergent sensory pathways within the cerebral cortex of the monkey. *Brain* 1970;93:793–820
 24. Petrides M, Pandya DN. Projections to the frontal cortex from the posterior parietal region in the rhesus monkey. *J Comp Neurol* 1984;228:105–116
 25. Mauguière F, Desmedt JE, Courjon J. Neural generators of N18 and P14 farfield SEPs. *Electroencephalogr Clin Neurophysiol* 1983;56:283–292