

Electrophysiological characterisation of myoclonic-atonic seizures in symptomatic continuous spike-waves during slow sleep syndrome

Pascal Vrielynck^{1,2}, Pierre Defresne³

¹ Service de neurologie, Hôpital de Jolimont, Haine Saint-Paul, Belgium

² Centre neurologique William Lennox, Université Catholique de Louvain, Ottignies LLN, Belgium

³ Service de pédiatrie, Hôpital de Jolimont, Haine Saint-Paul, Belgium

Received February 19, 2008; Accepted February 17, 2009

ABSTRACT – Sudden epileptic falls are frequently reported in continuous spike-waves during slow sleep (CSWS) syndrome. Inhibitory seizures are usually considered as the underlying mechanism. However, published polygraphic recordings are rare. We report the case of a 22 month-old boy suffering from a symptomatic CSWS syndrome associated with a perinatal stroke involving the right middle cerebral artery territory. He presented with psychomotor regression and daily multiple falls related to myoclonic-atonic seizures. Neurophysiological examination showed secondary generalized myoclonus systematically correlated with a bilateral spike spreading from the right central area. This confirms that positive myoclonus, in addition to negative myoclonus, may be responsible for epileptic falls in CSWS syndrome. *[Published with video sequences]*

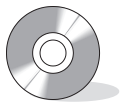Key words: epileptic falls, myoclonic-atonic seizures, continuous spike-waves during slow sleep, video-EEG

Epileptic falls are mainly observed in Lennox-Gastaut syndrome and epilepsy with myoclonic atonic seizure. They are also described in continuous spike-waves during slow sleep (CSWS) syndrome. CSWS is a well characterized age-dependant electro-clinical pattern associated with cognitive regression and variable seizure types including epileptic falls. These are found in up to 44.5% of cases (Tassinari *et al.* 2005), and negative myoclonus is usually considered the cause (Galanopoulou *et al.* 2000, Guerrini *et al.* 1998). Unfortunately

however, polygraphic studies are rare. We report the case of a 22 month-old boy presenting with symptomatic CSWS and daily multiple falls related to myoclonic-atonic seizures demonstrated by polygraphy.

Case report

The patient is a 22 month-old boy, born at term, after an uneventful pregnancy and delivery, with healthy parents and an unremarkable family history. After a few months, the parents



Correspondence:

P. Vrielynck
Service de neurologie,
Hôpital de Jolimont,
159 rue Ferrer,
7100 Haine-Saint-Paul,
Belgium
<vrielynckp@hotmail.com>

noticed a slight left motor asymmetry but no medical work-up was performed at this time. Independent walk was achieved at 18 months. At this time, he was able to speak a few words. When he was 22 months old, he was admitted to hospital because of unsteadiness, daily multiple (see video sequence 3) falls and language regression. Clinical examination revealed left hemiparesia predominating in the upper limb and a global developmental delay with autistic features. Cerebral MRI demonstrated a large stroke lesion in the right middle cerebral artery territory (figure 1).

Electrophysiological findings

A prolonged polygraphic examination was performed over 24 hours before treatment introduction, including video-EEG with 19 electrodes placed according to the 10-20 international system, and concomitant surface EMG recording of deltoid muscle activity. During wakefulness, abundant focal, high voltage, interictal diphasic spikes and spike waves were observed. Amplitude mapping showed tangential dipoles consistent with a right precentral generator, with a centrotemporal negativity and a frontal positivity. These interictal epileptic abnormalities were strongly activated during slow sleep, and then bilaterally spread from the right side to the left frontal area (figure 2). "Spike and wave index" (SWI), calculated in accordance with Galanopoulou *et al.* (2000), reached 72%. Neither tonic seizures nor

rapid rhythm discharges were noted during sleep. Sleep spindles were rarely present and were found lateralized to the left side.

Fourteen massive myoclonic jerks were recorded, only during wakefulness, mostly involving proximal muscles in the upper limbs (see video sequence 2). Deltoid EMG showed that they were either lateralized to the left or bilateral with asymmetry, occurring earlier on the left side (figure 3). While standing or sitting, a brief electromyographic silent period followed the positive myoclonus, associated with a sudden fall of the head and the whole body (see video sequence 1). This silent period was recorded on the deltoid EMG, and loss of tonus in the axial cervical musculature is suspected on the video. Duration of the myoclonic jerk measured between 110 and 180 ms, while the post myoclonic electromyographic silent period varied from 140 to 220 ms.

Myoclonic jerks were systematically time-locked to a bilateral high-voltage diphasic spike. Symptomatic "pre-myoclonic" spikes tend to spread more than asymptomatic ones and have greater amplitude, of more than 300 μ V (figure 4). The latency between the right centrotemporal spike and the contralateral homologous spike was constant, from 25 to 30 ms.

Follow-up

Treatment with sodium valproate, 20 mg/kg, was followed by a decrease in falls and EEG abnormalities. Levetiracetam,

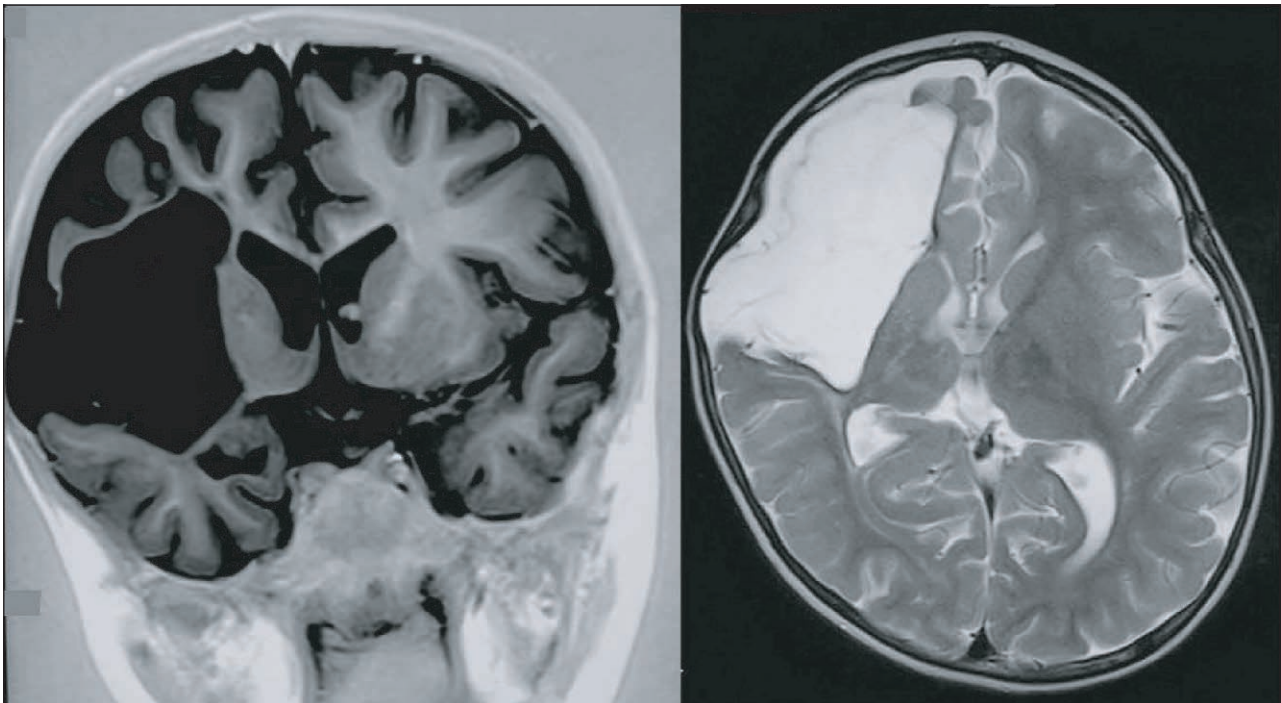


Figure 1. Cerebral MRI showing a large sequellar lesion in the right middle cerebral artery territory, sparing the thalamus.

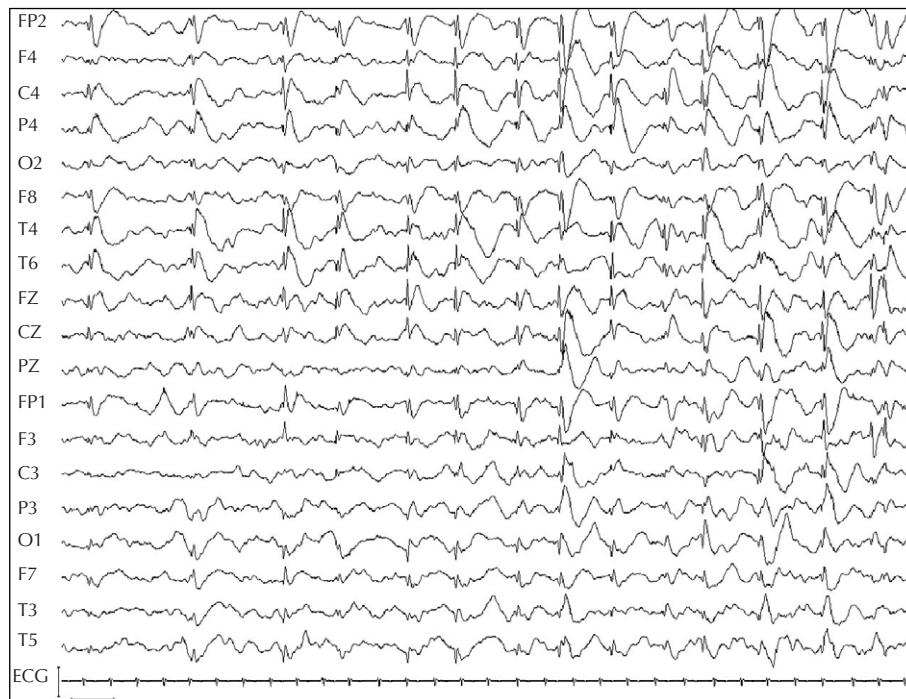

Figure 2. Sleep EEG before any treatment. Nearly continuous diffuse asymmetrical spike-waves, predominant on the right side (300 μ V, 1 sec).

40 mg/kg, was later added. Seizures disappeared and the EEG dramatically improved during sleep and wakefulness. Only sporadic right centrottemporal and left frontal spikes were noted during slow sleep. However, no improvement

in neurological development, language or autistic behaviour was noted to date, 8 months following treatment.

Discussion

The clinical history and EEG features of our patient support a diagnosis of CSWS syndrome. However, strict criteria according to the ILAE proposal (Engel 2001) are not fulfilled due to an asymmetric spike wave and a SWI below 85%. Moreover, it is difficult to clearly establish a cognitive deterioration, as classically described in this epileptic condition, in such a young child. The parents report the correct use of a few words between 12 and 20 months which disappeared thereafter. At the time of the first meeting, no more language was noticed and the boy presented autistic features.

Atypical benign partial epilepsy (ABPE) might also be considered on account of the similarity in electroclinical characteristics. Some authors (Dalla Bernardina *et al.* 2005) emphasize the nosological overlap between these entities in which a combination of genetic and lesional factors may be implicated. Indeed, in these epileptic syndromes, the abnormal electrical activity occurs during childhood and disappears during adolescence, testimony to the involvement of maturation factors. On the other hand, lesions involving the cortex or the thalamus are found in 30 to 60% of CSWS cases (Galanopoulou *et al.*

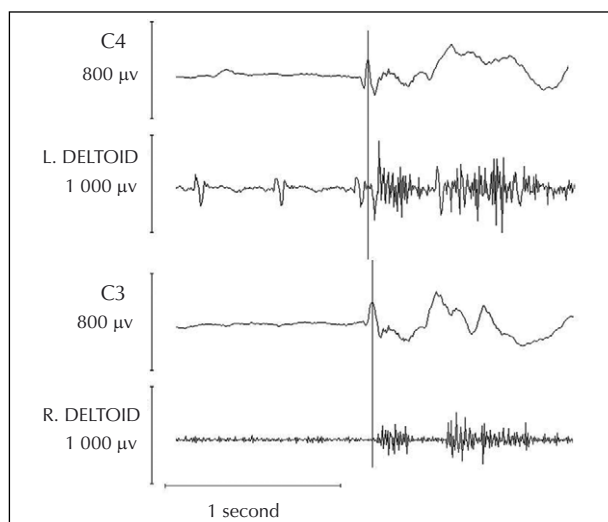


Figure 3. Secondary generalized epileptic myoclonus, followed by brief silent period. The onset of the myoclonus is time-locked to the peak of the negative spike on the contralateral central electrode. "Premyoclonic" spike and myoclonus are clearly asynchronous.

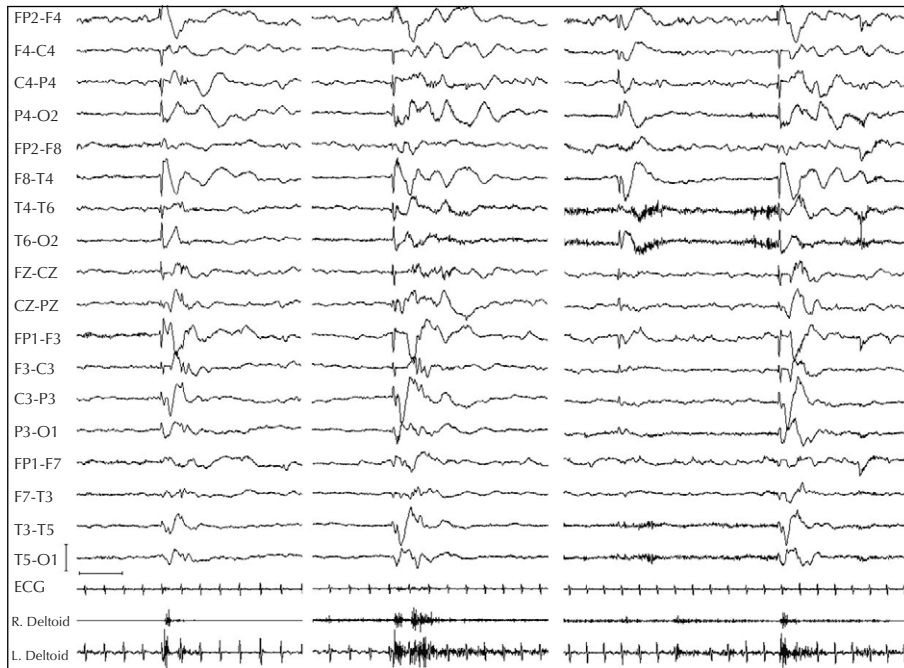


Figure 4. Awake EEG, no treatment. Three massive myoclonic jerks were recorded on deltoid EMG, correlating with the negative spike component of a bilateral spike and wave complex predominant on the right centrotemporal region (500 μ V, 1 sec). The third spike-wave discharge is asymptomatic.

2000) and are also described, although more rarely, in ABPE (Aicardi 2000). Congenital strokes, like that reported in the present case, represent a part of these reported neuroradiological abnormalities.

In these syndromes, several seizure types have been described: focal motor, tonic-clonic, atypical absences, and seizures with falls. Polygraphic studies analysing falls in CSWS and related syndromes are sparse. They consist mainly of drop attacks, attributed to negative myoclonus correlated with epileptic discharges, either the spike or the slow wave following the spike. Loss of muscular tone may be bilateral (Guerrini *et al.* 1998) or focal, involving a lower limb (Capovilla *et al.* 2000; Fernandez-Torre *et al.* 2004). de Saint-Martin *et al.* (2001) classified these brief inhibitory phenomena as "spike and wave related symptoms". Positive myoclonias were also published in a case report (de Saint-Martin *et al.* 1999), although involving only the face, without leading to a fall. Similar to the patient in the present study, symptomatic "interictal" spikes were characterized by greater amplitude than asymptomatic discharges.

Unlike these previous reports however, falls in the present case were provoked by positive massive bilateral myoclonic jerks and probably the subsequent brief atonia in deltoids and axial muscles of the neck and the trunk.

The falls are thus consistent with myoclonic-atonic seizures. Each myoclonus is induced by a bilateral asynchronous spike spreading from a right centrotemporal focus, with latency compatible with secondary bilateral synchrony. Deltoid EMG revealed that bilateral myoclonus was also asynchronous, with a constant leading side, consistent with secondary generalized myoclonus (Guerrini *et al.* 2005).

Falls related to myoclonic-atonic seizures have previously been reported in ABPE. In particular, Deonna *et al.* (1986) published a series of six children presenting myoclonic-astatic seizures and idiopathic partial epilepsy. However, this study and the two other ABPE main series contained no polygraphic recordings (Aicardi and Chevrie 1982, Hahn *et al.* 2001).

Atonia following myoclonus could be related to a post-myoclonic inhibition phenomenon, first described by Gastaut (1961). An active motor cortex inhibition related to the slow wave component of the epileptic discharge could also occur, previously suggested as the pathophysiological mechanism of negative myoclonus in ABPE (Parmeggiani *et al.* 2004).

In conclusion, this polygraphic study shows numerous epileptic falls in a child with symptomatic CSWS syndrome, related to massive myoclonic jerks and myoclonic-atonic seizures. The neurophysiological

Legends for video sequences

Video sequence 1. Myoclonic-atonic seizure while the child is sitting and playing, leading to unbalance. Polygraphic recording of this seizure is shown in figure 4, second picture.

Video sequence 2. Positive massive myoclonic jerk with left-side predominance, correlating with an asymmetrical bilateral spike and wave discharge.

Video sequence 3. Sudden fall associated with spike and wave discharge, not analysed with polygraphy. Consequently, the mechanism is unknown: negative or positive myoclonus, or perhaps a mixed phenomenon.

pattern is consistent with secondary generalized cortical myoclonus. This thereby confirms that positive myoclonus, as well as inhibitory seizures, may be responsible for the epileptic falls in CSWS syndrome. □

Acknowledgments.

We thank Dr Maria Paola Valenti and Prof. Edouard Hirsch for their helpful comments on the manuscript.

References

- Aicardi J, Chevrie JJ. Atypical benign partial epilepsy of childhood. *Dev Med Child Neurol* 1982; 24: 281-92.
- Aicardi J. Atypical semiology of rolandic epilepsy in some related syndromes. *Epileptic Disord* 2000; (Suppl. 1): 5-9.
- Capovilla G, Rubboli G, Beccaria F, et al. Intermittent falls and fecal incontinence as a manifestation of epileptic negative myoclonus in idiopathic partial epilepsy of childhood. *Neuropediatrics* 2000; 31: 273-5.
- Dalla Bernardina B, Sgro V, Fejerman N. Epilepsy with centro-temporal spikes and related syndrome. In: Roger J, Bureau M, Dravet C, Genton P, Tassinari CA, Wolf P, eds. *Epileptic syn-*

dromes in infancy, childhood and adolescence. London: John Libbey, 2005: 203-25.

Deonna T, Ziegler AL, Despland PA. Combined myoclonic-astatic and "benign" focal epilepsy of childhood ("atypical benign partial epilepsy of childhood"). A separate syndrome? *Neuropediatrics* 1986; 17: 144-51.

de Saint-Martin A, Petiau C, Massa R, et al. Idiopathic rolandic epilepsy with "interictal" facial myoclonia and oromotor deficit: a longitudinal EEG and PET study. *Epilepsia* 1999; 40: 614-20.

de Saint-Martin A, Carcangiu R, Arzimanoglou A, et al. Semiology of typical and atypical Rolandic epilepsy: a video-EEG analysis. *Epileptic Disord* 2001; 3: 173-82.

Engel J. A proposed diagnostic scheme for people with epileptic seizures and with epilepsy: Report of the ILAE task force on classification and terminology. *Epilepsia* 2001; 42: 796-803.

Fernandez-Torre JL, Otero B, et al. Epileptic negative myoclonus in a case of atypical benign partial epilepsy of childhood: a detailed video-polygraphic study. *Seizure* 2004; 13: 226-34.

Galanopoulou AS, Bojko A, Lado F, Moshe SL. The spectrum of neuropsychiatric abnormalities associated with electrical status epilepticus in sleep. *Brain Dev* 2000; 22: 279-95.

Gastaut H, Regis H. On the subject of Lennox's "akinetik" petit mal. *Epilepsia* 1961; 2: 298-305.

Guerrini R, Genton P, Bureau M, et al. Multilobar polymicrogyria, intractable drop attack seizures, and sleep-related electrical status epilepticus. *Neurology* 1998; 51: 504-12.

Guerrini R, Bonanni P, Parmeggiani L, et al. Pathophysiology of myoclonic epilepsies. *Adv Neurol* 2005; 95: 23-46.

Hahn A, Pistohl J, Neubauer BA, Stephani U. Atypical "benign" partial epilepsy or pseudo-Lennox syndrome. Part I: symptomatology and long-term prognosis. *Neuropediatrics* 2001; 32: 1-8.

Parmeggiani L, Seri S, Bonanni P, Guerrini R. Electrophysiological characterization of spontaneous and carbamazepine-induced epileptic negative myoclonus in benign childhood epilepsy with centro-temporal spikes. *Clin Neurophysiol* 2004; 115: 50-8.

Tassinari CA, Rubboli G, Volpi L, et al. Electrical Status Epilepticus during slow sleep (ESES or CSWS) including acquired epileptic aphasia (Landau-Kleffner syndrome). In: Roger J, Bureau M, Dravet C, Genton P, Tassinari CA, Wolf P, eds. *Epileptic syndromes in infancy, childhood and adolescence. 4th edition.* London: John Libbey, 2005: 295-314.