

Case Study: Biopercular lesions and acquired mutism in a young patient

Zeev Groswasser, Irith Groswasser-Reider & Cecilia Korn

To cite this article: Zeev Groswasser, Irith Groswasser-Reider & Cecilia Korn (1991) Case Study: Biopercular lesions and acquired mutism in a young patient, *Brain Injury*, 5:3, 331-334, DOI: [10.3109/02699059109008104](https://doi.org/10.3109/02699059109008104)

To link to this article: <http://dx.doi.org/10.3109/02699059109008104>



Published online: 03 Jul 2009.



Submit your article to this journal [↗](#)



Article views: 5



View related articles [↗](#)

Case study

Biopercular lesions and acquired mutism in a young patient

ZEEV GROSWASSER†, IRITH
GROSWASSER-REIDER‡ and CECILIA KORN†

†Loewenstein Rehabilitation Hospital Ra'anana and ‡Department of
Radiology/Section of Neuroradiology, Tel-Aviv Medical Center, Ichilov Hospital,
Sackler Faculty of Medicine, Tel-Aviv University, Israel

(Received 10 September 1990; accepted 18 October 1990)

A 13-year-old patient developed complete mutism and buccofacial apraxia following toxic vasculitis due to a yellow scorpion sting. Language functions were preserved. A CT scan disclosed mainly biopercular infarcts. It is suggested that the lost control of vocalization and speech is associated with biopercular lesions and that a preserved right opercular region can take over this function in the presence of damage to homologous left opercular region.

Introduction

The clinical phenomenon of long-standing mutism, defined as loss of vocalization and speech, without involvement of language functions, due to lesions in the central nervous system (CNS) has attracted considerable attention and has been described under many names [1-9].

Most of the reported patients acquiring the syndrome were middle-aged or older and had suffered from an underlying vascular disease. This paper reports a case of a 13-year-old patient who developed complete mutism with buccofacial apraxia (BFA) following vasculitis due to a toxic response to a scorpion bite, causing biopercular infarcts.

Case history

Patient presentation

A 13-year-old beduin boy was bitten by a yellow scorpion (*Leirus quinquestriatus*) on his left hand. On admission to hospital an hour and a half later, he was conscious but restless and showed multiple toxic manifestations including diffuse cold sweat, excessive salivation, vomiting, priapism and mydriasis. Blood pressure was 70/55. Therapy commenced immediately with diazepam, atropin and fluids. Soon after, his temperature rose to 39.5°C, he became unconscious and responded only to painful stimuli. Bilateral Babinski signs were noted and the patient developed pulmonary oedema and respiratory failure and had

Address correspondence to: Dr Z. Groswasser, Loewenstein Rehabilitation Hospital, PO Box 3, Ra'anana 43100, Israel.

to be intubated and artificially ventilated. Cardiogenic shock appeared due to ventricular tachycardia in spite of the prophylactic administration of lidocain. CT performed on the third day showed patchy areas of cortical damage. Consciousness recovered gradually on the fourth day and it became evident that the patient was unable to speak.

On the fifth hospital day, a demarcation line appeared 7 cm above his right ankle. Pulses were palpable at the right popliteal artery, but not below this level. Heparin was started but the foot became gangrenous and a below-knee amputation was performed on the 39th hospital day. Flexion contracture of the right knee developed in spite of intensive physiotherapy and the stump did not heal, therefore an above-knee reamputation was performed.

The patient was referred for rehabilitation during the 11th week of his illness. Physical examination was normal apart from the above-knee amputation on the right. On neurological examination he was conscious, alert and co-operative, obeyed commands but could not speak. Mild central palsy of the right facial nerve was noted; gag reflex was elicited on both sides. No other defects were found in the motor apparatus subserving speech production. The movements of the vocal cords were good. Some weakening of the right hand was found, but tendon reflexes were normal and symmetrical, pyramidal signs were negative. Sensation was normal and no extrapyramidal signs were found.

A CT scan performed at 4 months disclosed bilateral frontal opercular infarction around the territory of the prefrontal and insular branches of the middle cerebral arteries. Widened ventricles and subarachnoid spaces were also noted (Figure 1).

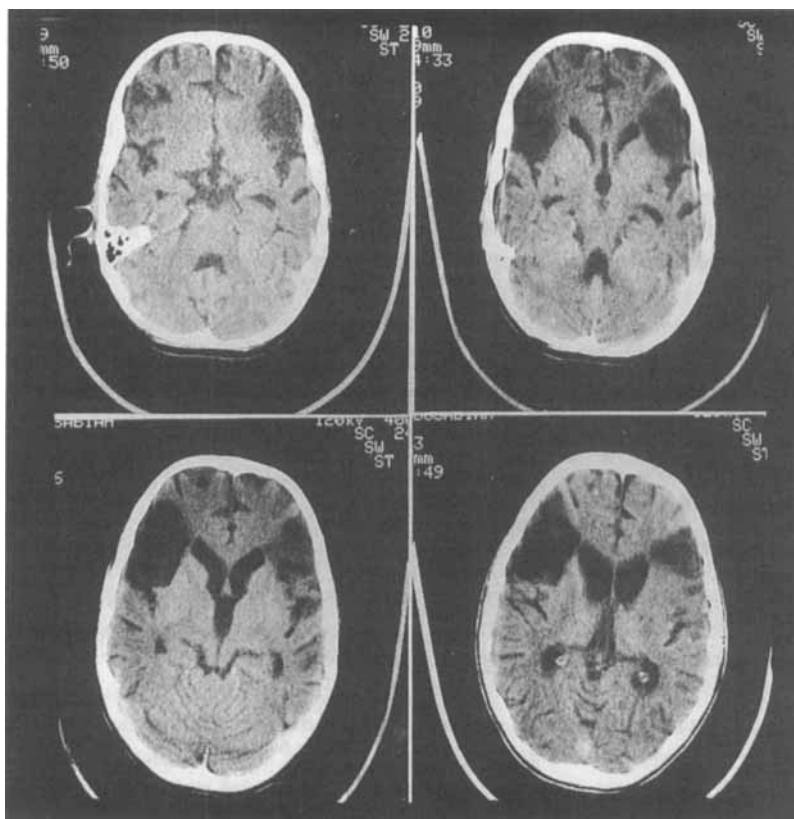


Figure 1. Bilateral frontal opercular infarcts in the territories of the insular and prefrontal branches of the middle cerebral arteries. Widened ventricles and subarachnoid spaces are noted.

Communication studies

The patient was mute, but his receptive functions were intact as evaluated on tests for aphasia, based on Eisenson's test and the Boston Aphasia test. The patient communicated effectively through gestures. His spontaneous orofacial movements were impaired in range, especially the lateral movements of the tongue. He was unable to perform any movement properly on command. He had swallowing difficulties and his co-ordination was impaired. Severe disturbances were found when tested for BFA according to Tognola and Vignolo [10].

The patient was followed for 6 months as an in-patient; improvement of his spontaneous tongue movements occurred, but his BFA did not change. On discharge, he was able to laugh, cough and produce a few isolated vowels. The patient's condition 2 years later had not improved.

Discussion

The phenomenon of lasting mutism associated with BFA following brain damage without any sign of language impairment are fairly rare and of considerable theoretical interest. Lecours *et al.* [11] assumed that it could be attributed to damage in a specific neuronal network which is functionally independent from the other cerebral systems underlying speech and language. The role of bilateral opercular lesions in the development of this specific clinical picture was clearly demonstrated by Cappa *et al.* [1], whose patient clearly showed that only the second infarction, affecting the homologous opercular region of the non-dominant right hemisphere, resulted in the clinical image of speechlessness and BFA without any signs of aphasia, similarly to patient F1 described by Groswasser *et al.* [4]. Both patients were initially described as aphasics whose aphasia resolved completely within a few weeks. Only the second stroke, affecting the non-dominant hemisphere, rendered them mute.

Our patient had several specific features. He is, as far as we know, the youngest patient ever reported to have acquired this syndrome having no underlying cardiovascular disease, which is the most common underlying disease [6]. The patient suffered from diffuse vasculitis and thrombotic phenomena as evidenced by brain infarcts in the territories of the pre-frontal and insular branches of the middle cerebral artery and in his right leg. The cardiovascular and autonomic disturbances following scorpion stings are well known but, to the best of our knowledge, diffuse vasculitis which led to the thrombosis of cerebral vessels, has not previously been reported.

The symmetrical bilateral involvement of the frontal operculum are responsible for the clinical picture of mutism and BFA in this patient. Patient F1 (described by Groswasser *et al.* [4]) and the patient described by Cappa *et al.* [1] demonstrate clearly the importance of the non-dominant right hemisphere in the development of a clinical picture identical to that of the present patient. The CT findings of these three patients are similar.

It therefore seems reasonable to assume that the permanent picture of mutism and BFA, without any other manifestations such as language impairment, may have developed in the present patient due to the homologous involvement of both opercular regions. The fact that the right frontal operculum was affected probably did not allow this region to take over successfully and efficiently the control of speech production, usually performed by the left hemisphere as was the case in the first stage of illness in the other two patients.

References

1. CAPPA, S. F., GUIDOTTI, M., PAPAGNO, C. *et al.*: Speechlessness with occasional vocalization after bilateral opercular lesions. *Aphasiology*, **1**: 35-39, 1987.

2. DAVID, A. S. and BONE, I.: Mutism following left hemisphere infarction. *Journal of Neurology, Neurosurgery and Psychiatry*, **47**: 1342–1344, 1984.
3. FOIX, C., CHAVANY, J. A. and MARIE, J.: Diplegie facio-linguo-masticatrice d'origin cortico-sous-cortical sans paralysis des membres. *Revue Neurologique*, **33**: 214–219, 1926.
4. GROSWASSER, Z., KORN, C., GROSWASSER-REIDER, I. *et al.*: Mutism associated with buccofacial apraxia and bihemispheric lesions. *Brain and Language*, **34**: 157–168, 1988.
5. MAO, C., COULL, B. M., GOLPER, L. A. *et al.*: Anterior opercular syndrome. *Neurology*, **39**: 1169–1172, 1989.
6. MARIANI, C., SPINNLER, H., STERZI, R. *et al.*: Bilateral perisylvian softening: Bilateral anterior opercular syndrome (Foix–Chavany–Marie Syndrome). *Journal of Neurology*, **223**: 269–284, 1980.
7. SCHIFF, H. B., ALEXANDER, M. P., NAESER, M. A. *et al.*: Aphemia: Clinical-anatomical correlations. *Archives of Neurology*, **40**: 720–727, 1983.
8. SUSSMAN, N. M., GUR, R., GUR, R. E. *et al.*: Mutism as a consequence of callosotomy. *Journal of Neurosurgery*, **59**: 514–519, 1983.
9. VON CRAMON, D.: Traumatic mutism and the subsequent organization of speech functions. *Neuropsychologia*, **19**: 801–805, 1981.
10. TOGNOLA, G. and VIGNOLO, L. A.: Brain lesions associated with oral apraxia in stroke patients: a clinico-neuro-radiological investigation with CT scans. *Neuropsychologia*, **18**: 257–272, 1980.
11. LECOIRS, A. R., ALI-CHERIF, A., DUDLEY, J. *et al.*: Articulatory and graphic disturbances in aphasia. In: A. R. Lecours, F. Lhermitte and B. Bryans (editors). *Aphasiology*. (Bailliere-Tindall, Eastbourne) pp. 57–75, 1983.