

FDG PET Brain Imaging in Neuropsychiatric Systemic Lupus Erythematosus With Choreic Symptoms

Martin Krakauer, MD, PhD,* and Ian Law, MD, PhD, DMSc†

Abstract: Chorea is a rare manifestation of neuropsychiatric systemic lupus erythematosus, and is probably caused by immune-mediated hypofunction of the contralateral striatum. Conventional imaging with brain computed tomography or magnetic resonance imaging often fails to show any structural lesions. We report a case of systemic lupus erythematosus-associated chorea in which brain F-18 fluorodeoxyglucose positron emission tomography imaging showed disturbances in striatal metabolism in the absence of structural damage on magnetic resonance imaging. A follow-up positron emission tomography scan showed normalization of striatal metabolism, which was correlated with clinical remission.

Key Words: PET, FDG, SLE, chorea

(*Clin Nucl Med* 2009;34: 122–123)

Received for publication July 22, 2008; accepted September 12, 2008.

From the *Department of Clinical Physiology and Nuclear Medicine and †The PET and Cyclotron Unit, Department of Clinical Physiology and Nuclear Medicine, Copenhagen University Hospital, Rigshospitalet, Copenhagen, Denmark.

Reprint: Martin Krakauer, Department of Clinical Physiology and Nuclear Medicine, KF 4011, Copenhagen University Hospital, Rigshospitalet, 9 Blegdamsvej, 2100 Copenhagen, Denmark. E-mail: martin.krakauer@rh.regionh.dk.

Copyright © 2009 by Lippincott Williams & Wilkins
ISSN: 0363-9762/09/3402-0122

REFERENCES

1. Minoshima S, Frey KA, Koeppe RA, et al. A diagnostic approach in Alzheimers-disease using 3-dimensional stereotaxic surface projections of fluorine-18-FDG PET. *J Nucl Med.* 1995;36:1238–1248.
2. Liang MH, Corzillius M, Bae SC, et al. The American College of Rheumatology nomenclature and case definitions for neuropsychiatric lupus syndromes. *Arthritis Rheum.* 1999;42:599–608.
3. Furie R, Ishikawa T, Dhawan V, et al. Alternating hemichorea in primary antiphospholipid syndrome—evidence for contralateral striatal hypermetabolism. *Neurology.* 1994;44:2197–2199.
4. Sundén-Cullberg J, Tedroff J, Aquilonius SM. Reversible chorea in primary antiphospholipid syndrome. *Mov Disord.* 1998;13:147–149.
5. Vela L, Sfakianakis GN, Heros D, et al. Chorea and contraceptives: case report with PET study and review of the literature. *Mov Disord.* 2004;19:349–352.
6. Wu SW, Graham B, Gelfand MJ, et al. Clinical and positron emission tomography findings of chorea associated with primary antiphospholipid antibody syndrome. *Mov Disord.* 2007;22:1813–1815.
7. Nordal EB, Nielsen J, Marhaug G. Chorea in juvenile primary antiphospholipid syndrome - Reversible decreased circulation in the basal ganglia visualised by single photon emission computed tomography. *Scand J Rheumatol.* 1999;28:324–327.
8. Kim JS, Lee KS, Lee KH, et al. Evidence of thalamic disinhibition in patients with hemichorea: semiquantitative analysis using SPECT. *J Neurol Neurosurg Psychiatry.* 2002;72:329–333.
9. DeLong MR. Primate models of movement disorders of basal ganglia origin. *Trends Neurosci.* 1990;13:281–285.

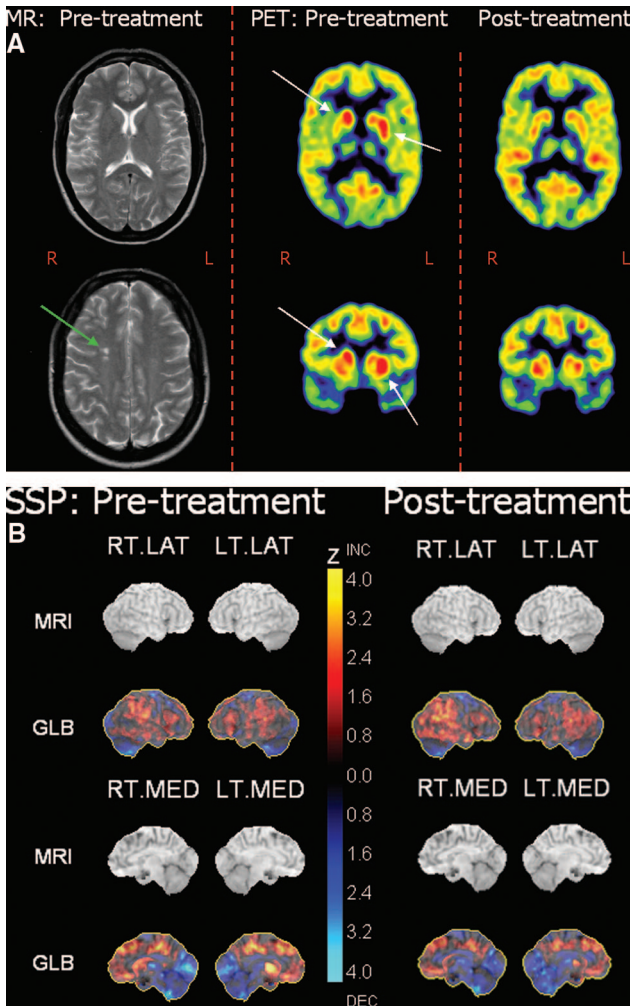


FIGURE 1. The patient, a 36-year-old white woman with systemic lupus erythematosus (SLE), developed involuntary movements in her right-sided extremities over a period of 3 months subsequently diagnosed clinically as hemichorea. Initial positron emission tomography (PET) images were acquired 40 minutes after intravenous injection of 233 MBq (6.3 mCi) F-18 fluorodeoxyglucose (FDG) on a GE Advance scanner. Follow-up PET images 5 months later were acquired with an identical protocol and 191 MBq (5.2 mCi) F-18 FDG. T2-weighted brain MRI with angio sequence was performed 3 days before the first PET scan and coregistered with the PET scans.

(A) Left column: pretreatment axial MR images showed no structural abnormalities in the basal ganglia or occipital cortex. A small lesion in the right parietal lobe (green arrow) consistent with a previous infarct was deemed irrelevant for the clinical symptoms. Middle column: Axial sections at the level of the basal ganglia (top) and coronal sections through the head of the caudate and anterior putamen (bottom). FDG PET images showed increased FDG activity in the left putamen and the right caudate nucleus (white arrows) before treatment. The patient was treated with cyclophosphamide and oral anticoagulants upon which the choreic symptoms remitted. Right column: A follow-up FDG PET brain examination 5 months later showed normalization of the metabolism in the basal ganglia. The axial MR and PET sections of the top row are coregistered.

(B) In addition to visual analysis, quantitative 3-dimensional stereotactic surface projection analysis (Neurostat) was employed.¹ Left column: Pretreatment. Right column: Post-treatment. The MR surface projections in the top rows (MRI) are presented for anatomic reference in a standard stereotactic space and do not belong to the patient. Images were normalized to global brain activity, using a database of normal subjects, and scaled to Z-values from -4.0 (cold color scale) to 4.0 (hot color scale).¹ Upper panels show projections of Z-values onto the right and left lateral hemispheric surfaces, respectively. Lower panels show projections of the right and left mesial hemispheric surfaces, respectively. Although this supplementary analysis is primarily designed for identification of cortical abnormalities, the presence of significant hypermetabolism in the left putamen and the right caudate nucleus could be discerned, as well as bilateral slight occipital and thalamic hypometabolism. All changes remitted at follow-up.

Chorea in SLE is a rare manifestation of neuropsychiatric SLE (NPSLE).² Studies have found changes in cerebral metabolism and/or blood-flow in patients with NPSLE, whereas NPSLE specifically with choreiform symptoms has been correlated with changes in the metabolism or perfusion in the contralateral striatum.³⁻⁸ Choreic syndromes are because of an imbalance in the inhibitory and excitatory basal ganglia-thalamocortical pathways, with a resulting disinhibition of the corticospinal motor pathways.⁹ The pathogenesis of chorea in SLE and primary antiphospholipid syndrome is undetermined. Hypotheses include vascular compromise (hypercoagulability, vasculitis, microinfarctions) and an immunologic attack on striatal tissues (antibodies, complement, cytotoxicity, blood-brain barrier leakage). In the present case, the increased FDG-uptake in the striatal nuclei may represent inflammatory activity and, consequently, decreased inhibitory activity in the contralateral striatum. The abnormal FDG uptake in the ipsilateral caudate nucleus, which is connected primarily to the right frontal cortex, may have been clinically silent or may have been causing more subtle cognitive or behavioral impairments.

This case demonstrates the clinical value of FDG PET brain imaging in neuropsychiatric SLE in the absence of relevant structural lesions on MRI. Stereotactic surface projection analysis provides a standardized quantitative measure of changes in gray matter metabolism.