



Acute bilateral thalamic infarction as a cause of acute dementia and hypophonia after occlusion of the artery of Percheron

Ephrosyni Koutsouraki ^{*}, Georgia Xiromerisiou ¹, Vassiliki Costa ², Stavros Baloyannis ³

1st Department of Neurology, Aristotelian University, School of Medicine, Agriteli 4, 55132, Thessaloniki, Greece

ARTICLE INFO

Available online 13 May 2009

Keywords:

Bilateral thalamic infarction
Artery of Percheron
Hypophonia
Memory dysfunction
Apathy

ABSTRACT

The thalami of the human brain obtain their blood supply from many perforating arteries, which exhibit complex distribution and many variations. One rare variation is the artery of Percheron that supplies the paramedian thalami bilaterally. This artery arises from the first segment of the posterior cerebral artery and gives rise to bilateral medial thalamic perforants. Occlusion of the artery of Percheron none rarely results in bilateral thalamic and mesencephalic infarctions.

We describe the case of a 38-year-old male patient with a presumed occlusion of this artery in which MR imaging revealed characteristic symmetrical bilateral paramedian thalamic infarctions. The unique characteristics of this case are based on the young age of the patient, the absence of any risk factors or other diseases and even more on the rare clinical manifestations consisted of hypophonia, memory dysfunction, time disorientation and apathy.

© 2009 Published by Elsevier B.V.

1. Introduction

Bilateral infarctions in the paramedian artery territory are very rare and may result in a variety of clinical presentations. Among the clinical manifestations disorientation, confusion, hypersomnolence, deep coma, akinetic mutism, amnesic syndrome and various neuropsychological phenomena have been described until now [1,2]. Speech and language dysfunctions such as dysarthric and aphasic disturbances, hypophonia and dysprosody may also be detected. Occlusion of the artery of Percheron, a solitary arterial trunk that arises from one of the proximal segments of the posterior cerebral artery and supplies the paramedian thalami and the rostral midbrain bilaterally results in these bilateral thalamic infarctions [3].

We attempted to describe the case of a patient with bilateral thalamic lesion due to ischemic stroke presenting with hypophonia, memory dysfunction, time disorientation and apathy.

2. Case report

A 38-year-old man, Professor of Physics, was admitted to the Department of Neurology of the University Hospital (AHEPA Hospital) in Thessaloniki, Greece, in a status of coma with Glasgow coma scale score of six which persisted for three hours. The neurological examination revealed skew deviation, constricted pupils and bilateral extensor plantar responses. There was no verbal response and no eye opening response but there were withdraws from pain. On the following period the level of consciousness elevated (Glasgow coma scale score of 13) but severe akinetic mutism lasted for three days. After that period the patient begun to talk but hypophonia was the main and permanent feature of his speech. Impairment of arousal with fluctuating level of consciousness was detected in the early stages lasting for a few days. Memory dysfunction, apathy, time orientation deficits and primitive reflexes like snout reflex and palmomental sign (Marinesco sign) were also elicited. Signs of pituitary failure were recorded a few days after his admission but the recovering was quick and spontaneous. During his hospitalization the patient recovered partially but the main clinical sign, namely the hypophonia persisted.

A neuroimaging protocol for stroke demonstrated symmetric bilateral hypo-density lesions in the thalami and symmetric bilateral hypertense thalamic lesions on diffuse-weighted MRI and fluid-attenuated inversion recovery (FLAIR) images, consistent with acute ischemic events and compatible with occlusion of the artery of Percheron (Fig. 1).

The large arteries of the posterior circulation, including the tip of the basilar artery, were fully patent as magnetic resonance

^{*} Corresponding author. Tel.: +30 2310 994604; fax: +30 2310 994711.

E-mail addresses: efrosin@hol.gr (E. Koutsouraki), geoksirom@med.uth.gr (G. Xiromerisiou), vcmg410@med.auth.gr (V. Costa), sibh844@otenet.gr (S. Baloyannis).

¹ Tel.: +30 2310 993309; fax: +30 2310 994711.

² Tel./fax: +30 2310 994712.

³ Tel.: +30 2310 994712; fax: +30 2310 994711.

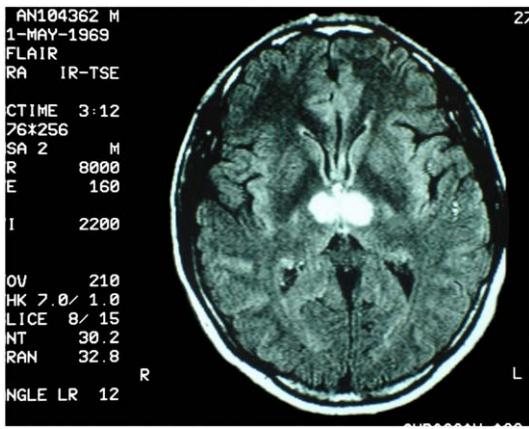


Fig. 1. Bilateral thalamic infarction involving the medial group of thalamic nuclei MRI (flair).

angiography revealed, which also advocated for an occlusion of the Percheron's artery (Fig. 2).

2D echocardiography, trans-oesophageal echocardiography, 24-hour electrocardiography (Holter) monitoring and intracranial and extracranial Doppler ultrasonography were normal.

Electroencephalographic recording in the initial phase showed diffuse theta (θ) and polymorphic delta (δ) activity, which after a few days was normalized.

Pro-coagulant screen for Factor V Leiden mutation was normal. Other inherited (such as protein C, S, AT III deficiency, prothrombin 20210 mutation, homocysteinemia and paroxysmal nocturnal haemoglobinuria) and acquired thrombophilias (anticardiolipin antibodies, anti-phospholipid antibodies, vasculitic screen, malignancy screen) were excluded.

The patient had no risk factors such as hypertension, diabetes mellitus, smoking, hypercholesterolemia or vasculitis.

The neuropsychological findings were evaluated in this patient with a series of standardized test instruments that quantitatively measured various cognitive functions, including language, spatial, frontal and memory functions. Mini Mental state examination (MMSE) was used to assess global cognitive dysfunction. Verbal amnesia was assessed by the Ray Auditory Verbal Learning test. After all these tests and the total clinical assessment of the patient, thalamic dementia was under a reasonable consideration. The main clinical phenomena which plead in favor of the diagnosis of thalamic dementia were the memory deficit, the lack of insight, the impairment of spontaneous activity, the slurred speech, the flattened emotional reactions, the frontal dysfunctions and a MMSE score below 18.

3. Discussion

Acute simultaneous bilateral thalamic infarcts in various vascular territories are uncommon as they represent over 0.6% of first ever acute ischemic stroke. The paramedian thalamic region is the most commonly affected location and usually the infarcts are asymmetrical [4,5]. Occlusion of the artery of Percheron results in bilateral medial thalamic and rostral mesencephalic infarctions with a relatively symmetrical distribution. So when bilateral medial thalamic infarcts are found, occlusion of the artery of Percheron should be considered as the main causative factor. Castaigne et al. stated that when the artery of Percheron is occluded, the thalamic infarcts are always bilateral and medial [6]. Performing conventional angiography may not be indicated because lack of visualization of the artery does not exclude its patency as well as its occlusion [7,8].

The cause of stroke in patients suffering from bilateral thalamic infarction is mainly a small artery disease and secondly an embolism from various emboligenic sources. The unique characteristics of this case were the young age of the patient, the absence of any risk factors and the inability to detect any obvious causative factor [9].

Thalamic dementia is a common clinical picture presented in patients with bilateral paramedian thalamic infarcts and is due to the

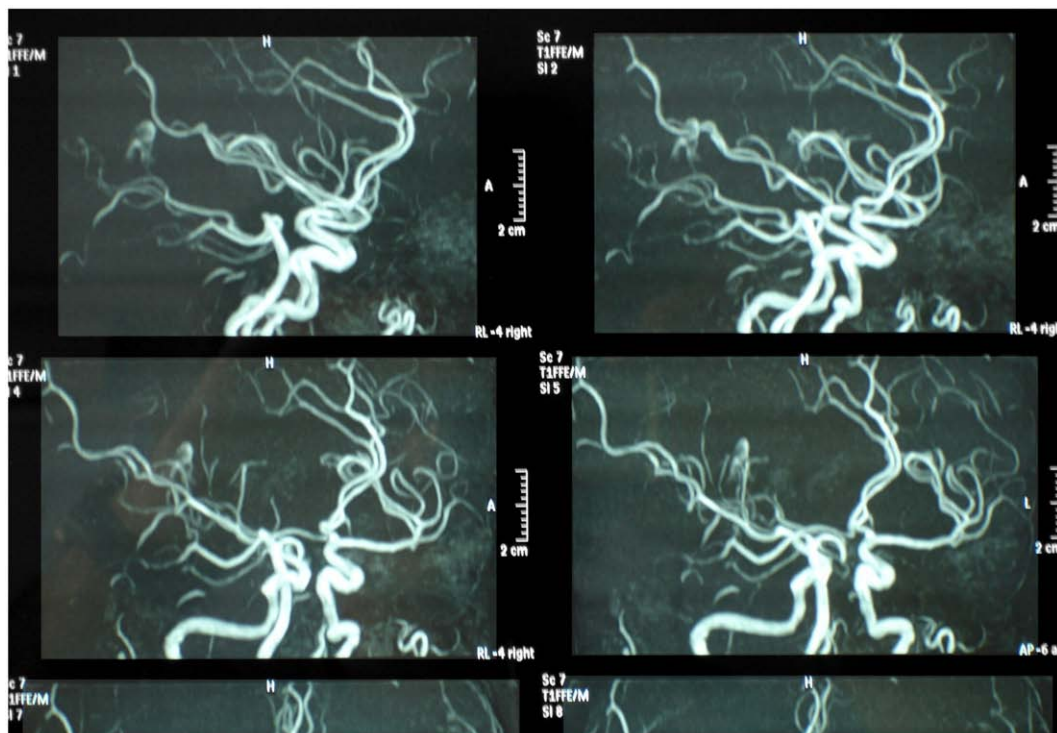


Fig. 2. MRI angiography revealing the occlusion of Percheron's artery although the distribution of the other arterial branches is unremarkable.

involvement of the mammillothalamic tract, the internal medullary lamina and the dorsomedial nucleus of the thalamus [10–13].

Loss of self activation that is revealed with apathy and no concern for the relatives or the illness is a result of lesion in the intralaminar nuclei which plays an important role in arousal and motivation [14–16].

Akinetic mutism is due to the interruption of the thalamo–fronto–limbic loop [17]. Hypophonia, without any dysphasic characteristics is a rare clinical sign. In the patient that we describe, the hypophonia persisted although the patient recovered partially and he tends to be improved. Nucleus dorsomedialis, nucleus anterior principalis, pulvinar and ventral nuclei group are supposed to be involved in hypophonia without any definite explanation for this [18].

The adynamic aphasia of Guberman and Stuss associated with hypophonia and dysprosody, reduced verbal fluency, preserved syntactic structure, but marked simplification of syntax, normal repetition but occasional paraphasic errors is a characteristic type of aphasia described in bilateral paramedian thalamic infarction [19]. The patient whom we describe has most of these characteristics. However the most impressive feature of his clinical manifestations is that the specific type of aphasia tended to be improved whereas the hypophonia persists and remains at the same level. The hypothesis of a functional deafferentiation of both thalami with the frontal lobe, leading to a disruption of the thalamo–frontal circuits that subserve the planning, organization and integration of linguistic information may be a possible interpretation of this type of aphasia.

References

- [1] Llinas R, Ribary U. Consciousness and the brain. The thalamocortical dialogue in health and disease. *Ann N Y Acad Sci* 2001;929:166–75.
- [2] Winocur G, Oxbury S, Roberts R, Agnetti V, Davis C. Amnesia in a patient with bilateral lesions to the thalamus. *Neuropsychologia* 1984;22:123–43.
- [3] Percheron G. The anatomy of the arterial supply of the human thalamus and its use for the interpretation of the thalamic vascular pathology. *Z Neurol* 1973;205:1–13.
- [4] Gentilini M, De Renzi E, Crisi G. Bilateral paramedian thalamic artery infarcts: report of eight cases. *J Neurol Neurosurg Psychiatry* 1987;50:900–9.
- [5] Krolak-Salmon P, Croisile B, Houzard C, Setiey A, Girard-Madoux P, Vighetto A. Total recovery after bilateral paramedian thalamic infarct. *Eur Neurol* 2000;44:216–8.
- [6] Castaigne P, Lhermitte F, Buge A, Escourrolle R, Hauw JJ, Lyon-Caen O. Paramedian thalamic and midbrain infarct: clinical and neuropathological study. *Ann Neurol* 1981;10:127–48.
- [7] Bewermeyer H, Dreesbach HA, Rackl A, Neveling M, Heiss WD. Presentation of bilateral thalamic infarction on CT, MRI and PET. *Neuroradiology* 1985;27:414–9.
- [8] Gerber O, Gudesblatt M. Bilateral paramedian thalamic infarctions: a CT study. *Neuroradiology* 1986;28:128–31.
- [9] Reilly M, Connolly S, Stack J, Martin EA, Hutchinson M. Bilateral paramedian thalamic infarction: a distinct but poorly recognized stroke syndrome. *Q J Med* 1992;82:63–70.
- [10] Hodges JR, McCarthy RA. Autobiographical amnesia resulting from bilateral paramedian thalamic infarction. A case study in cognitive neurobiology. *Brain* 1993;116(Pt 4):921–40.
- [11] Karussis D, Leker RR, Abramsky O. Cognitive dysfunction following thalamic stroke: a study of 16 cases and review of the literature. *J Neurol Sci* 2000;172:25–9.
- [12] Malamut BL, Graff-Radford N, Chawluk J, Grossman RI, Gur RC. Memory in a case of bilateral thalamic infarction. *Neurology* 1992;42:163–9.
- [13] von Cramon DY, Hebel N, Schuri U. A contribution to the anatomical basis of thalamic amnesia. *Brain* 1985;108(Pt 4):993–1008.
- [14] Bogousslavsky J, Regli F, Assal G. The syndrome of unilateral tuberthalamic artery territory infarction. *Stroke* 1986;17:434–41.
- [15] Bogousslavsky J, Regli F, Uske A. Thalamic infarcts: clinical syndromes, etiology, and prognosis. *Neurology* 1988;38:837–48.
- [16] Bogousslavsky J, Regli F, Delaloye B, Delaloye-Bischof A, Assal G, Uske A. Loss of psychic self-activation with bithalamic infarction. Neurobehavioural, CT, MRI and SPECT correlates. *Acta Neurol Scand* 1991;83:309–16.
- [17] van Domburg PH, ten Donkelaar HJ, Notermans SL. Akinetic mutism with bithalamic infarction. Neurophysiological correlates. *J Neurol Sci* 1996;139:58–65.
- [18] Lazzarino LG, Nicolai A. Aponia as the only speech disturbance from bilateral paramedian thalamic infarction. *Clin Neurol Neurosurg* 1988;90:265–7.
- [19] Guberman A, Stuss D. The syndrome of bilateral paramedian thalamic infarction. *Neurology* 1983;33:540–6.