

## LETTER TO THE EDITOR

**Hemiballismus in subthalamic haemorrhage: efficacy of levetiracetam**

P. Marchione, C. Vento, M. Marianetti, T. Romeo, G. A. Amabile and P. Giacomini

*Department of Neurology and Otolaryngology, University of Rome 'La Sapienza', Rome, Italy*

Correspondence: Pasquale Marchione, Viale dell'Università 30, 00185 Rome, Italy (tel.: +39649914502; fax: +3964454294; e-mail: pasquale.marchione@uniroma1.it).

Received 14 October 2006

Accepted 28 December 2006

Sir,

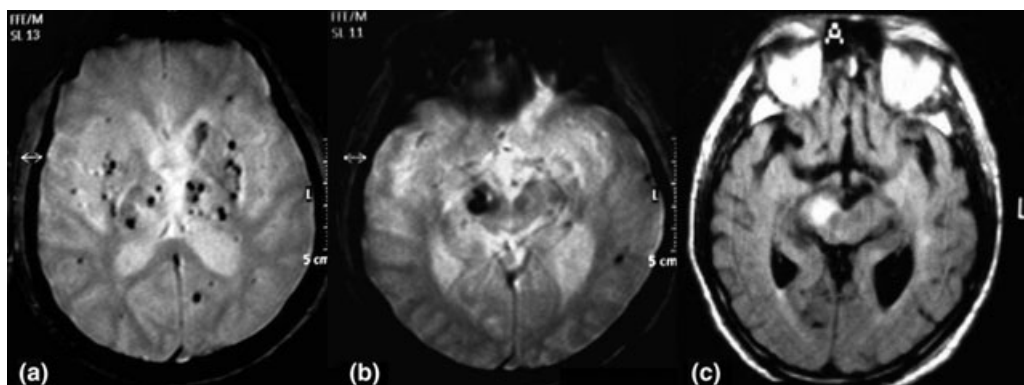
A 65-year-old man with uncontrolled hypertension presented with severe ataxia, dizziness and vomiting in January 2005. Magnetic resonance imaging (MRI) brain showed a hyperintense haemorrhagic lesion in the cerebellar vermis on T2-weighted images (Fig. 1a) and heterogeneous 'popcorn-like' lesions with a mixed signal core in fast field echo sequences, which were consistent with multiple cavernous angiomas (Fig. 1b). As cavernous angiomas are typically occult at angiography, digital subtraction angiography was deemed unnecessary. Upon admission, high arterial blood pressure values (ABP, mean values 210/110 mmHg) were rapidly controlled with quinalapril 20 mg/day and hydrochlorothiazide 25 mg/day. Full blood count, erythrocyte sedimentation rate, serum electrolytes, routine autoantibodies, glycaemia, liver and kidney function tests were within normal limits. Three days after admission, the patient presented with two consecutive

episodes of severe vomiting and marked increase in ABP (200/100 mmHg) followed by sudden onset of severe involuntary, forceful flailing and wide movements in the left arm and leg. Large, prevalently proximal, vigorous and 'kicking' movements were subcontinuously present during the waking hours, enhanced by voluntary movement of the involved limb and reduced or absent during sleep. A second MRI brain showed a markedly hyperintense haemorrhagic area in fluid attenuated inversion recovery (FLAIR) and T2-weighted images in the right subthalamic nucleus (STN, Fig. 1c). A diagnosis of hemiballismus related to subthalamic haemorrhage was considered. The patient was treated with haloperidol (8 mg/day) and lorazepam (5 mg/day), which led to a rapid improvement in the involuntary movements over a few days and an increasing degree of sedation and stiffness. Treatment was thus discontinued after 1 week; although rigidity and somnolence remitted rapidly, involuntary movements relapsed at 2-week evaluation. Levetiracetam (LEV) was started at a dosage of 125 mg twice daily and increased by 125 mg every week. A significant improvement in the hemiballismus was observed at 4 weeks (1000 mg), followed by complete remission when a final dose of 2000 mg/day was reached. At the 3-month follow-up, LEV was decreased by 125 mg per week to assess a possible long-term spontaneous improvement. As hemiballismus relapsed after a reduction of 1000 mg, LEV dosage was again raised to the previous dose with subsequent improve of involuntary movements.

**Discussion**

Hemiballismus is a relatively rare neurological disorder, usually caused by

destructive lesions of the contralateral STN, whose long-term prognosis is considered non-specific and related to aetiologic pattern of hemiballismus [1,2]. Nevertheless, its persistence requires pharmacologic therapy with benzodiazepines, antipsychotic and/or antiepileptic drugs [1]. The severity of involuntary movements and the absence of spontaneous improvement in our patient required a pharmacological approach, though the classical treatment was associated with severe side effects. Recent reports described the efficacy of LEV in the treatment of vascular hemichorea [3]. Despite LEV is well tolerated, a slow titration was preferred to avoid the somnolence, appearing more often at a higher dosage. The decreased STN inhibitory control of both globus pallidus (GP) and thalamus may disinhibit the excitatory pathways to the motor cortex, which in turn results in hemiballistic movements [1]. The antihyperkinetic activity of LEV is probably to be due to the desynchronization of abnormal neuronal firing patterns related to partial inhibition of N-type voltage-gated calcium channels and/or to suppression of negative allosteric modulation of gamma-aminobutyric acid (GABA) receptors that may restore GABA inhibition in GP pathway to thalamus [4]. Recently, synaptic vesicle protein (SV2A) has been identified as a possible binding site of LEV which could lead to neural transmission modulation that influences the activity of the STN [5]. To our knowledge, this is the first reported case of a significant improvement in vascular hemiballismus following treatment with LEV, highlighting the role of this drug in the treatment of hyperkinetic movement disorders.



**Figure 1** (a) Axial fast field echo (FFE) image showing multiple cavernomas. (b) Axial fluid attenuated inversion recovery (FLAIR) image of pre-haemorrhagic subthalamic nucleus. (c) Axial FLAIR image with hyperintense haemorrhagic lesion at subthalamic level.

**References**

1. Fahn S. Hypokinesia and hyperkinesia. In: Goetz CG, ed. *Textbook of Clinical Neurology*, 2nd edn. Amsterdam, Netherlands: Elsevier, 2003: 476–490.
2. Ristic A, Marinkovic J, Dragasevic N, Stanisavlejevic D, Kostic V. Long-term prognosis of vascular hemiballismus. *Stroke* 2002; **33**: 2109–2115.
3. D'Amelio M, Callari G, Gammino M, *et al.* Levetiracetam in the treatment of vascular chorea: a case report. *Eur J Clin Pharmacol* 2005; **60**: 835–836.
4. Rigo JM, Hans G, Nguyen L, *et al.* The anti-epileptic drug levetiracetam reverses the inhibition by negative allosteric modulators of neuronal GABA- and glycine-gated currents. *Br J Pharmacol* 2002; **136**: 659–672.
5. Lynch BA, Lambeng N, Nocka K, *et al.* The synaptic vesicle protein SV2A is the binding site for the antiepileptic drug levetiracetam. *Proc Natl Acad Sci USA* 2004; **101**: 9861–9866.