

Retinal Artery Embolization During Carotid Angioplasty and Carotid Artery Stenting

—Case Report—

Hiroyuki YAMASAKI, Shunji MATSUBARA*,
Isao SASAKI, and Shinji NAGAHIRO*

Department of Neurosurgery, Mizunomiyako Hospital, Tokushima;

**Department of Neurosurgery, The University of Tokushima Faculty of Medicine, Tokushima*

Abstract

A 69-year-old man presented with a rare case of retinal artery embolization, which occurred as a complication of carotid angioplasty and carotid artery stenting performed for recurrent cerebral infarction. Magnetic resonance imaging and angiography showed right internal carotid artery stenosis with ulceration. Carotid angioplasty and carotid artery stenting were performed using the distal protection system with the PercuSurge GuardWire. However, just after dilation, the patient complained of ocular pain and blurred vision on the right, which was subsequently diagnosed as retinal artery embolization. Heparin was given for 15 hours after stenting, and aspirin and ticlopidine medication were continued. The patient received hyperbaric oxygen therapy for 1 week. The patient's blurred vision gradually improved, but visual field defect remained. Debris was probably flushed into the external carotid artery, and passed through an anastomosis into the ophthalmic artery, resulting in retinal artery embolization.

Key words: retinal artery embolization, carotid angioplasty and carotid artery stenting, anastomosis, lacrimal artery, middle meningeal artery

Introduction

Percutaneous transluminal carotid angioplasty and carotid artery stenting (CAS) is an attractive treatment alternative to carotid endarterectomy for the treatment of severe carotid artery bifurcation stenosis. CAS does not require general anesthesia and is less traumatic, so could be especially advantageous for use in high-risk patients with medical comorbidities or high risk anatomic characteristics, as well as in the elderly. The complications of CAS include puncture site hematoma, carotid artery spasm,²⁾ transient bradycardia, hypotension,⁹⁾ transient cerebral ischemia, transient seizures or loss of consciousness, and minor embolic stroke. Major complications are uncommon and include carotid artery dissection, perforation, acute thrombosis, cerebral hemorrhage, major embolic stroke, and intraventricular hemorrhage.⁵⁾

We present a rare case of a patient who suffered

ocular pain and blurred vision during CAS, which was subsequently diagnosed as retinal artery embolization.

Case Report

A 69-year-old man with dysarthria and left hemiparesis was admitted to our hospital. Diffusion-weighted magnetic resonance (MR) imaging showed multiple new infarctions in the right hemisphere. MR angiography indicated moderate cervical internal carotid artery (ICA) stenosis at the right carotid bifurcation. The patient refused conventional angiography. The patient was treated conservatively with ozagrel and edaravone, and was then discharged with aspirin medication and followed up as an outpatient. One month after discharge, the patient again presented with dysarthria. Diffusion-weighted MR imaging on admission showed multiple additional new infarctions in the right

Received October 1, 2007; Accepted January 15, 2009

Author's present address: Hiroyuki Yamasaki, M.D., Department of Neurosurgery, Kajikawa Hospital, Hiroshima, Hiroshima, Japan.

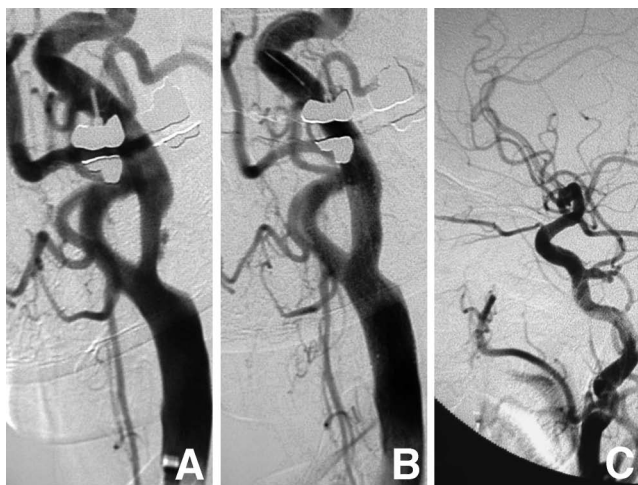


Fig. 1 A: Right common carotid angiogram showing an approximately 65% stenosis with ulceration based on the North American Symptomatic Carotid Endarterectomy Trial method. B: Post-stenting right carotid angiogram showing decreased stenosis and disappearance of the ulceration. C: Pre-operative right carotid angiogram showing that the right ophthalmic artery is chiefly perfused through the ipsilateral internal carotid artery.

hemisphere, and MR angiography showed that the right cervical ICA stenosis had not progressed. At first, the patient was again treated conservatively. Based on the North American Symptomatic Carotid Endarterectomy Trial method, conventional angiography revealed a 65% right ICA stenosis with ulceration, and the ophthalmic artery perfused by the ipsilateral ICA (Fig. 1A, C).

CAS was performed 45 days after the second admission. A 6F Shuttle sheath (Cook, Bloomington, Ind., U.S.A.) was introduced into the common femoral artery and advanced to the common carotid artery (CCA). Lateral, anteroposterior, and bilateral oblique angiograms were obtained via the Shuttle sheath. The PercuSurge GuardWire (Medtronic Inc., Minneapolis, Minn., U.S.A.) was then advanced into the distal ICA and inflated to occlude antegrade flow after a 1-minute occlusion test indicated tolerance. Heparin was given to maintain the activated clotting time above 250 seconds. The ICA stenosis was predilated with a 4.5 mm \times 3.0 cm Amia angioplasty balloon (Cordis, Johnson & Johnson, Miami, Fla., U.S.A.) (10 atm \times 30 sec). A 10 mm \times 4.0 cm PROTAGE self-expandable stent (ev3 Inc., North Plymouth, Minn., U.S.A.) was deployed across the lesion with the proximal end in the CCA. A 4.5 mm \times 3.0 cm Amia angioplasty balloon was used for

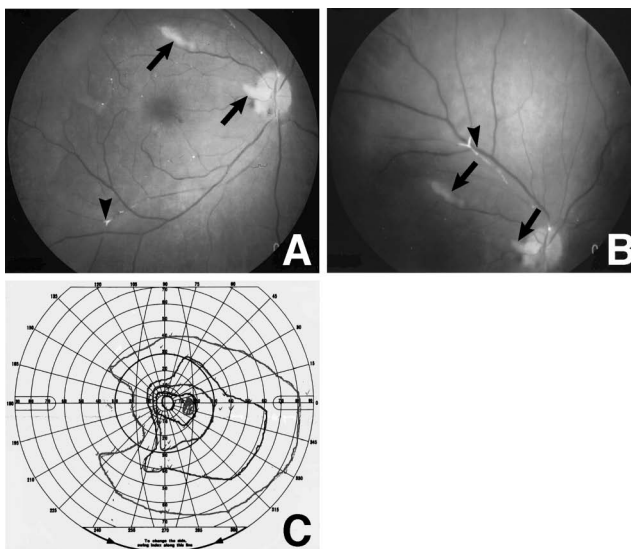


Fig. 2 A, B: Right fundus photographs showing white arterioles (arrowheads) that are not perfused and many white spots (arrows), including the optic disc. C: Visual field test showing a defect in the medial visual field of the right eye.

post-stent dilation (10 atm \times 30 sec). After predilation, stenting, and postdilation were completed, about 30 ml of blood was aspirated using a Thrombuster III (Kaneka Medix, Osaka), and the remaining debris was flushed away toward the external carotid artery (ECA) using 20 ml of 50% contrast medium and 40 ml of saline. At each step, the GuardWire was deflated. A low to moderate volume of debris was aspirated, but not more than usual. Just after the flushing following the post-stent dilation, the patient started to complain of right ocular pain, blurred vision, and absence of medial visual field. His symptoms improved gradually, so we did not administer urokinase. Post-stent intracranial angiography showed successful stenting (Fig. 1B) and no abnormalities of the arteries, including the ophthalmic artery.

Heparin administration was continued for 15 hours after stenting, and the patient continued to take aspirin and ticlopidine. The patient received hyperbaric oxygen therapy for 1 week. His blurred vision improved gradually but the visual field loss did not resolve completely. An ophthalmologist later diagnosed right retinal artery branch occlusion. Right fundus photography showed white arterioles that were not perfused, and many white spots affecting the optic disc (Fig. 2A, B). Visual field examination revealed a deficit in the medial visual field of the right eye (Fig. 2C). The patient was discharged

home with no other neurological deficit.

Discussion

The human orbit is mainly supplied by the ophthalmic artery, with minor contributions from the infraorbital artery and the orbital branch of the middle meningeal artery (MMA) that arises from the internal maxillary artery.^{4,7)} Anastomoses are located between the recurrent branch of the lacrimal artery and the orbital branch of the MMA. Variations can be classified by origin, intraorbital course of the ophthalmic artery, and contribution of the MMA. Therefore, flushing debris towards the ECA carries the risk of retinal embolization through the orbital branch of the MMA, especially if the contribution of the MMA to the blood supply of the ophthalmic artery is high. Even if anastomoses from the MMA are not opacified on conventional angiography, obliteration of the ICA due to an occlusion balloon may change the blood flow, resulting in the debris passing through the anastomoses.

Retinal artery embolization during CAS is a very rare but serious complication that can lead to partial or total blindness. Retinal artery embolization during CAS was reported in 6 of 118 patients (5%), 2 of whom were symptomatic (1.7%).¹³⁾ Emboli occurred in 5 of 38 patients (13.2%) in whom the Theron system¹⁰⁾ was used, and in 1 of 80 patients (1.25%) in whom the PercuSurge system was used. Debris is aspirated with blood through a guide catheter with the Theron system, whereas an aspiration catheter is used with the PercuSurge system. Consequently, the remaining debris is flushed towards the ECA with the Theron system, but not with the PercuSurge system. Retinal artery embolization could occur either due to embolic flow through anastomotic pathways between the ECA and ICA, or by the escape of material trapped in the stagnant segment of the ICA during reflow after deflation of the protection balloon.¹³⁾

We routinely flush debris away towards the ECA using saline mixed with 50% contrast medium and only saline after blood suction using an aspiration catheter, because we think that an aspiration catheter cannot remove all of the debris, especially debris located close to the distal occlusion balloon. The GuardWire balloon had to be positioned more distally than usual during this procedure due to the tortuosity of the ICA. Thus, we could not confirm whether the aspiration catheter was close enough to the GuardWire balloon, and we suspect that more debris than usual remained near the balloon, which may have increased the risk of retinal artery embolization. Since the ICA was not opacified in the

present patient when debris was flushed away towards the ECA using 50% contrast medium, and the patient complained of ocular pain and blurred vision just after flushing but prior to GuardWire deflation, we presume that the responsible debris passed through an anastomosis between the ICA and the ECA, rather than through antegrade flow. The present patient is the only case of retinal embolism among our 170 patients treated with CAS.

Acute onset visual loss always requires urgent ophthalmologic consultation. Treatment needs to be started as soon as possible to maximize the chance of restoring normal vision. Several cases of retinal artery embolization have occurred incidentally during interventional treatment.^{1,3,6,8,11,12)} Various treatments, including conservative therapy, were used in these cases, but the success rate was very low. The lack of a safe and effective treatment for retinal embolization is reflected by the variety of reported management options for retinal artery occlusion, which are intended either to reduce intraocular pressure or to attempt to dislodge or reduce the embolus. Ocular massage can reduce intraocular pressure, and increase retinal arterial flow through vasodilation. Furthermore, ocular massage may mechanically facilitate the disintegration of thrombus or dislodge embolus into a more peripheral part of the retinal circulation. In the present case, ocular massage was not performed because his symptom was improving, and bradycardia and hypotension should be avoided. The present patient was left with a minor visual field defect and an uncomfortable feeling in the eye. Following the procedure, the patient was given heparin concomitantly with aspirin and ticlopidine, as well as hyperbaric oxygen therapy, and his visual symptoms gradually recovered over 1 month.

Retinal artery embolization is a very serious complication of CAS that cannot be ignored. To decrease or avoid the risk of retinal embolization and to decrease the amount of debris remaining prior to balloon deflation, we think that the volume of aspirated blood should be increased, and the need to flush away debris needs to be assessed.

References

- 1) Ashwin PT, Mirza S, Ajithkumar N, Tsaloumas MD: Iatrogenic central retinal artery occlusion during treatment for epistaxis. *Br J Ophthalmol* 91: 122-123, 2007
- 2) Cardaioli P, Giordan M, Panfill M, Chioin R: Complication with an embolic protection device during carotid angioplasty. *Catheter Cardiovasc Interv* 62: 234-236, 2004

- 3) Castillo B Jr, De Alba F, Thornton J, DeBrun G, Pulido J: Retinal artery occlusion following coil embolization of carotid-ophthalmic aneurysms. *Arch Ophthalmol* 118: 851-852, 2000
- 4) Hayreh SS: Orbital vascular anatomy. *Eye* 20: 1130-1144, 2006
- 5) Krajickove D, Krajina A, Nove M, Raupach J: Fatal intraventricular hemorrhage after the extracranial carotid artery angioplasty and stent placement. *Cardiovasc Intervent Radiol* 28: 502-505, 2005
- 6) Kunikata H, Tamai M: Cilioretinal artery occlusions following embolization of an artery to an intracranial meningioma. *Graefes Arch Clin Exp Ophthalmol* 244: 401-403, 2006
- 7) Liu QL, Rhoton AL Jr: Middle meningeal origin of ophthalmic artery. *Neurosurgery* 49: 401-407, 2001
- 8) Önerci M, Gumus K, Cil B, Eldem B: A rare complication of embolization in juvenile nasopharyngeal angiofibroma. *Int J Pediatr Otorhinolaryngol* 69: 423-428, 2005
- 9) Pappadà G, Beghi E, Marina R, Agostoni E, Cesana C, Legnani F, Parolin M, Petri D, Sganzerla EP: Hemodynamic instability after extracranial carotid stenting. *Acta Neurochir (Wien)* 148: 639-645, 2006
- 10) Théron J, Courteoux P, Alachpar F, Bouvard G, Maiza D: New triple coaxial catheter system for carotid angioplasty with cerebral protection. *AJNR Am J Neuroradiol* 11: 869-874, 1990
- 11) Turner T, Trobe JD, Deveikis JP: Sequential branch retinal artery occlusions following embolization of an intracranial meningioma. *Arch Ophthalmol* 120: 857-860, 2002
- 12) Wen F, Chen XM, Liao RD: Branch retinal artery occlusion after thyroid artery interventional embolization. *Am J Ophthalmol* 129: 690-691, 2000
- 13) Wilentz JR, Chati Z, Krafft V, Amor M: Retinal embolization during carotid angioplasty and stenting: mechanisms and role of cerebral protection systems. *Catheter Cardiovasc Interv* 56: 320-327, 2002

Address reprint requests to: Hiroyuki Yamasaki, M.D.,
Department of Neurosurgery, Kajikawa Hospital,
8-20 Shouwa-machi, Naka-ku, Hiroshima,
Hiroshima 730-0046, Japan.
e-mail: d-45hx_shanqi@ya2.so-net.ne.jp