





Disponible en ligne sur
 ScienceDirect
www.sciencedirect.com

Elsevier Masson France
 EM|consulte
www.em-consulte.com



ORIGINAL ARTICLE / ARTICLE ORIGINAL

Prognostic role of somatosensory and auditory evoked potentials in paediatric hypoxic-ischemic encephalopathy managed with hypothermia: An illustrative case

Un cas illustratif de la valeur pronostique des potentiels évoqués somesthésiques et auditifs dans l'encéphalopathie anoxo-ischémique traitée par hypothermie

A. Suppiej*, A. Cappellari, P.E. Cogo

Department of paediatrics, university of Padova, via Giustiniani, 3, 35100 Padova, Italy

Received 4 July 2008; accepted 22 February 2009
Available online 17 March 2009

KEYWORDS

Postanoxic coma;
Somatosensory evoked potentials;
Mismatch negativity;
Children;
EEG;
Prognosis

Summary

Introduction. – The contribution of clinical neurophysiology in the neurological prognosis of hypoxic-ischemic coma has been well established in adults: the bilateral absence of cortical somatosensory evoked potentials (SEP) is considered the single best indicator of adverse outcome, while the presence of the auditory mismatch negativity (MMN) is thought to herald arousal.

Study aim. – To use MMN combined with serial EEG recordings, somatosensory and brainstem auditory evoked potentials (BAEP) in a paediatric case of postanoxic coma managed with hypothermia, since they have not yet been described in children.

Methods. – We report the case of a nine-year-old boy with hypoxic-ischemic encephalopathy due to cardiorespiratory arrest after accidental burial in sand, who was treated with therapeutic hypothermia for 72 hours. Serial EEG recordings, evoked potentials, brain CT scan and brain MRI were performed in the first few days after the event.

Results. – SEP to median nerve stimulation showed bilateral absence of the N20 component, while the N13 and P14 peaks were preserved; BAEP showed normal I–V interpeak latency and normal hearing threshold. At the same time, the MMN component of auditory event related potentials, recorded in the classical oddball paradigm, was absent. Seventeen months after the accident, the patient is alive in persistent vegetative state.

* Corresponding author.

E-mail address: suppiej@pediatria.unipd.it (A. Suppiej).

MOTS CLÉS

Coma postanoxique ;
Potentiels évoqués
somesthésiques ;
Négativité de
discordance ;
Enfants ;
EEG ;
Pronostic

Conclusions. – This case illustrates the particular significance of SEP and MMN together with EEG in gaining prognostic information, even in sedated and hypothermic patients, and encourages systematic study of these prognostic tools in paediatric postanoxic coma.

© 2009 Elsevier Masson SAS. All rights reserved.

Résumé

Introduction. – L'apport de la neurophysiologie clinique dans le pronostic neurologique du coma postanoxique est bien établi chez l'adulte : l'absence bilatérale des composantes corticales des potentiels évoqués somesthésiques (PES) constituent le meilleur indicateur individuel d'un mauvais pronostic alors que la présence de la négativité de discordance (mismatch negativity [MMN]) annonce un éveil imminent.

But de l'étude. – L'utilisation conjointe de la MMN, d'enregistrements EEG répétés, des PES et des potentiels auditifs du tronc cérébral (PEAT) n'a jusqu'ici pas été décrite chez l'enfant.

Méthodes. – Nous rapportons le cas d'un enfant de neuf ans victime d'une encéphalopathie hypoxique ischémique due à un enterrement accidentel dans le sable, traité par hypothermie durant 72 heures. Des enregistrements répétés de l'EEG et des potentiels évoqués, un scanner et une IRM cérébrale furent réalisés dès le premier jour après l'accident.

Résultats. – Les PES des nerfs médians montrent une absence bilatérale d'onde N20, les ondes N13 et P14 étant conservées, les PEAT montrent un intervalle I–V et des seuils normaux. La MMN, obtenue au moyen d'un paradigme oddball classique, est absente. Dix-sept mois après l'accident, le patient est toujours en vie mais dans un état végétatif.

Conclusions. – Ce cas démontre que les PES et la MMN enregistrés conjointement à l'EEG gardent une valeur pronostique, même chez les patients sous sédation et hypothermie. Il constitue un encouragement à une étude systématique de ces instruments pronostiques dans l'encéphalopathie hypoxique ischémique de l'enfant.

© 2009 Elsevier Masson SAS. Tous droits réservés.

Introduction

The clinical contribution of evoked potentials (EP) in the neurological prognosis of coma has been well established in adults: the bilateral absence of cortical somatosensory evoked potentials (SEP) is considered the single best indicator of adverse outcome [1] while the presence of the mismatch negativity (MMN) component of the auditory event-related potentials (AERP) is thought to herald arousal [2–4].

In Paediatric Intensive Care Units, EP are not well-established techniques and to the best of our knowledge, there are no reports on the role of MMN in paediatric coma. The aetiology of coma in children is heterogeneous, and previous studies have mainly dealt with a small number of cases, pooling together different ages and aetiologies. Multimodal neurophysiological techniques (SEP, Brainstem Auditory Evoked Potentials [BAEP], EEG monitoring) have been described in children with coma from mixed aetiologies, and results show that neurophysiology is more accurate than the Glasgow Scale (GCS), and that the combination of different methods gives better results than a single method. Few studies report on the role of SEP in post-traumatic coma [5] and even fewer deal specifically with paediatric postanoxic coma [6]. Taken together, these studies suggest that the absence of cortical SEP result in death or persistent vegetative state with a positive predictive value approaching 100%, while the role of BAEP and visual evoked potentials is less clear [7].

Hypothermia has recently become an established treatment in adults and children in order to reduce the brain damage related to a hypoxic-ischemic insult [8]. The effect of hypothermia on EEG and EP and the role of EP in monitor-

ing the efficacy of treatment have not been systematically studied in children.

The aim of this study is to describe the prognostic role of neurophysiological techniques, particularly SEP and MMN, combined with EEG, in a child affected by postanoxic coma and treated with hypothermia.

Patient and methods

Approval for the retrospective case-note review was obtained from our Institution Ethical Committee.

We report on a nine-year-old boy with hypoxic-ischemic encephalopathy due to cardiorespiratory arrest after accidental burial in sand. It was assumed that the cardiac arrest had lasted about 30 minutes. The child was found with a GCS of 3 and with mydriatic pupils sluggishly reactive to light. He was resuscitated, intubated, ventilated, and transferred immediately to the Paediatric Intensive Care Unit, Department of Paediatrics, University of Padova, Italy.

On admission, his clinical parameters were the following: rectal temperature 34.5°C, arterial blood pressure 107/53 mmHg, heart rate 112 b/min, O₂ saturation 100% on synchronized intermittent mechanical ventilation with FiO₂ 31%. His pupils were miotic and reactive to light, and the GCS was 5. The brain CT scan, performed two hours after admission, did not show any signs of cerebral oedema. The patient was initially sedated with fentanyl (1 mcg/kg per hour) and midazolam (0.1 mg/kg per hour) and mannitol therapy was given because of the severe asphyxia. It was decided to monitor the intracranial pressure and to start therapeutic hypothermia with a cooling blanket, with a core temperature ranging from 32.5 to 34.5°C for 72 hours [8].

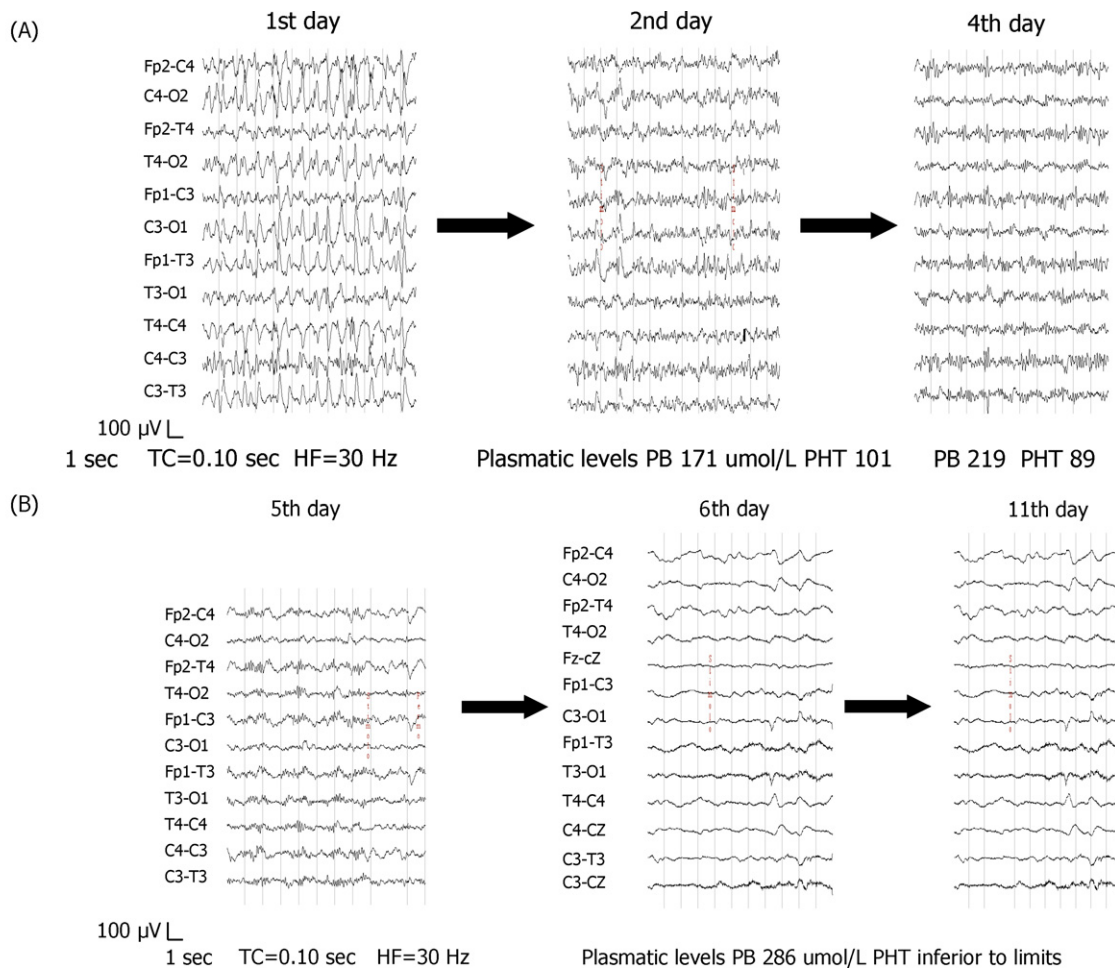


Figure 1 The EEG carried out on day 1, 2, 4 and in the first 13 days after the event. On Day1, there is massive generalized spiking with subtle but consistent bilateral central regions accentuation; there was no clinical motor correlate. During the course of therapeutic hypothermia (days 2 and 4), the EEG was characterized by an alpha-theta coma pattern consisting of non-reactive, diffuse, continuous rhythms in the 6–9 Hz frequency band, but by Day6, although levels of antiepileptic drugs were within the therapeutic range, a progressive slowing and flattening occurred. Fp1, Fp2, T3, T4, C3, C4, O1, O2: locations by International 10–20 System; PB: Phenobarbital; PHT: phenytoin.

Meanwhile the patient presented continuous generalized tonic clonic seizures. At this time, the EEG was not available, and he was treated with lorazepam (0.1 mg/kg i.v.), phenytoin (15 mg/kg i.v.) and phenobarbital (18 mg/kg i.v.) with clinical remission. An 8-channel EEG record using silver chloride disk electrodes placed at the standard scalp sites according to the 10–20 International System, was started a few hours later; it showed an ictal pattern characterized by massive generalized spiking with subtle but consistent bilateral central region accentuation, but there were no clinical motor manifestations (Fig. 1, 1st day). Remission was achieved following treatment with lorazepam (0.1 mg/kg i.v.), phenytoin (20 mg/kg i.v.) and phenobarbital (20 mg/kg i.v.). The antiepileptic treatment was then continued with phenytoin (7 mg/kg per day) and phenobarbital (10 mg/kg per day). The EEG was repeatedly performed in the course of follow-up treatment. On Day 2, during the course of therapeutic hypothermia, his state was characterized by an alpha-theta coma pattern consisting of non-reactive, diffuse, continuous rhythms in the 6–9 Hz frequency band

(Fig. 1, 2nd day). By Day 6, although the levels of antiepileptic drugs were within the therapeutic range, a progressive slowing and flattening of the background activity occurred (Fig. 1). SEP to median nerve stimulation, performed on Day 7, showed bilateral absence of the N20 component (Fig. 2). At that time, the patient was treated with phenytoin 7 mg/kg per day and phenobarbital 8 mg/kg per day. BAEP, carried out on Day 12, showed normal I-V inter-peak latency and normal hearing threshold. The MMN component of AERP recorded in the classical oddball paradigm [9] was absent on Day 13. The anti-epileptic drugs were stopped one and two days before BAEP and MMN recordings, respectively; the plasmatic level of phenobarbital was within the therapeutic range, and that of phenytoin was at the lower limits of the range. The brain CT scan on Day6 showed diffuse cerebral oedema and hypodensity of the basal ganglia; the magnetic resonance imaging demonstrated signs of severe hypoxic-ischemic insult with hyperintense signal in the T2 sequences at a diffuse cortical level, thalamus, and basal ganglia. On Day8, a brain CT scan was repeated and the

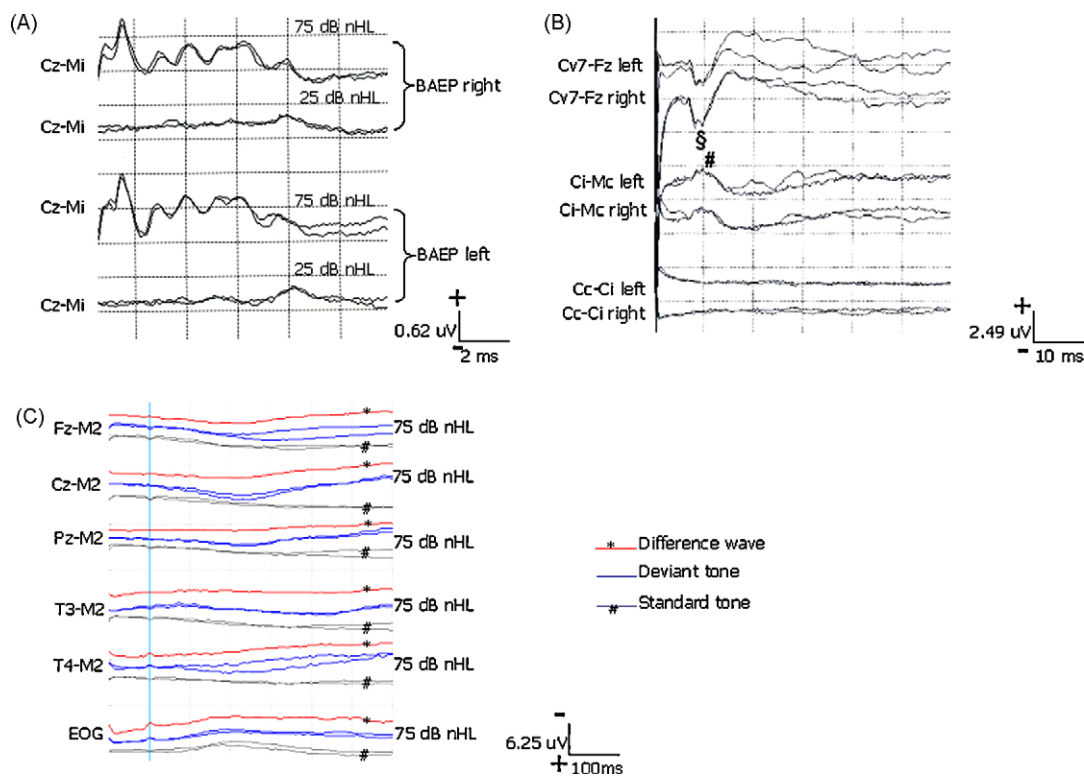


Figure 2 A. Normal BAEP to 75 and 25 dB nHL. B. SEP to median nerve stimulation showing bilateral absence of N20 cortical component and presence of N13 (§) and P14 (#) peaks. C. Auditory ERP to standard 1000 Hz tones (80% probability) and deviant 2000 Hz tones (20% probability) delivered within the Odd-ball paradigm [8], showing absence of MMN component. Cv7: spinous process of the 7th cervical vertebra; Fz, Cz, Pz, T3, T4: locations by International 10–20 System; Cc: centro-parietal scalp location contralateral to stimulus, Ci: centro-parietal scalp location ipsilateral to stimulus; Mc: mastoid process contralateral to stimulus; Mi: mastoid process ipsilateral to stimulus, M2: bilateral linked mastoids, EOG: electro-oculogram.

signs of severe hypoxic-ischemic encephalopathy were confirmed.

On Day 13, the patient was transferred to another hospital, still intubated and ventilated with a GCS of 8. The neurological examination was characterized by the absence of response to verbal stimulation, symmetrical miotic pupils with a sluggish reaction to light; corneal reflex and cough reflex were present. The patient had spontaneous eye opening and eyelid movements and he showed flexion withdrawal of arms and legs in response to strong pain stimulation. Generalized hypertonia, hyperreflexia and bilateral Babinski sign were also observed.

Seventeen months after the accident, the patient is alive, breathing spontaneously, unresponsive, tetraplegic and affected by drug resistant clinical seizures and continuous slow spike-wave activity during sleep.

Discussion

The main issue raised by our study is the prognostic role of EP in postanoxic coma occurring in childhood. Studies concerning the role of SEP in the prognosis of comatose children have been hampered not only by reports combining various aetiologies and age groups, but also by the small number of cases studied homogeneously. However, the value of SEP, particularly the finding of bilateral absence of

the N20 cortical component in children suffering from coma of various aetiologies, has now been reported in at least 700 patients less than 17 years of age. Where testing has been done with appropriate timing, the positive predictive values have been in the range of 92–100% [1,10].

A bilateral absence of cortical SEP has been reported with good recovery only in cases of focal lesions disrupting the afferent somatosensory pathway, subdural and subgaleal effusions, in a rapid surgical correction of intracranial hypertension and after a lightning strike [11], but interestingly loss of cortical SEP associated with good outcome has not been reported in postanoxic aetiology. Thus, the bilateral absence of cortical SEP shown by the patient reported in this study correctly predicted the evolution to persistent vegetative state and confirms previous findings.

We also examined auditory ERP (13 days after resuscitation) and we found no response. The role of auditory ERP, particularly the MMN component, in heralding arousal following postanoxic coma has been confirmed in adult studies, where MMN was shown to be superior to N100 auditory response, SEP, middle latency auditory evoked potentials and other clinical parameters [2]. We are not aware of previous studies on the MMN component in paediatric hypoxic-ischemic coma. It is well known that the MMN is always present in normal children of similar ages under comparable recording conditions [9]. Cochlear impairment due to asphyxia was excluded in our patient by BAEP testing

showing normal hearing (occurrence of wave V at near threshold stimulation). Although research has not yet clarified the effect of slow wave sleep mechanisms and sedation on SEP and MMN in children, the finding of non-reactive background EEG activity and the subsequent unfavorable neurological prognosis, even after hypothermia treatment, suggests that our SEP and MMN findings could be considered unfavorable features, rather than the effect of sedation or sleep.

The importance for prognostication of the evolution of EEG changes in the early hours and days after an hypoxic insult has long been recognized, since the pioneering work of Binnie et al. [12] and Prior [13].

The neurophysiological monitoring of our child suffering from severe hypoxic-ischemic encephalopathy was useful to confirm the role of the EEG in prompt identification of non convulsive status epilepticus as well as in monitoring the efficacy of antiepileptic treatment. Status epilepticus complicates postanoxic coma and, in adults, it has been shown to represent an independent outcome predictor [14]. Status epilepticus has been estimated to occur in about one third of unresponsive paediatric patients [15]; it can occur in absence of clinical signs, as with the child reported in this study. Its prompt recognition by means of EEG monitoring is important to limit the development of secondary brain damage [13].

Following recovery from status epilepticus, during the course of therapeutic hypothermia, the EEG of our patient was characterized by an alpha-theta coma pattern consisting of non-reactive, diffuse, continuous rhythms in the 6–9 Hz frequency band. The alpha-theta coma pattern, when not due to sedative drugs, is rare in children, 1% in the study by Hosain et al. [15]. No information is available on the role of hypothermia in association with the alpha-theta pattern in the EEG of comatose children.

Since brainstem involvement and severe cortical dysfunction with functional disconnection of the hemispheres have both been implicated in the pathogenesis of postanoxic alpha-theta pattern coma, the finding of normal BAEP and absent cortical SEP helped localize lesions of our patient in the cerebral cortex. Research indicates a worse prognosis in adults when the alpha pattern coma shows no reactivity to stimulation [16]. However, its prognostic significance is less clear in children [15]. SEP and AERP findings may also be used in clarifying the prognostic significance of this EEG pattern. In our patient, EP were performed when the EEG had already changed to a slow low voltage pattern, yet the evolution of EEG features was difficult to interpret because of the effect of previous hypothermia and plasma levels of antiepileptic drugs in a child. EP findings supported the suspicion of an unfavorable evolution.

Conclusion

Our data confirm the role of EP together with EEG in the management and prognosis of paediatric hypoxic-ischemic encephalopathy. When sedation and hypothermia can affect the interpretation of the EEG, the finding of normal BAEP will suggest a residual brainstem function and exclude brainstem death (even in the presence of a flat EEG), while the absence

of the MMN and cortical SEP and the lack of EEG reactivity orient the prognosis to persistent vegetative state. It would be interesting to study whether MMN is able to herald recovery of consciousness in paediatric patients with the presence of cortical SEP.

Further studies are required to evaluate the role of integrated clinical neurophysiology, and in particular the role of MMN in paediatric postanoxic coma.

Conflict of interests: none.

References

- [1] Robinson LR, Micklesen PJ, Tirschwell DL, Lew LH. Predictive value of somatosensory evoked potentials for awakening from coma. *Crit Care Med* 2003;31:960–7.
- [2] Daltrozzo J, Wioland N, Mutschler V, Kotchoubey B. Predicting coma and other low responsive patients outcome using event-related brain potentials: a meta-analysis. *Clin Neurophysiol* 2007;118:606–14.
- [3] Guérit JM, Amantini A, Amodio P, Andersen KV, Butler S, de Weerd A, et al. Consensus on the use of neurophysiological tests in the intensive care unit (ICU): Electroencephalogram (EEG), Evoked Potentials (EP), and Electroneuromyography (ENMG). *NCCN Neurophysiol Clin Clin Neurophysiol* 2009; 39.
- [4] Fischer C, Luauté J, Adeleine P, Morlet D. Predictive value of sensory and cognitive evoked potentials for awakening from coma. *Neurology* 2004;63:669–73.
- [5] Carter BG, Butt W. A prospective study of outcome predictors after severe brain injury in children. *Intensive Care Med* 2005;31:840–5.
- [6] Mandel R, Martinot A, Delepoulle F, Lamblin MD, Laureau E, Vallee L, et al. Prediction of outcome after hypoxic-ischemic encephalopathy: a prospective clinical and electrophysiologic study. *J Pediatr* 2002;141:45–50.
- [7] Mewasingh LD, Christophe C, Fonteyne C, Dachy B, Zierysen F, Christiaens F, et al. Predictive value of electrophysiology in children with hypoxic coma. *Pediatr Neurol* 2003;28: 178–83.
- [8] Hypothermia after cardiac arrest study group. Mild therapeutic hypothermia to improve the neurologic outcome after cardiac arrest. *N Engl J Med* 2002;346:549–56.
- [9] Morr ML, Shafer VL, Kreuzer JA, Kurtzberg D. Maturation of mismatch negativity in typically developing infants and preschool children. *Ear & Hearing* 2002;23:118–36.
- [10] Abend NS, Licht DJ. Predicting outcome in children with hypoxic ischemic encephalopathy. *Pediatr Crit Care Med* 2008;9:32–9.
- [11] Beca J, Cox PN, Taylor MJ, Bohn D, Butt W, Logan WJ, et al. Somatosensory evoked potentials for prediction of outcome in acute severe brain injury. *J Pediatr* 1995;126:44–9.
- [12] Binnie CD, Prior PF, Lloyd DSL, Scott DF, Margerison JH. Electroencephalographic prediction of fatal anoxic brain damage after resuscitation from cardiac arrest. *Br Med J* 1970;4:265–8.
- [13] Prior PF. The EEG in acute cerebral anoxia. Amsterdam: Excerpta Medica; 1973.
- [14] Rossetti AO, Logroscino G, Liauder L, Ruffieux C, Ribordy V, Schaller MD, et al. Status epilepticus: An independent outcome predictor after cerebral anoxia. *Neurology* 2007;69:255–60.
- [15] Hosain SA, Solomon GE, Kobylarz EJ. Electroencephalographic patterns in unresponsive pediatric patients. *Pediatr Neurol* 2005;32:162–5.
- [16] Kaplan PW, Genoud D, Ho WT, Jallon P. Etiology, neurologic correlations, and prognosis in alpha coma. *Clin Neurophysiol* 1999;110:205–13.