

Letters to the Editor Related to New Topics

The Treatment of Persistent Vascular Hemidystonia–Hemiballismus with Unilateral GPi Deep Brain Stimulation

Video 

We describe a case of a severe refractory hemidystonia–hemiballismus resulting from hemorrhage of the right subthalamic nucleus, which was managed with unilateral globus pallidus internus (GPi) deep brain stimulation (DBS).

A 56-year-old man with a history of hypertension presented with a sudden onset of headache, left hemiparesis, and dysarthria. A brain computed tomography (CT) scan showed a small focal hematoma in the right pons, midbrain, and subthalamic region. The hemiparesis and dysarthria improved over several days, although not to normality. Four days after presentation, he started to notice left sustained twisting of the wrist, posturing of the arm, held in extension, and sudden flinging movements of the whole arm. This progressed over weeks to reach a stable but disabling level that affected his balance whilst walking, and which prevented him from performing bimanual tasks since the left arm would suddenly deviate outwards. He underwent inpatient neurorehabilitation and was discharged home 1 month later, but continued to have severe ballistic movements despite maximum tolerated medication including tetrabenazine (37.5 mg/tds), haloperidol (3 mg/tds), orphenadrine (50 mg/tds), and botulinum toxin (500 U to left pectoralis). The arm was prone to frequent trauma due to uncontrollable movements. After 3 years of unsuccessful medical therapy, he was referred for functional neurosurgery and underwent multidisciplinary evaluation for DBS.

Physical examination revealed no contractures but on attempting to use his arms even minimally, he would develop a 90° flexed posture of the left wrist, and an externally rotated extended left arm (reminiscent of a waiter's tip), which would suddenly deviate backwards and laterally. There were some milder dystonic and choreic movements of the left leg. He walked with his arm firmly adducted to the body with the elbow in full extension. There was no spasticity in the limbs, and the remainder of the neurological examination was normal (Supporting Information Video). Brain MRI showed a focus of low signal on T2 and FLAIR within the right side of the midbrain with extension into the substantia nigra and subthalamic nucleus (STN) consistent with hemosiderin deposition following previous hemorrhage

(Fig. 1A). Magnetic resonance angiography, neuropsychological, and neuropsychiatric testing revealed no abnormalities precluding DBS.

Three years after the onset of his symptoms, a quadripolar DBS electrode (Medtronic 3389) was placed in the right GPi using direct MRI guided targeting under general anaesthesia (Fig. 1B). The battery was implanted in the same session. There were no complications. The DBS was switched on 2 days postoperatively. The initial parameters were case positive, contact one negative, amplitude 1.5 V, pulse width 60 µs, frequency 130 Hz. An improvement was noted in the involuntary movements within days, with the patient being able to perform the “finger-nose” test with the left hand. Regular physiotherapy was provided, and the amplitude was gradually increased to 4.5 V over the next 6 months, at which time the ballistic movements had been eliminated, although the dystonic posturing of the left wrist persisted (Supporting Information Video). Some functionality was restored, and the patient could hold pans, open doors, and walk with more ease without injuring the left arm. Standardized measures of symptom severity were not used in this case because of the lack of such scales for ballism, which was the predominant problem. However, the benefit of surgery is apparent in the videos that demonstrate the transition from the preoperative state, in which the left arm is unusable and susceptible to frequent trauma, to the postoperative state in which the patient can use the left arm purposefully. His clinical condition has remained stable at 15 months follow-up.

The patient clinically had hemidystonia and hemiballismus. Phasic dystonia has been shown to respond to GPi DBS, hence our view to offer this treatment.¹ Ventrolateral thalamotomy² and posteroventral pallidotomy^{3–5} have been shown to improve hemiballismus arising from STN lesions, but we are not aware of any GPi DBS reports for persistent hemidystonia–hemiballismus, possibly due to the rarity of this condition. The incidence of refractory hemiballismus after stroke was 0.04% in a large series.⁶

This case demonstrates the efficacy of GPi DBS for hemiballismus associated with phasic dystonia. The persistence of dystonic posturing in this case suggests that the response of dystonia may not be immediate but could improve with time, presumably due to plastic changes within the basal ganglia and thalamo-cortical loops.⁷

LEGENDS TO THE VIDEO

The preoperative video shows dystonic posturing of the left arm, ballism, and abnormal gait. The postoperative part (taken 6 months post-op) shows the patient performing the finger-nose test with his left hand and gait. Note the absence of ballism and persistence of dystonic posturing.

Additional Supporting Information may be found in the online version of this article.

Published online 18 May 2009 in Wiley InterScience (www.interscience.wiley.com). DOI: 10.1002/mds.22598

Author Roles: Harutomo Hasegawa: Wrote first draft, revised subsequent drafts; Nilesh Mundil: Review/critique of

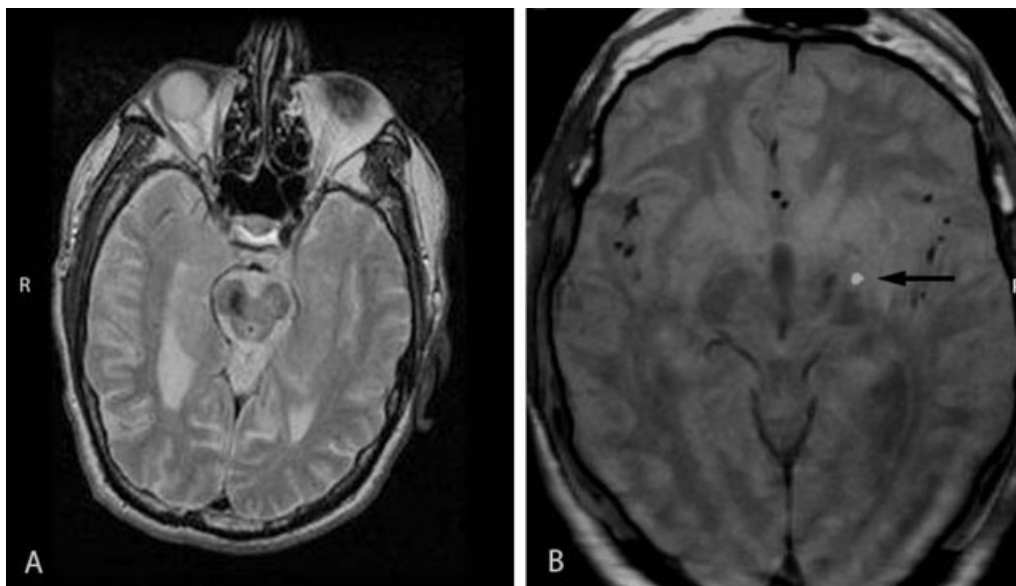


FIG. 1. (A) MR scan showing an oval shaped focus of low signal in the right side of the midbrain with extension into the substantia nigra and subthalamic nucleus. (B) Fused CT/MRI image showing the position of the active contact (arrow).

manuscript; Michael Samuel: Review/critique of manuscript; Jo Jarosz: Reported imaging; Keyoumars Ashkan: review/critique of manuscript.

Harutomo Hasegawa*
Nilesh Mundil
Department of Neurosurgery
King's College Hospital
London, United Kingdom

*E-mail: haruchobin@hotmail.com

Michael Samuel, MD, MRCP, FRCP
Department of Neurology
King's College Hospital
London, United Kingdom

Jo Jarosz, MRCP, FRCP
Department of Neuroradiology
King's College Hospital
London, United Kingdom

Keyoumars Ashkan, MB, MRCP, FRCS
Department of Neurosurgery
King's College Hospital
London, United Kingdom

References

1. Vidailhet M, Vercueil L, Houeto JL, et al. Bilateral deep-brain stimulation of the globus pallidus in primary generalized dystonia. *N Engl J Med* 2005;352:459–467.
2. Cardoso F, Jankovic J, Grossman RG, Hamilton WJ. Outcome after stereotactic thalamotomy for dystonia and hemiballismus. *Neurosurgery* 1995;36:501–508.
3. Yamada K, Harada M, Goto S. Response of postapoplectic hemichorea/ballism to GPi pallidotomy: progressive improvement resulting in complete relief. *Mov Disord* 2004;19:1111–1114.

4. Suarez JJ, Metman LV, Reich SG, Dougherty PM, Hallett M, Lenz FA. Pallidotomy for hemiballismus: efficacy and characteristics of neuronal activity. *Ann Neurol* 1997;42:807–811.
5. Vitek JL, Chockkan V, Zhang JY, et al. Neuronal activity in the basal ganglia in patients with generalized dystonia and hemiballismus. *Ann Neurol* 1999;46:22–35.
6. Ghika-Schmid F, Ghika J, Regli F, Bogousslavsky J. Hyperkinetic movement disorders during and after acute stroke: The Lausanne Stroke Registry. *J Neurol Sci* 1997;146:109–116.
7. Tisch S, Rothwell JC, Bhatia KP, et al. Pallidal stimulation modifies after-effects of paired associative stimulation on motor cortex excitability in primary generalised dystonia. *Exp Neurol* 2007;206:80–85.

Pallidal Deep Brain Stimulation in Belly Dancer's Dyskinesia

Video 

We report a case of belly dancer's dyskinesia (BDD) successfully treated with deep brain stimulation (DBS) of the globus pallidus internus (GPI) for an observational period of 30 months.

The term “belly dancer's dyskinesia” was coined by Illiceto et al. in 1990 to describe focal dyskinesias affecting the abdominal wall in five patients.¹ The clinical picture of BDD was dominated by writhing movements and contractions of

Potential conflict of interest: CS received honoraria from Boehringer Ingelheim and Solvay Pharmaceuticals, both unrelated to this work. JKK is consultant to Medtronic Deutschland GmbH and Medtronic Inc.

Published online 18 May 2009 in Wiley InterScience (www.interscience.wiley.com). DOI: 10.1002/mds.22579

the abdominal muscles. Their onset was usually gradual, and they could be suppressed only temporarily by holding up the breath. An antecedent of local trauma or surgical procedures of the abdomen was present in half of the cases.^{1,2} Investigations, such as spinal and abdominal imaging, failed to reveal any abnormality that could explain the movement disorder. Since the first description, a variety of similar disorders have been reported, most of them fulfilling either the clinical or electrophysiological criteria of spinal³⁻⁶ or brainstem-derived myoclonus.^{1,7} In most cases, the prognosis was quite unfavorable as no effective treatment has been reported so far.

Since pallidal DBS has been introduced in the late 1990 for treatment of dystonia,⁸ it has been shown to be effective in various dystonic and dyskinesic movement disorders with a more pronounced effect on phasic or myoclonic dystonic elements.^{9,10}

A 78-year-old woman presented with a 3-year history of involuntary movements. At age of 75, she had developed semirhythmic dyskinesic contractions of the abdominal wall resulting in writhing and bending of the trunk. Somewhat later, orofacial dyskinesias also occurred, and both movements had gradually increased in severity since that time. According to her husband, they disappeared during sleep. There was no history of antecedent abdominal or spinal trauma, tumor, surgical procedure, or anti-dopaminergic treatment.

On examination there were continuous, slow, sinuous contractions of the upper abdominal muscles. They were observed in all positions, but were most evident when she was lying down or sitting relaxed. The movements fluctuated in intensity during respiration, being greatly reduced during deep inspiration, expiration, and breath-holding. They were not stimulus-sensitive. The involuntary orofacial movements were continuously present.

Cranial and spinal MRI revealed no circumscribed lesion; normal sensory and motor evoked potentials and normal CSF ruled out a spinal lesion. All lab tests including copper, ceruloplasmin, thyroid status, and blood smear were unremarkable. As several oral drug approaches, including tiapride 600 mg per day, were only of transient and limited effect, she was selected for pallidal DBS.

Quadripolar electrodes were placed stereotactically in the posteroventral lateral part of the GPi. Microelectrode recordings were performed additionally for optimal target localization. Clinical evaluation employed the Burke-Fahn-Marsden Dystonia Rating Scale (BFMDRS) and the Abnormal Involuntary Movement Scale (AIMS) which were obtained prior to surgery, 1 week postoperatively and at 9 and 30 months follow-up using video-based rating (see video).

Prior to surgery, the BFMDRS movement subscore was 26 and on AIMS she scored 23. Bipolar high frequency stimulation starting at 130 Hz, 210 μ s, and 4 V clearly suppressed BDD significantly for 6 weeks. Subsequent waning of the effect of stimulation concerned predominantly the truncal involuntary movements and required continuous adjustment of stimulation settings which included activating four contacts and increasing voltage and frequency. Interestingly, the orofacial elements improved sooner.

At 9 months follow-up her dyskinesia was rescored 36 hours off stimulation and 48 hours after reactivation of the pacemakers. Phasic movements showed better improvement than tonic elements.

Twenty-four months after surgery, the battery of the DBS device ran flat. Clinically, the truncal dyskinesia reemerged

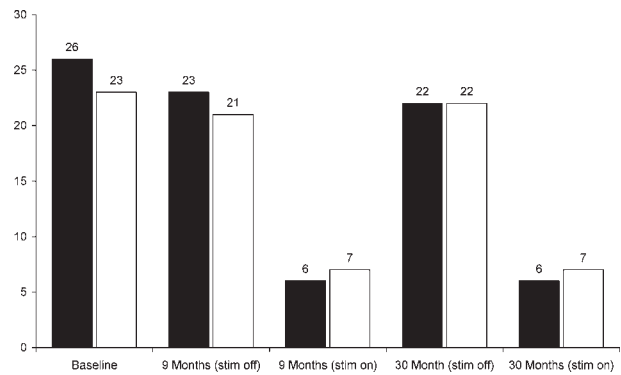


FIG. 1. Effect of bilateral GPi stimulation in belly dancer's dyskinesia before DBS (baseline) and at 9- and 30-months follow-up. Follow-up was performed in stim-off and stim-on state. For the off-state, DBS was discontinued for 36 hours. On-scoring was performed 48 hours after reactivation of the DBS device. Black bars: Burke-Fahn-Marsden-Dystonia-Rating-Scale (BFMDRS) motor part; white bars: Abnormal Involuntary Movement Scale (AIMS).

gradually over a period of 1 week. After battery replacement, the clinical effect took 3 days to reach a level comparable with that of 9-month follow-up. The effect of stimulation remained constant over 30 months (Fig. 1). Medication (200 mg tiapride tid) remained stable over the observation period.

The etiology of BDD is unclear. In our case, it was associated with oral dyskinesias, but tardive dyskinesia could be excluded. BDD is often resistant to medical treatment. Trihexyphenidyl^{1,2,11} or benzodiazepines³ were of limited use in several cases. Deanol aceglutamate,¹¹ carbamazepine,³ and transcutaneous electrical nerve stimulation (TENS)¹² have been reported beneficial to suppress involuntary abdominal movements in single patients. In our patient, tiapride only transiently suppressed BDD, however, GPi DBS was a safe and effective option for an observation period of 30 months. We suggest, therefore, that pallidal DBS might be considered a second-line treatment option in this rare disorder. Further experience in other patients is needed.

LEGENDS TO THE VIDEO

Segment 1. This segment demonstrates pre-operatively condition. BDD is most evident while sitting but can also be observed in standing position.

Segment 2. Nine months follow-up, stim-on state. The DBS device was turned on 36 hours before this video recording. BDD is almost completely suppressed even during provoking measures such as counting backwards or finger-to-nose-test.

Segment 3. Nine months follow-up, stim-off state. The DBS device was turned off for 48 hours. BDD recurs, but is slightly less pronounced than at baseline.

Segment 4. 30 months follow-up, stim-on. BDD is persistently markedly suppressed.

Christoph Schrader, MD*

Department of Neurology and Clinical Neurophysiology
Medical School of Hannover
Hannover, Germany

*E-mail: schrader.christoph@mh-hannover.de

Holger Capelle, MD
 Thomas Kinfe, MD
 Joachim K. Krauss, MD
*Department of Neurosurgery
 Medical School of Hannover
 Hannover, Germany*

References

1. Illiceto G, Thompson PD, Day BL, Rothwell JC, Lees AJ, Marsden CD. Diaphragmatic flutter, the moving umbilicus syndrome, and "belly dancer's" dyskinesia. *Mov Disord* 1990;5:15–22.
2. Caviness JN, Gabellini A, Kneebone CS, Thompson PD, Lees AJ, Marsden CD. Unusual focal dyskinesias: the ears, the shoulders, the back, and the abdomen. *Mov Disord* 1994;9:531–538.
3. Inghilleri M, Conte A, Frasca V, Vaudano AE, Meco G. Belly dance syndrome due to spinal myoclonus. *Mov Disord* 2006;21:394–396.
4. Kono I, Ueda Y, Araki K, Nakajima K, Shibasaki H. Spinal myoclonus resembling belly dance. *Mov Disord* 1994;9:325–329.
5. Shamim EA, Hallett M. Intramedullary spinal tumor causing "belly dancer syndrome". *Mov Disord* 2007;22:1673–1674.
6. Tamburin S, Idone D, Zanette G. Belly dancer's myoclonus and chronic abdominal pain: pain-related dysinhibition of a spinal cord central pattern generator? *Parkinsonism Relat Disord* 2007;13:317–320.
7. Roggendorf J, Burghaus L, Liu WC, et al. Belly dancer's syndrome following central pontine and extrapontine myelinolysis. *Mov Disord* 2007;22:892–894.
8. Krauss JK, Pohle T, Weber S, Ozdoba C, Burgunder JM. Bilateral stimulation of globus pallidus internus for treatment of cervical dystonia. *Lancet* 1999;354:837–838.
9. Capelle HH, Weigel R, Krauss JK. Bilateral pallidal stimulation for blepharospasm-oromandibular dystonia (Meige syndrome). *Neurology* 2003;60:2017–2018.
10. Lohr TJ, Capelle HH, Kaelin-Lang A, et al. Deep brain stimulation for dystonia: outcome at long-term follow-up. *J Neurol* 2008;255:881–884.
11. Burn DJ, Coulthard A, Connolly S, Cartledge NE. Tardive diaphragmatic flutter. *Mov Disord* 1998;13:190–192.
12. Linazasoro G, Van Blercom N, Lasa A, Fernandez JM, Aranzabal I. Etiological and therapeutical observations in a case of belly dancer's dyskinesia. *Mov Disord* 2005;20:251–253.

Levosulpiride-Induced Resting Orolingual Tremor

Video 

Levosulpiride is a benzamide derivative used in the treatment of dyspepsia.¹ Because it exerts its pharmacologic activity mainly by blocking dopaminergic D2 receptor activity, levosulpiride can cause extrapyramidal symptoms (EPS), most of which are generalized parkinsonism.^{2,3} We report a

case of orolingual resting tremor associated with levosulpiride use.

A 61-year-old woman presented with rhythmic oscillation of the perioral muscles. She had worn upper and lower dentures for 10 years and had undergone dental implant insertion for the two lower incisors 5 months before visiting our hospital, when the oral tremor began to develop. The tremor did not interfere with her ability to speak, chew, or swallow. She had a few-year history of dyspepsia, and she had been taking levosulpiride at a dose of 75 mg/day for 9 months. The findings of a neurological examination were unremarkable, except for the presence of an orolingual tremor. She had no bradykinesia, rigidity, or tremor in any of her extremities. Her gait and posture were normal. Rhythmic movements of the perioral muscles were observed at a frequency of 4 to 5 Hz when she closed her jaw, and they disappeared when she began to speak. When she opened her mouth, the perioral tremor disappeared, but a tongue tremor of the same frequency was noted. The tongue tremor was observed when the tongue was protruded as well as in the resting position. There was no palatal tremor or audible ear click. Interestingly, her tremor was amplified when she removed her dentures (Video Segment 1). Levosulpiride was discontinued due to the suspicion of a drug-induced orolingual tremor. Her tremor disappeared completely after 7 weeks (Video Segment 2).

It was recently reported that levosulpiride can induce a resting suprahoid neck and tongue tremor.⁴ However, orolingual tremor, which is more commonly encountered in clinical practice than neck and tongue tremor, has not been described in association with levosulpiride use. The tremor in our patient was present mainly in the resting state, and it involved the perioral muscles and tongue, making it indistinguishable from a Parkinsonian orolingual tremor.⁵ The tremor disappeared completely following the discontinuation of levosulpiride. Although our patient did not have bradykinesia or rigidity, these findings suggest that the tremor in our patient was caused by the dopamine-receptor-blocking activity of levosulpiride.

One interesting feature of our case is that the tremor was amplified on removal of her dentures. The edentulous state has also been reported to increase the severity of perioral involuntary movement in tardive oral dyskinesia.⁶ It could be simply because removal of the dentures provided more space around the perioral muscles for the tremor to occur. Alternatively, sensory stimuli from the dentures could have attenuated the perioral tremor through an unknown mechanism that may resemble the "sensory trick" in dystonia. However, the presence of a "sensory trick" has not been demonstrated in tremor.⁷

In conclusion, although levosulpiride has been associated with a low frequency of EPS due to its low affinity for the dopamine D2 receptor and generalized parkinsonism is the most frequently reported extrapyramidal adverse effect,^{1,3} our case shows that levosulpiride can induce isolated resting orolingual tremor.

LEGENDS TO THE VIDEO

Segment 1. The video shows rhythmic movements of the perioral muscles at rest. It disappeared when she began to

Additional Supporting Information may be found in the online version of this article.

Potential conflict of interest: Nothing to report.

Published online 18 May 2009 in Wiley InterScience (www.interscience.wiley.com). DOI: 10.1002/mds.22578

speak. Her tremor was amplified when she removed her dentures.

Segment 2. Her tremor disappeared completely after 7 weeks. This video was taken with her dentures removed.

Acknowledgments: This work was supported by the 2007 Inje University research grant.

Han-Joon Kim, MD*

*Department of Neurology, Movement Disorder Center
CRC, Seoul National University Hospital
Seoul, Korea*

**E-mail: cupofcoffee@hanmail.net*

Joong-Yang Cho, MD, PhD

Yong-Jin Cho, MD, PhD

Keun-Sik Hong, MD, PhD

*Department of Neurology and Clinical Research Center
Inje University Ilsan Paik Hospital*

Goyang-si

Gyeonggi-do, Korea

References

- Rossi F, Forgione A. Pharmacotoxicological aspects of levosulpiride. *Pharmacol Res* 1995;31:81–94.
- Benazzi F. Side-effects of benzamide derivatives. *Int J Geriatr Psychiatry* 1997;12:132.
- Kim JS, Ko SB, Han SR, Kim YI, Lee KS. Levosulpiride-induced Parkinsonism. *J Korean Neurol Assoc* 2003;21:418–421.
- Baik JS, Lyoo CH, Lee JH, Lee MS. Drug-induced and psychogenic resting suprahoid neck and tongue tremors. *Mov Disord* 2008;23:746–748.
- Silverdale MA, Schneider SA, Bhatia KP, Lang AE. The spectrum of orolingual tremor—a proposed classification system. *Mov Disord* 2008;23:159–167.
- Myers DE, Schooler NR, Zullo TG, Levin H. A retrospective study of the effects of edentulism on the severity rating of tardive dyskinesia. *J Prosthet Dent* 1993;69:578–581.
- Masuhr F, Wissel J, Mueller J, Scholz U, Poewe W. Quantification of sensory trick impact on tremor amplitude and frequency in 60 patients with head tremor. *Mov Disord* 2000;15:960–964.

Normal Diffusion-Weighted MR Imaging Predicts a Good Prognosis in Extrapontine Myelinolysis-Induced Parkinsonism

Extrapontine myelinolysis (EPM) is a rare neurologic disorder induced by osmotic demyelination arising from rapid correction of hyponatremia.¹ EPM is usually combined with central pontine myelinolysis (CPM),² and pure EPM occurs rarely.³ The prognosis of CPM/EPM varies widely: the patient may return to normal functioning, but the condition

may also lead to death.⁴ There are no known parameters predicting prognosis of CPM/EPM in its early phase.

A 36-year-old alcoholic patient was admitted to our hospital because of a 4-day history of jaundice. His medical history revealed that he had taken prednisolone for treatment of nephrotic syndrome since he was 11 years of age. He had been drinking alcohol every day for a week before admission and had not eaten during this time. On admission, he showed no neurological deficits. His serum sodium level was 109 mEq/L and this imbalance was corrected with hypertonic saline. Serum alanine aminotransferase, aspartate aminotransferase, alkaline phosphatase, gamma-glutamyl-transpeptidase, and total bilirubin levels were elevated to 169 IU/L, 83 IU/L, 207 IU/L, 419 IU/L, and 2.3 mg/dL, respectively. Serum ammonia was also elevated to 143 µg/dL. Abdominal ultrasonography did not detect any specific liver problem. Elevated liver enzyme levels and ammonia spontaneously normalized. His sodium level was gradually corrected to 136 mmol/L over the next 5 days. On the fifth day of treatment, he showed marked hypomimia and dysarthria, but his mental status and cognition were normal. Extraocular movement was not impaired. He had marked parkinsonism, including symmetric rigidity and bradykinesia of every limb, and tremor in both arms at rest and in a stretching posture. The patient was unable to arise from the chair independently and unable to swallow because of severe dysphagia. Arm and leg strength were normal despite of severe bradykinesia. Brain MRI taken 5 days after the onset of symptoms revealed symmetrically increased signal intensity in the putamen and caudate nucleus on T2-weighted imaging, with iso-intensity on the T1-weighted image (Fig. 1A). There was no signal change in the pons. The apparent diffusion coefficient (ADC) of diffusion-weighted image (DWI) of the basal ganglia was normal (Fig. 1B). He was treated with levodopa for 2 months, at which time the drug was successfully withdrawn because parkinsonism and dysphagia had almost completely resolved. A follow-up MRI after 7 months revealed significant resolution of the basal ganglion lesion on T2-weighted imaging (Fig. 1C). However, a signal change in the central pons was found on the T2-weighted image; this had not been seen on the initial MRI.

Our patient showed subacute progressive parkinsonism after rapid correction of hyponatremia. Initial clinical and neuroimaging findings were compatible with EPM without CPM, although but the follow-up brain MRI revealed a newly observed pontine lesion suggesting CPM. It is unclear whether the pontine and the basal ganglia lesions developed separately or not. Because rapid correction of hyponatremia was done before initial MRI and there was no clinical deterioration after initial MRI, the pontine lesion in this patient might be present, although undetectable, at the time when initial MRI was taken. Chua et al.⁵ also demonstrated that more CPM/EPM lesions were observed in the follow-up MRIs performed several weeks later, compared with the initial MRIs. Elevated liver enzyme and serum ammonia levels suggest that parkinsonism in this patient is associated with chronic liver disease, that is, acquired hepatocerebral degeneration. However, early normalization of liver enzyme and ammonia levels as well as lack of typical MRI findings consistent with acquired hepatocerebral degeneration (high-signal lesions in the basal ganglia on T1-weighted images)⁶ may minimize this possibility.

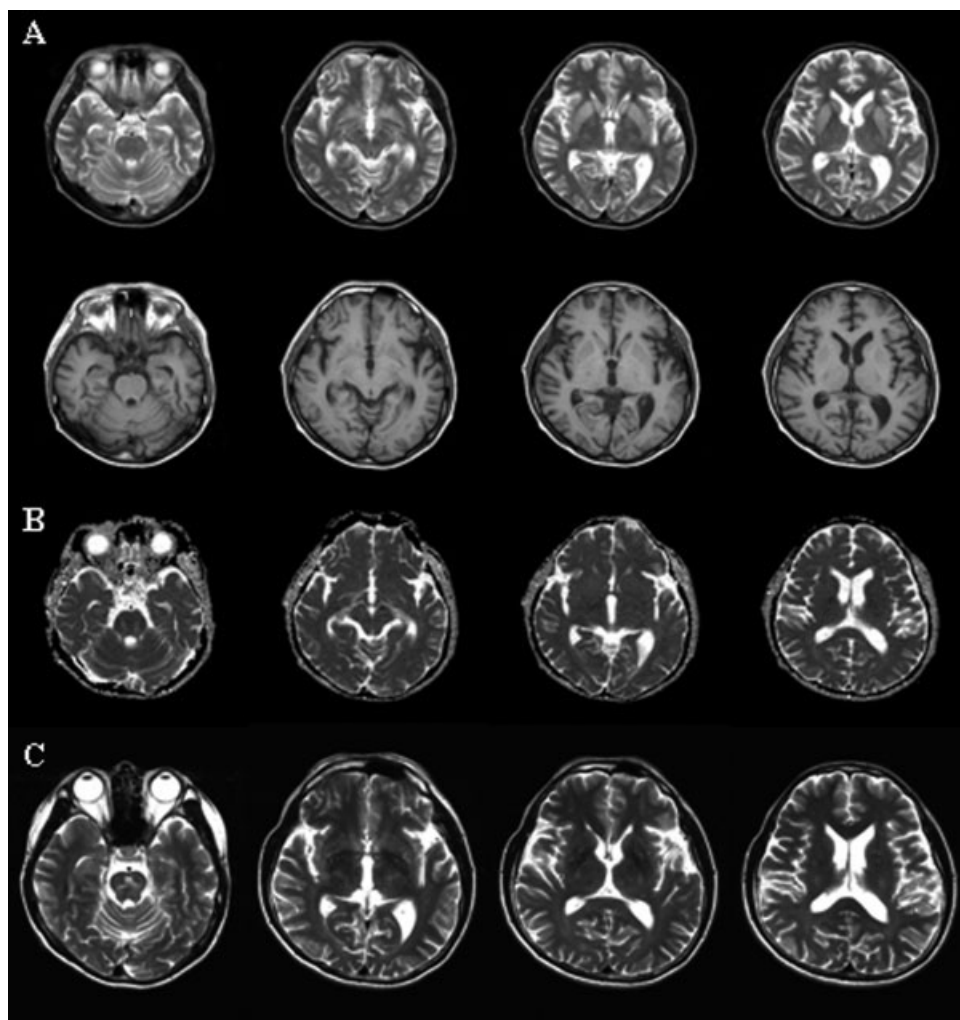


FIG. 1 A: Brain MRI performed on the fifth day after onset of Parkinsonism revealing symmetrically increased signal intensity in the putamen and caudate nucleus on T2-weighted imaging, with isointensity on the T1-weighted image, and without signal change in the pons. B: The ADC of the DWI was normal. C: The follow-up MRI at 7 months revealed significant resolution of the basal ganglia lesion on T2-weighted imaging, but with signal change in the central pons.

Brain MRI is a sensitive tool for diagnosis of CPM/EPM, but it cannot predict prognosis of the condition. Although brain MRI in our patient showed extensive lesions in the basal ganglia, the patient recovered completely from profound parkinsonism. Recent case studies^{5,7} have reported that signal changes in DWI are seen in the early phases of CPM/EPM. Various ADC values of DWI in CPM/EPM patients^{5,7} reflect the complex pathogenic mechanism of CPM/EPM. A reduction of the ADC is associated with cytotoxic cellular edema while vasogenic edema usually shows elevation of the ADC.^{5,7} Therefore, it is hoped that ADC measurements may eventually be of prognostic predictive value. Recently, Dervisoglu et al.⁸ proposed a relationship between rapid ADC normalization and a favorable clinical outcome of CPM/EPM. DWI in our patient was normal on the fifth day after the appearance of clinical manifestations, despite the presence of extensive basal ganglia lesions on T2-weighted imaging. A normal ADC value at an early stage appears to reflect rapid normalization of DWI signal changes. The present case provides a further illustration of

the value of DWI in predicting CPM/EPM prognosis, supporting the findings of a previous report.⁸ A further study involving a large number of patients is required to determine the prognostic value of DWI in CPM/EPM cases.

Acknowledgments: This work was supported by the Brain Korea 21 Project for Medical Science, Yonsei University.

Hae-Won Shin, MD
*Department of Neurology and Brain Research Institute
 Yonsei University College of Medicine
 Seoul, Korea*

*Department of Neurology
 Parkinson/Alzheimer Center
 Asan Medical Center
 University of Ulsan College of Medicine
 Seoul, Korea*

Dongbeom Song, MD
*Department of Neurology and Brain Research Institute
 Yonsei University College of Medicine
 Seoul, Korea*

Young H. Sohn, MD, PhD*
*Department of Neurology and Brain Research Institute
 Yonsei University College of Medicine
 Seoul, Korea*
 *E-mail: yhsohn62@yuhs.ac

References

1. Lauren R, Karp BI. Pontine and extrapontine myelinolysis following rapid correction of hyponatraemia. *Lancet* 1988;1:1439–1441.
2. Martin RJ. Central pontine and extrapontine myelinolysis: the osmotic demyelination syndromes. *J Neurol Neurosurg Psychiatry* 2004;75 (Suppl 3):iii22–iii28.
3. Tomita I, Satoh H, Satoh A, Seto M, Tsujihata M, Yoshimura T. Extrapontine myelinolysis presenting with parkinsonism as a sequel of rapid correction of hyponatraemia. *J Neurol Neurosurg Psychiatry* 1997;62:422–423.
4. Menger H, Jorg J. Outcome of central pontine and extrapontine myelinolysis (n = 44). *J Neurol* 1999;246:700–705.
5. Chua GC, Sitoh YY, Lim CC, Chua HC, Ng PY. MRI findings in osmotic myelinolysis. *Clin Radiol* 2002;57:800–806.
6. Brunberg JA, Kanal E, Hirsch W, van Thiel DH. Chronic acquired hepatic failure: MR imaging of the brain at 1.5 T. *AJNR Am J Neuroradiol* 1991;12:909–914.
7. Chu K, Kang DW, Ko SB, Kim M. Diffusion-weighted MR findings of central pontine and extrapontine myelinolysis. *Acta Neurol Scand* 2001;104:385–388.
8. Dervisoglu E, Yegenaga I, Anik Y, Sengul E, Turgut T. Diffusion magnetic resonance imaging may provide prognostic information in osmotic demyelination syndrome: report of a case. *Acta Radiol* 2006;47:208–212.

Lingual Dystonia as a Manifestation of Thalamic Infarction

The thalamus is the relay structure for the motor¹ and sensory nervous systems,² and lesions occurring in this region may cause involuntary movements including delayed-onset dystonia.^{3,4} However, dystonia in the acute stage of thalamic infarction has rarely been reported.⁵ Moreover, orolingual dystonia is an extremely rare manifestation of thalamic infarction.^{5,6}

A 70-year-old man was admitted to our hospital due to a sudden onset of swallowing difficulty and involuntary tongue movements that commenced 2 weeks before. Three days before admission, dysphagia became aggravated, and he could not ingest any type of food. He had undergone a carotid endarterectomy for left internal carotid artery stenosis 3

years previously after a right pure motor stroke, and had since taken antiplatelet and antilipidemic drugs. He denied the use of any antidopaminergic drugs such as gastrointestinal prokinetics or neuroleptics.

The patient's tongue was found to be elevated with slow, irregular and continuous retraction movements to the posterior oral cavity (see Video, Segment 1). There were no involuntary movements in other body parts. Facial and masseter muscle power was normal, but he could not easily move his mouth because of the tongue dystonia. Face and limb sensory functions were normal. Laboratory findings on routine hematologic, biochemical and thyroid function studies were all normal. Diffusion-weighted brain magnetic resonance imaging (MRI) taken 2 weeks after the onset of initial symptoms showed an acute focal infarct in the right posterolateral thalamus. The lesion included two contiguous areas, one with a brighter signal intensity than the other (Fig. 1A). A T2-weighted image demonstrated multiple old infarctions in the bilateral thalami and basal ganglia (Fig. 1B). Video fluoroscopy revealed continuous involuntary tongue movement and abnormal pharyngeal contractions without aspiration during the swallowing of test materials (see Video, Segment 2). Four months later, involuntary movements of the tongue resolved, and everything appeared normal. The ability to ingest food returned to normal.

The present patient is unique in that he showed dystonic tongue retraction to the posterior oral cavity. Tongue retraction dystonia (as demonstrated by video fluoroscopy) and the absence of aspiratory signs indicated that the swallowing difficulty was caused by lingual dystonia. Diffusion-weighted MRI showed two adjacent acute ischemic lesions with slightly different signal intensities. Considering the patient's history, extension of the acute infarction near the initial lesion may have caused the aggravated dysphagia 3 days before admission.

The patient developed lingual dystonia as an initial symptom of acute thalamic infarction. Previous reports indicate that secondary dystonia due to a thalamic infarction usually develops weeks to months after the acute stage of infarction, reflecting the excessive neuronal reorganization during recovery from motor weakness or sensory loss.^{3,4} One similar case report described acute oral dyskinesia caused by bilateral thalamocapsular infarcts, but did not discuss possible pathological mechanisms.⁵ Unlike that report, the diffusion-weighted brain MRI in our patient showed a unilateral lesion. However, there were multiple old ischemic lesions in the bilateral thalami, and an acute infarction in the right thalamus might have generated lingual dystonia in concert with underlying ischemic lesions in the contralateral thalamus.

The mechanisms underlying acute lingual dystonia due to a thalamic lesion remain unknown. One possible mechanism of lingual dystonia due to a thalamic lesion would be the disinhibition of the thalamocortical projection. Because excitatory thalamocortical projection is inhibited by the GPI/SNr complex, blockage of these inhibitory fibers may result in hyperkinetic movement disorders by way of allowing excessive activation of corticospinal projections. Bilateral cortical projection to the lingual muscle might cause the excessive contraction of both sets of styloglossus muscles,⁷ and result in retraction lingual dystonia in the unilateral thalamic infarction.

Potential conflict of interest: Nothing to report.

Published online 1 June 2009 in Wiley InterScience (www.interscience.wiley.com). DOI: 10.1002/mds.22657

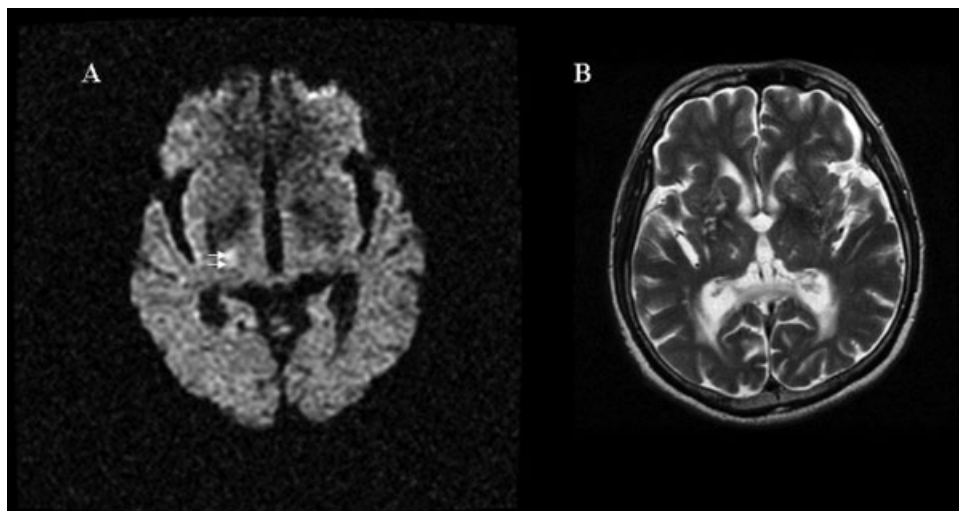


FIG. 1. (A) Initial diffusion-weighted brain magnetic resonance imaging (MRI) scan obtained 14 days after the onset of symptoms. Note the two contiguous lesions with different high signal intensities in the posterolateral part of the right thalamus (arrows). (B) T2-weighted brain MRI showing multiple old ischemic lesions in the bilateral thalami and basal ganglia.

The present case showed that isolated lingual dystonia can be caused by thalamic infarction. Therefore, thalamic lesions should be considered in cases of acute onset lingual dystonia.

Hye-Jin Kim, MD
 Myoung C. Lee, MD
 Jong S. Kim, MD, PhD
 Sun J. Chung, MD, PhD
 Hye-Jin Kim, MD
 Miseon Kwon, PhD, CCC-SLP
 Hae-Won Shin, MD*
*Department of Neurology
 Parkinson/Alzheimer Center
 Asan Medical Center
 University of Ulsan College of Medicine, Seoul, Korea
 E-mail: shinhw@amc.seoul.kr

References

1. Joel D, Weiner I. The organization of the basal ganglia-thalamo-cortical circuits: open interconnected rather than closed segregated. *Neuroscience* 1994;63:363–379.
2. Apkarian AV, Hodge CJ. Primate spinothalamic pathways: III. Thalamic terminations of the dorsolateral and ventral spinothalamic pathways. *J Comp Neurol* 1989;288:493–511.
3. Kim JS. Delayed onset mixed involuntary movements after thalamic stroke: clinical, radiological and pathophysiological findings. *Brain* 2001;124 (Part 2):299–309.
4. Lee MS, Marsden CD. Movement disorders following lesions of the thalamus or subthalamic region. *Mov Disord* 1994;9:493–507.
5. Combarros O, Gutierrez A, Pascual J, Berciano J. Oral dyskinesias associated with bilateral thalamo-capsular infarction. *J Neurol Neurosurg Psychiatry* 1990;53:168–169.
6. Lehericy S, Vidailhet M, Dormont D, et al. Striatopallidal and thalamic dystonia. A magnetic resonance imaging anatomoclinical study. *Arch Neurol* 1996;53:241–250.
7. Muellbacher W, Boroojerdi B, Ziemann U, Hallett M. Analogous corticocortical inhibition and facilitation in ipsilateral and contralateral human motor cortex representations of the tongue. *J Clin Neurophysiol* 2001;18:550–558.

Linburg's Syndrome, Can It Cause Focal Dystonia?

Video 

Repeating movements of high complexity changes the functional organization of the central motor nervous system. In the case of musicians, such plasticity can be maladaptive, and cause task-specific focal dystonia,¹ which may be triggered by biomechanical constraints.²

In the Linburg-Comstock syndrome,³ an aberrant connection between the tendons of the thumb (flexor pollicis longus, FPL) and the index finger (flexor digitorum profundus, FDP), limits active flexion of the thumb interphalangeal joint if there is no simultaneous flexion of the index' distal interphalangeal joint. This constraint is present in a third of the general population,⁴ but is not known to generate specific problems among musicians.⁵

A 32-year-old male classical pianist presented with an involuntary flexion of the index finger while playing piano, which he noticed during a concert 6 weeks earlier. He reported always experiencing some constrain moving the thumb with his index finger extended, but did not recall any musical pieces where this movement was repeated intensively or where he could not reconfigure the fingering of the passage. However, for the preceding 2 months he had been practicing Chopin OP 25-11, which requires repeated movements of the thumb to various keys while the index finger is extended. He experienced some difficulties during the preparation of the concert but denied involuntary

Potential conflict of interest: There has been no financial support for the study reported in this manuscript.

Published online 9 June 2009 in Wiley InterScience (www.interscience.wiley.com). DOI: 10.1002/mds.22667

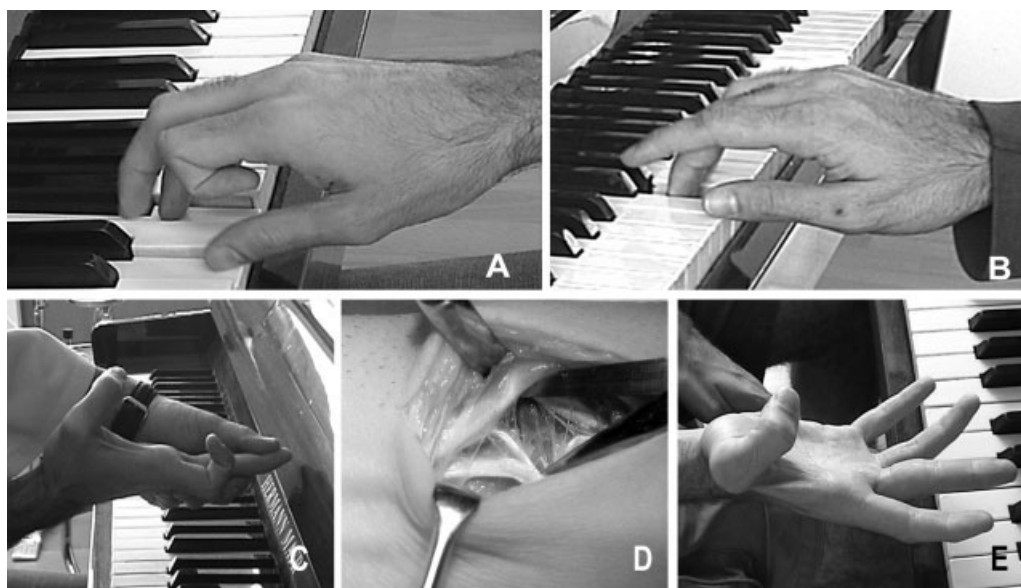


FIG. 1. In this musician, dystonia is seen as involuntary flexion of the index finger (A). Six months after the onset of the reeducation program, the involuntary index finger flexion is no longer seen playing on the piano or other activities (B). Before surgery, thumb flexion is not possible without simultaneous index finger flexion (C). Surgical inspection of the tendons demonstrates a connection between FPL and FDP tendons (D). After surgical release of the connection, thumb flexion is possible without simultaneous index finger flexion (E).

movements or contractions till the concert day when he first noticed the problem.

Physical exam revealed an apparently forced flexion of the index finger that appeared only during piano playing (Fig. 1A), and the impossibility to maintain flexion of the thumb without accompanying flexion of the distal interphalangeal joint of the index finger (1C). Neurological examination, nerve conduction test, and electromyogram did not reveal other abnormalities. Our working diagnosis was task-specific focal dystonia in a patient with Linburg-Comstock syndrome.

After surgical release of the tendons (Fig. 1D), the patient was able to perform independent distal interphalangeal joint flexion of the index and the thumb (Fig. 1E). He began cautiously to practice piano 4 days after the operation, and reported a significant, albeit not complete, improvement in his performance. Unfortunately, the improvement remitted after a few days, and he began to complain again of involuntary flexion of the index finger. We initiated a neuro-rehabilitation program based on Sensory Motor Retuning⁶ that involved daily sessions of work on the piano performing seven different digit combinations while some of the fingers splinted for ~90 min, followed by practice of slow and easy movements without splints. Every month, the practice schedule, specific exercises, kind of digit combinations, and digit positions during the work were checked and adjusted if needed. The goal is to promote alternative motor programs based on modification of the proprioceptive input. The patient showed a progressive improvement of his condition, and task-induced involuntary flexion of the index finger was gone after 6 months (Fig. 1B). Eventually, he returned to his professional activity and his symptoms have not returned over the past 2 years.

The Linburg-Comstock syndrome is a congenital condition and, therefore, our patient certainly had the mechanical constraints related to it all his life. Likely, he was well adapted to this condition, with no apparent motor difficulties until

playing the Chopin concert. As this piece does not allow alternative movements, he was forced to train in adverse biomechanical conditions, which might have led to the development of unwanted motor synergies and ultimately the manifestation of focal dystonia.

After surgical repair of the Linburg-Comstock syndrome, biomechanical, cutaneous, and proprioceptive changes appear to have been sufficient for a transient improvement of our patient's dystonia. In some musicians, focal dystonia can be relieved by postural or mechanical strategies, like having a piece of tape attached to one finger, or holding an object between two fingers. Such "tricks" might work because changes in sensory inputs may improve selection of motor commands⁷ or minimize abnormalities of sensory processing.⁸ Unfortunately, dystonic movements often reappear after a variable time of practice (minutes to days). Similarly, the post-surgical benefit in our patient was time-limited but further recovery was possible with Sensory Motor Retuning, which might have induced a more consistent change in the dysfunctional central nervous system circuits.⁶

Our case reveals that, even when an apparent precipitating event is clearly recognized, dystonia, which involves a plastic change in the central nervous system, may remain after the apparent precipitating cause has been removed. The process of re-learning the specific motor task, such as with Sensory Motor Retuning, may succeed in improving motor control. However, we speculate that, in the particular case reported here, surgical intervention could have been partially useful by facilitating re-education under more favorable biomechanical conditions.

LEGENDS TO THE VIDEO

Segment 1. Flexion of the interphalangeal joint of the thumb is not possible without index finger flexion. The

patient was requested to flex the thumb but this was not possible to do in isolation (without flexing the index finger too), due to an anomalous connection between the tendons of the two muscles.

Segment 2. Involuntary index finger flexion and middle finger extension. After practicing piano playing and trying to perform movements requiring simultaneous thumb flexion and index extension, the patient began to feel involuntary movements on the index and middle finger.

Segment 3. Post-surgery: flexion of the interphalangeal joint is now possible without simultaneous index flexion. Surgical liberation of the anomalous tendinous connections allowed isolated thumb movements.

Segment 4. Reduction of involuntary movements. Surgical liberation of the tendons led to a clear amelioration of motor performance, with less unwanted index finger flexion and middle finger extension.

Segment 5. Involuntary movements reappeared after 15 days of practicing piano. The patient was asked to slowly return to piano practice after surgery. However, the involuntary index finger flexion and middle finger extension reappear 2 weeks after starting practice.

Segment 6. Involuntary movements improved after 6 months of reeducation. Guided repetitive daily exercises on the piano led to a significant improvement of finger control, with a consistent reduction in index finger flexion and middle finger extension.

Jaume Rosset-Llobet, MD*

*Institut de Fisiologia i Medicina de l'Art-Terrassa
Barcelona, Spain*

*E-mail: info@institutart.com

Marc Garcia-Elias, MD

*Institut Kaplan
Barcelona, Spain*

Jordi Montero, MD

*Servei de Neurologia
Hospital Universitari de Bellvitge
Barcelona, Spain*

Josep Valls-Solé, MD

*Servei de Neurologia
Hospital Clínic de Barcelona
Barcelona, Spain*

Álvaro Pascual-Leone, MD

*Berenson-Allen Center for Noninvasive Brain Stimulation
Beth Israel Deaconess Medical Center
Harvard Medical School
Boston, Massachusetts, USA
Institut Guttmann de Neurorehabilitació
Universitat Autònoma
Barcelona, Spain*

References

1. Quartarone A, Siebner HR, Rothwell JC. Task-specific hand dystonia: can too much plasticity be bad for you? *Trends Neurosci* 2006;29:192–199.
2. Leijnse JN. Anatomical factors predisposing to focal dystonia in the musician's hand—principles, theoretical examples, clinical significance. *J Biomech* 1997;30:659–669.
3. Linburg RM, Comstock BE. Anomalous tendon slips from the flexor pollicis longus to the flexor digitorum profundus. *J Hand Surg (Am)* 1979;4:79–83.
4. Hamitouche K, Roux JL, Baeten Y, Allieu Y. Linburg-Comstock syndrome. Epidemiologic and anatomic study, clinical applications. *Chir Main* 2000;19:109–115.
5. Karalezli N, Karakose S, Haykir R, Yagisan N, Kacira B, Tuncay I. Linburg-Comstock anomaly in musicians. *J Plast Reconstr Aesthet Surg* 2006;59:768–771.
6. Candia V, Rosset-Llobet J, Elbert T, Pascual-Leone A. Changing the brain through therapy for musicians' hand dystonia. *Ann NY Acad Sci* 2005;1060:335–342.
7. Schramm A, Reiners K, Naumann M. Complex mechanisms of sensory tricks in cervical dystonia. *Mov Disord* 2004;19:452–458.
8. Tecchio F, Melgari JM, Zappasodi F, et al. Sensorimotor integration in focal task-specific hand dystonia: a magnetoencephalographic assessment. *Neuroscience* 2008;154:563–571.

“Acquired” Hepatocerebral Degeneration in a Patient Heterozygote Carrier for a Novel Mutation in *ATP7B* Gene

Acquired hepatocerebral degeneration (AHD) is a rare type of hepatic encephalopathy characterized by neuropsychiatric symptomatology, and peculiar neuroradiologic findings, without the clinical evidence of Wilson's disease (WD).^{1,2} We studied a patient with AHD responsive to penicillamine who was heterozygote carrier for a novel mutation in the *ATP7B* gene, and discussed the possible role of the mutation in facilitating the appearance of the syndrome.

A 37-year-old man with liver cirrhosis related to chronic hepatitis C was admitted because of progressive consciousness impairment. Family history was negative for WD. Ammonia was 176 $\mu\text{mol/L}$ (NR, 9–33 $\mu\text{mol/L}$); total bilirubin 1.71 mg/dL (NR, 0.2–1.3 mg/dL); serum albumin 2.6 g/dL (NR, 3.3–5 g/dL); AST 62 U/L (NR, 10–45 U/L). Electroencephalogram disclosed diffuse slow wave activity. After rifaximin, lactulose, and branched chain amino acid infusion, his arousal state went back normal in about 12 hours, and ammonia levels decreased to 94 $\mu\text{mol/L}$.

Neurological examination revealed bradykinesia, sialorrhea, dysarthria, mild rest tremor, in the upper limbs, prevalent on the right side, postural instability, and camptocormia. Moreover, he showed depression and anxiety. The MMSE had normal scores (27/30).

Serum ceruloplasmin, cupremia, and cupruria were within the reference values. Ocular slit-lamp examination did not reveal Kayser-Fleischer ring. CSF examination revealed increased manganese concentration (2.9 $\mu\text{g/L}$; NR, 0.88 \pm 0.76 $\mu\text{g/L}$), while copper and iron levels were within normal values. Brain MRI showed increased signal intensity in basal ganglia bilaterally on T1-weighted images (Fig. 1A,B). Levodopa and pramipexole were of no benefit. After informed consent, he was treated with penicillamine 900 mg daily and trihexyphenidyl 2 mg twice daily. In the following 5 days, psychiatric disturbances progressively abated, while bradykinesia,

Published online 9 June 2009 in Wiley InterScience (www.interscience.wiley.com). DOI: 10.1002/mds.22659

- Victor M, Adams RD, Cole M. The acquired (non-Wilsonian) type of chronic hepatocerebral degeneration. *Medicine (Baltimore)* 1965;44:345–394.
- Vrabelova S, Letocha O, Borsky M, Kozak L. Mutation analysis of the ATP7B gene and genotype/phenotype correlation in 227 patients with Wilson disease. *Mol Genet Metab* 2005;86:277–285.
- Lee J, Lacomis D, Comu S, Jacobsohn J, Kanal E. Acquired hepatocerebral degeneration: MR and pathologic findings. *AJNR Am J Neuroradiol* 1998;19:485–487.
- Burkhard PR, Delavelle J, Du Pasquier R, Spahr L. Chronic parkinsonism associated with cirrhosis: a distinct subset of acquired hepatocerebral degeneration. *Arch Neurol* 2003;60:521–528.
- Sechi GP, Cocco GA, Errigo A, et al. Three sisters with very -late-onset major depression and parkinsonism. *Parkinsonism Relat Disord* 2007;13:122–125.
- Murthy RC, Lal S, Sakena DK, et al. Effect of manganese and copper interaction on behavior and biogenic amines in rat fed a 10% casein diet. *Chem Biol Interact* 1981;37:299–308.

Axial Myoclonus in Devic Neuromyelitis Optica



Axial myoclonus identifies spontaneous or sometimes stimulus-sensitive, rhythmic or arrhythmic, flexion or extension movements of the axial muscles of the body which can remain segmentally located (i.e., spinal myoclonus) or instead spread to the limbs excluding the cranially innervated muscles (i.e., propriospinal myoclonus).¹ Focal spinal cord lesions tentatively attributed to demyelination have previously been reported in spinal segmental and propriospinal myoclonus.^{2,3} Herein, we report on axial myoclonus associated with spinal cord lesions in a patient with Devic Neuromyelitis Optica (NMO).

A 32-year-old woman was admitted because of a worsening 8-year history of sporadic abdominal muscles movements which were aggravated by lying down and impeded falling asleep. Medical history included bilateral simultaneous visual loss at age 18 when brain MRI showed multiple cerebral white matter lesions that led to a diagnosis of central nervous system (CNS) demyelinating disease. From the age of 18 to 29 years, seven episodes of optic neuritis recurred, treated with intravenous pulse corticosteroid therapy.

At admission, neurological examination showed bilateral gaze-evoked nystagmus, left arm weakness, diffuse exaggerated tendon reflexes, bilateral Babinski sign, and pallor of optic discs. When the patient was in bed in the supine posture, spontaneous jerky flexion movements symmetrically involved the abdominal wall. Similar jerks could be elicited by taps to the glabella or by auditory stimulation.

Visual-evoked potentials showed prolonged latency bilaterally. Videopolygraphic recordings revealed spontaneous EMG bursts of 100–200 ms in duration recurring many times with

the patient lying supine, with constant recruitment of the rectus abdominis muscles and causing symmetrical abdominal flexion. Jerks could also spread to the intercostalis muscles, the sternocleidomastoideus, and the tibialis anterior muscles, with variable time delays of 35–96 ms (Fig. 1A,B). An estimated propagation velocity along the spinal cord of 8–12 m/s was calculated by dividing the length of the spine from C1 to L2 by the time delays. Auditory stimuli evoked axial propagated jerks with the same EMG pattern (Fig. 1A,B) (see video). EEG back-averaging, triggered on the rectus abdominis muscles, did not show any cortical jerk-related potential.

The axial jerks disappeared during mental arousal and sleep. EMG and nerve conduction velocities were normal. MRI revealed multiple cerebral white matter and intrinsic spinal cord lesions localized at C2 to C7 and D5 to D9 levels (Fig. 1C).

The patient declined lumbar puncture. An elevated titre of aquaporin-4 (AQP4) IgG antibodies was detected in the serum (with a titre expressed as the reciprocal of doubling serum dilution of 1 in 960; normal value: <1 in 60; serum sample tested by the indirect immunofluorescence assay).

The patient refused therapy with immunosuppressive drugs and plasmapheresis. Clonazepam (2 mg/day) and levitiracetam (2000 mg/day) reduced but did not abolish the myoclonic jerks.

In our patient, the recurrent episodes of optic neuritis, the extensive spinal cord lesions, and the AQP4-specific serum auto-antibody led to the diagnosis of NMO with longitudinally extensive myelitis.^{4,5} NMO is a severe demyelinating disease of the CNS that preferentially affects the optic nerve and the spinal cord.⁵ NMO-IgG antibodies recognizing AQP4 seem to play a central role in the pathophysiology of and to account for the pathological lesions and blood-brain barrier dysfunction observed in NMO.⁴ This NMO-IgG biomarker has been incorporated in the clinical NMO diagnostic criteria.^{4,5} In addition to NMO, our patient had axial symmetrical flexion myoclonus with, upon neurophysiological analysis, a T8–T10 spinal origin (rectus abdominis muscle) and a propriospinal rostro-caudal pattern of propagation.¹ The abdominal jerky movements were different from the writhing abdominal contortions with sinuous flowing navel movements observed in the “moving umbilicus syndrome” and “belly dancer’s dyskinesia” and were not due to diaphragmatic flutter. The myoclonus was associated to intrinsic spinal cord lesions on MRI.

Although the pathophysiology of axial myoclonus remains to be fully elucidated, intrinsic spinal cord lesions could be responsible for partial release of a spinal motor generator capable of recruiting muscles via long propriospinal pathways into quasi-rhythmic complex activity.¹ Reports of propriospinal myoclonus as a paraneoplastic presentation⁶ or in the course of paraproteinemic polyneuropathy⁷ militate for a possible role of autoimmunity in spinal cord “damage” and its increased excitability.

LEGEND TO THE VIDEO

Segment 1. Several spontaneous flexion myoclonic jerks (arrow) of the abdominal wall, repeating at irregular intervals, and also induced by auditory bursts.

Roberto Vetrugno, MD, PhD*
Roberto D’Angelo, MD

Additional Supporting Information may be found in the online version of this article.

Published online 9 June 2009 in Wiley InterScience (www.interscience.wiley.com). DOI: 10.1002/mds.22654

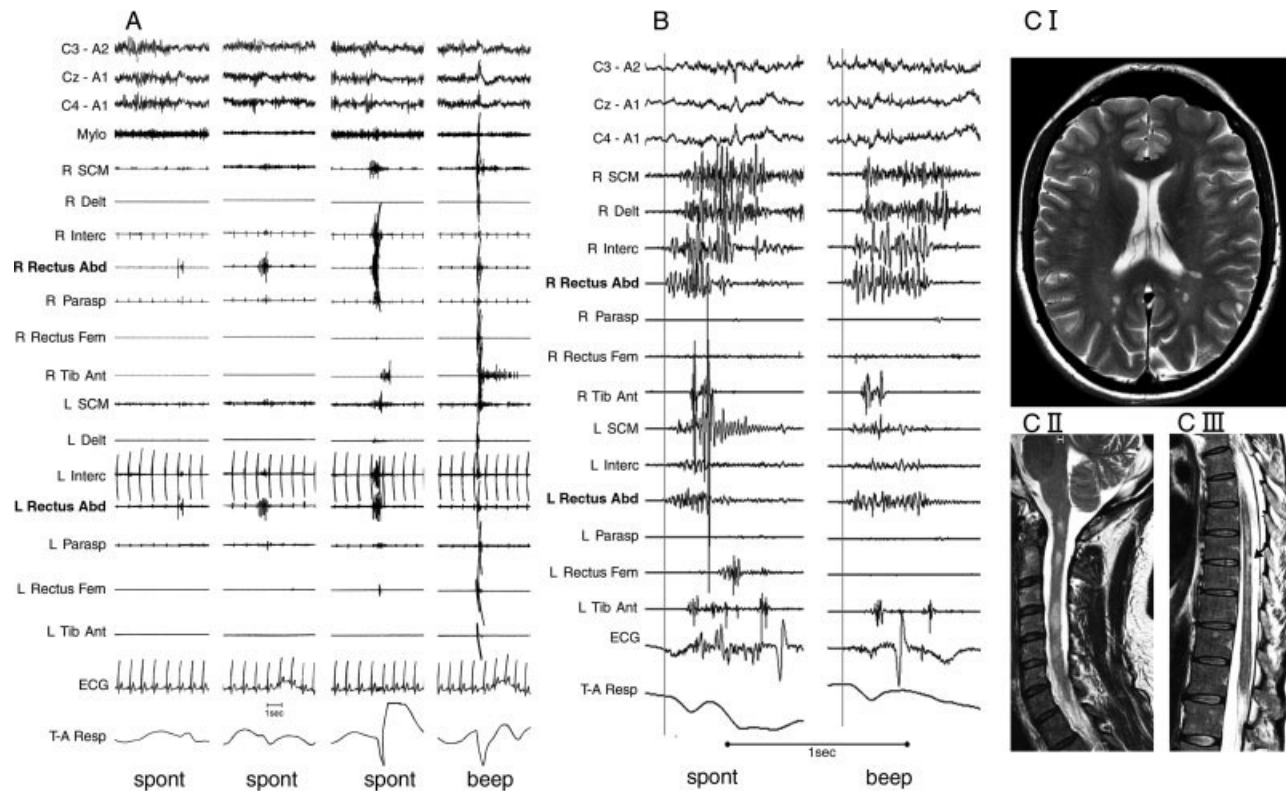


FIG. 1. (A) Polygraphic recording of axial myoclonus, spontaneous (spont) or evoked by auditory stimuli (beep). The myoclonus may be restricted to the rectus abdominis muscles (Rectus Abd), or become propagated to more caudal and rostral muscles. (B) Detailed analysis of the axial myoclonus showing its origin in the rectus abdominis muscles (Rectus Abd) and later propagation to the intercostalis (Interc), right deltoid (Delt), sternocleidomastoideus (SCM), left rectus femoris (Rectus Fem), and tibialis anterior (Tib Ant) muscles. (C) T2 weighted images showing multiple focal hyperintense lesion in the cerebral white matter. (C I), and in the cervical (C II) and thoracic (arrow in C III) spinal cord. Mylo, myloioideus; SCM, sternocleidomastoideus; Delt, deltoideus; Interc, intercostalis; Rectus Abd, rectus abdominis; Parasp, thoraco-lumbar paraspinalis; Rectus Fem, rectus femoris; Tib Ant, tibialis anterior; R, right; L, left.

Maria Alessandria, MD
 Margheita Fabbri, MD
 Rocco Liguori, MD
 Pasquale Montagna, MD
 Department of Neurological Sciences
 University of Bologna
 Bologna, Italy
 *E-mail: roberto.vetrugno@unibo.it

Sergio Stecchi, MD
 Multiple Sclerosis Unit—Cardiovascular Clinical Department
 AUSL Bologna
 Bologna, Italy

Mario Mascalchi, MD
 Radiodiagnostic Section
 Department of Clinical Physiopathology
 University of Florence
 Florence, Italy

References

1. Brown P, Thompson PD, Rothwell JC, Day BL, Marsden CD. Axial myoclonus of spinal origin. *Brain* 1991;114:197–214.
2. Jankovic J, Pardo R. Segmental myoclonus: clinical and pharmacologic study. *Arch Neurol* 1986;43:1025–1031.
3. Kapoor R, Brown P, Thompson PD, Miller DH. Propriospinal myoclonus in multiple sclerosis. *J Neurol Neurosurg Psychiatry* 1992;55:1086–1088.
4. Waters P, Jarius S, Littleton E, et al. Aquaporin-4 antibodies in neuromyelitis optica and longitudinally extensive transverse myelitis. *Arch Neurol* 2008;65:913–919.
5. Wingerchuk DM, Lennon V, Lucchinetti CF, Pittock SJ, Weinshenker BG. The spectrum of neuromyelitis optica. *Lancet Neurol* 2007;6:805–815.
6. Salsano E, Ciano C, Romano S, Cornelio F, Di Donato S, Pareyson D. Propriospinal myoclonus with life threatening tonic spasms as paraneoplastic presentation of breast cancer. *J Neurol Neurosurg Psychiatry* 2006;77:422–424.
7. Vetrugno R, Liguori R, D'Alessandro R, D'Angelo R, Alessandria M, Montagna P. Axial myoclonus in paraproteinemic polyneuropathy. *Muscle Nerve* 2008;38:1330–1335.

Early and Marked Benefit with GPI DBS for Lubag Syndrome Presenting with Rapidly Progressive Life-Threatening Dystonia

Video 

X-linked recessive dystonia parkinsonism (XDP), DYT3, or Lubag syndrome is a neurodegenerative genetic condition caused by a mutation in the TATA-binding protein-associated factor-1 (TAF1). It affects mainly men with maternal ancestry from the Island of Panay in the Philippines. Initial presentation is usually with dystonia gradually being replaced by parkinsonism. Symptoms tend to be refractory to pharmacological treatments. Intracranial surgical procedures were performed without benefit in the past.¹ Evidente et al. reported the first case of XDP with a good and sustained response to pallidal stimulation.² We present a patient with very rapid progressive and life-threatening XDP exhibiting substantial and maintained benefit from bilateral GPi DBS.

A 34-year-old Filipino man presented with a 12-month history of a rapidly progressive dystonia. His maternal family was from Capiz in the Panay Island. The condition started with blepharospasm. Subsequently, he developed dystonia of the neck, arms, trunk, and legs. He lost around 10 kg secondary to presumed oropharyngeal dystonia and increased metabolic demand. Preoperative baseline examination showed generalized dystonia with a Burke-Fahn-Marsden (BFM) dystonia score of 77.5. He also had parkinsonism with a Unified Parkinson's Disease Rating Scale (UPDRS) motor scores of 37 (off-medication) (video, segment 1). Several pharmacological treatments were tried without benefit. Botulinum toxin injections were effective for blepharospasm and retrocollis. The diagnosis of XDP was confirmed genetically by the identification of disease-specific single-nucleotide changes 3 and 12 of the *TAF1* gene.

Quadripolar 3389 DBS electrodes (Medtronic, Minneapolis) were implanted bilaterally under general anesthesia with direct visualization and targeting of the posteroventral GPi on proton density stereotactic MR images. Intraoperative impedance recording was used to delineate gray and white matter boundaries. Postoperative stereotactic MRI confirmed placement of the electrodes within the posteroventral GPi (Fig. 1). DBS electrodes were then connected to a subclavicular subcutaneous neurostimulator (Kinetra, Medtronic).

An immediate improvement was noticed after surgery before switching the stimulation on. Stimulation was started a few days later with further improvement of the dystonia. A temporary percutaneous endoscopy gastrostomy tube was required initially because of concerns over aspiration. Monopolar stimulation of ventral contacts was set at 60 microseconds pulse width and 130 Hertz frequency. Ampli-

tude was progressively increased up to 3.3 Volts at 1 year follow up. Further increments of amplitude produced dysarthria. Switching the stimulation off, with the patient unaware, produced a worsening of the dystonia within seconds and turning it back on provided immediate relief (video, segment 2). Oral pharmacological treatment was discontinued after surgery. At 6 months, the patient was eating normally and had gained 18 kg. At 1 year, BFM dystonia scores was 15 and UPDRS motor scores 8. Trunk dystonia and swallowing difficulties improved the most. Blepharospasm did not respond to stimulation and retrocollis responded only partially and they were treated with botulinum toxin injections (video, segment 3).

Bilateral GPi DBS has shown to be a safe and effective treatment for primary generalized, segmental, and focal dystonia with benefits maintained over time.^{3,4} Although primary dystonia is more responsive to GPi DBS than secondary dystonia, limited data suggest that dystonia in the context of hereditary degenerative conditions, tardive dystonia, dystonia-plus syndromes, or secondary dystonia, may also improve, although to a lesser extent.

GPi DBS produced a marked and sustained improvement on dystonia and parkinsonism in the patient reported here. A lesion-like effect may explain the benefit observed before the stimulation was started. In primary generalized dystonia, a progressive and delayed response to stimulation is usually observed, which implies that the improvement might be in part mediated by cortical reorganization.⁵ An immediate response of dystonia to stimulation has also been reported in other neurodegenerative conditions,^{6,7} including XDP.² It is therefore possible that stimulation-induced neuroplasticity is less relevant in neurodegenerative disorders, and the effect of the stimulation is mainly the result of direct stimulation of the neuronal tissue.

This case study, along with the one reported previously,² suggests that GPi DBS may be a therapeutic, potentially life-saving option for XDP refractory to medication. The adjustability of DBS might be of great value in XDP as symptoms vary as neurodegeneration progresses. Nevertheless, more cases and longer follow up are needed to determine the chronic response to GPi DBS on XDP.

LEGENDS TO THE VIDEO

Segment 1. Preoperative examination. The patient has severe generalized dystonia, with painful trunk opisthotonus especially when lying down. Marked retrocollis is also noticed.

Segment 2. Three months after DBS, in the condition on stimulation and off stimulation. Dystonia recurs immediately after switching the stimulation off.

Segment 3. Six months after pallidal DBS in the condition on stimulation. Generalized dystonia is markedly improved compared to segment 1. Blepharospasm persists and mild retrocollis is also noticed.

Acknowledgments: This work was undertaken at University College London Hospitals and University College London (UCLH/UCL) with a proportion of funding from the Department of Health's National Institute for Health Research (NIHR) Biomedical Research Centres funding scheme. The Unit of Functional Neurosurgery is supported

Additional Supporting Information may be found in the online version of this article.

Published online 9 June 2009 in Wiley InterScience (www.interscience.wiley.com). DOI: 10.1002/mds.22656

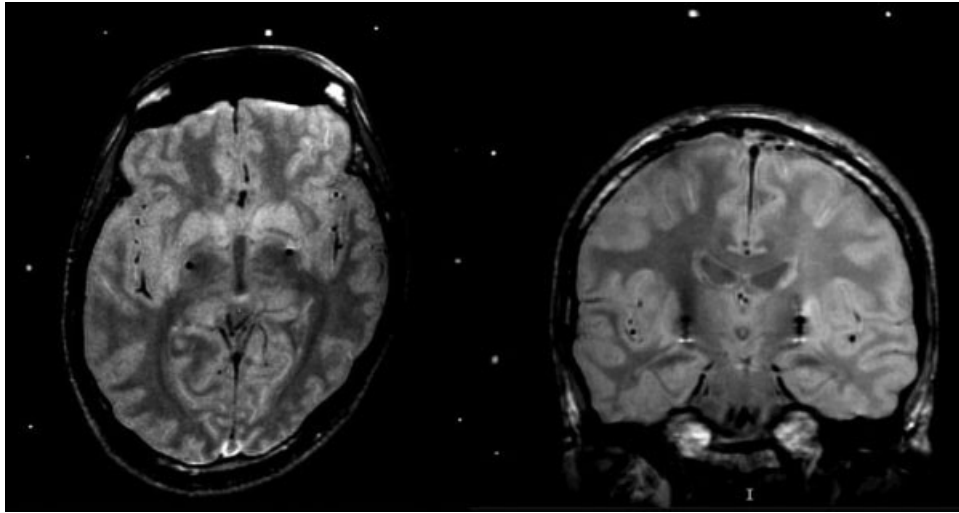


FIG. 1. Proton density axial and coronal stereotactic MR images showing the DBS electrodes located bilaterally in the posteroventral internal globus pallidus. Note the plagioccephaly and resulting asymmetry of the basal ganglia that would have rendered indirect targeting extremely inaccurate.

by the Parkinson's Appeal. I.M.T. is supported by a grant from the Fondo de Inversion Sanitaria (FIS), Instituto de Salud Carlos III, Spanish Department of Science and Innovation (FI08/00108).

Financial Disclosure: M. Hariz and L. Zrinzo have occasionally received travel grants and honoraria from Medtronic for lecturing at meetings.

Irene Martinez-Torres, MD*
 Patricia Limousin, MD, PhD
*Unit of Functional Neurosurgery
 Sobell Department of Motor Neuroscience
 and Movement Disorders
 UCL, Institute of Neurology
 Queen Square, London
 United Kingdom*
 *E-mail: i.torres@ion.ucl.ac.uk

Steve Tisch, MBBS, PhD
*Department of Neurology
 St. Vincent's Hospital
 Sydney, Australia*

Rupert Page, MRCP
*Department of Neurology
 Poole Hospital NHS Foundation Trust
 Poole, United Kingdom*

Ashwin Pinto, FRCP, DPhil
*Department of Neurology
 Wessex Neurological Centre
 Southampton General Hospital
 United Kingdom*

Thomas Foltynie, MRCP, PhD
*Unit of Functional Neurosurgery
 Sobell Department of Motor Neuroscience
 and Movement Disorders
 UCL, Institute of Neurology
 Queen Square, London
 United Kingdom*

Kailash P. Bhatia, FRCP
*Sobell Department of Motor Neuroscience
 and Movement Disorders
 UCL, Institute of Neurology
 Queen Square, London
 United Kingdom*

Marwan I. Hariz, MD, PhD
 Ludvic Zrinzo, MD, MSc, FRCS (Ed)
*Unit of Functional Neurosurgery
 Sobell Department of Motor Neuroscience
 and Movement Disorders
 UCL, Institute of Neurology
 Queen Square, London
 United Kingdom*

References

1. Lee LV, Maranon E, Demaisip C, et al. The natural history of sex-linked recessive dystonia parkinsonism of Panay, Philippines (XDP). *Parkinsonism Relat Disord* 2002;9:29–38.
2. Evidente VG, Lyons MK, Wheeler M, et al. First case of X-linked dystonia-Parkinsonism (“Lubag”) to demonstrate a response to bilateral pallidal stimulation. *Mov Disord* 2007;22:1790–1793.

3. Kupsch A, Benecke R, Müller J, et al. Deep-brain stimulation for Dystonia Study Group. Pallidal deep-brain stimulation in primary generalized or segmental dystonia. *N Engl J Med* 2006;9;355:1978–1990.
4. Vidailhet M, Vercueil L, Houeto JL, et al. French SPIDY Study Group. Bilateral pallidal deep-brain stimulation in primary generalised dystonia: a prospective 3 year follow-up study. *Lancet Neurol* 2007;6:223.
5. Tisch S, Rothwell JC, Bhatia KP, et al. Pallidal stimulation modifies after-effects of paired associative stimulation on motor cortex excitability in primary generalized dystonia. *Exp Neurol* 2007;206:80–85.
6. Umemura A, Jaggi JL, Dolinskas CA, Stern MB, Baltuch GH. Pallidal deep brain stimulation for longstanding severe generalized dystonia in Hallervorden-Spatz syndrome: case report. *J Neurosurg* 2004;100:706–709.
7. Hebb M, Garcia R, Gaudet P, Mendez I. Bilateral stimulation of the globus pallidus internus to treat choreathetosis in Huntington's disease: technical case report. *Neurosurgery* 2006;58: E383.