

molecule, compared to 3 for N-AA at 2.02 ppm. If one assumes an N-AA concentration of 7 mM, a peak 3.75 times that of N-AA could arise from a FFA/DAG concentration of no more than 1 to 2 mM/kg. The Siesjo study (referenced by Dr Detre) found a peak FFA concentration of 0.44 mM/kg but did not measure DAG. We have not claimed that the lipid signal we observe definitely arises from phosphatidylinositol breakdown products, but simply suggested that it is one reasonable mechanism to account for the result; the numbers above seem to us consistent with that suggestion.

We would summarize as follows: Not only do the ^1H MRS resonances of lactate and lipid overlap, but the potential causes of increases in brain concentrations of the two metabolites may also overlap. A recent report [4] demonstrated that it is not sufficient to report lactate increase at long TE [5] without having looked for possible simultaneous lipid increases at short TEs.

Neurology Department
Harvard Medical School
Boston, MA
McLean Hospital
Belmont, MA

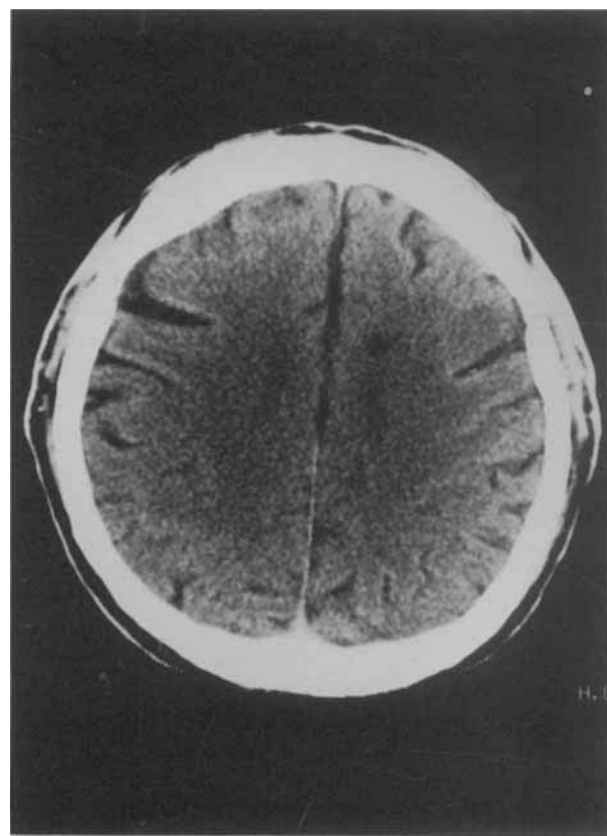
References

1. Woods BT, Chiu T-M. In vivo ^1H spectroscopy of the human brain following electroconvulsive therapy. *Ann Neurol* 1990; 28:745-749
2. Bruhn H, Frahm J, Glyngell ML, et al. Cerebral metabolism in man after acute stroke: new observations using localized proton NMR spectroscopy. *Magn Reson Med* 1989;9:126-131
3. Derome AE. Modern NMR techniques for chemistry research. New York: Pergamon Press, 1987:114-116
4. Sotak CH, Alger JR. A pitfall associated with lactate detection using stimulated-echo proton spectroscopy. *Magn Reson Med* 1991;17:533-538
5. Detre JA, Wang Z, Bogdan AR, et al. Regional variation in brain lactate in Leigh syndrome by localized ^1H magnetic resonance spectroscopy. *Ann Neurol* 1991;29:218-221

The Dysarthria-Clumsy Hand Syndrome: Ataxic or Bradykinetic Hand?

F. Grandas, MD, J. A. Villanueva, MD, D. Mateo, MD, and S. Gimenez-Roldán, MD

The term *dysarthria-clumsy hand syndrome* (DCHS) was coined by Fisher [1] to identify a lacunar stroke characterized chiefly by the combination of dysarthria and "clumsiness" of one hand. It is commonly related to small infarcts in the basis pontis [2, 3], but other anatomical localizations have been suggested [4]. "Clumsiness," however, is a vague term whose actual nature has not been precisely defined. It was initially described as "awkwardness, slowness of fine manipulations, difficulty in writing, wavering ataxia on the finger-nose test not clearly cerebellar in type. . ." [1] and no further clarification was made in a more recent review of the topic [5].



CT scan performed 2 days after the onset of symptoms showing a small, well-defined area of hypodensity in the subcortical white matter underneath the left SMA.

Glass and associates [2] reported a consistent clinical-anatomical correlation in patients with the DCHS. In their series "clumsiness" was regarded as a cerebellar type ataxia. All patients were found to have small infarcts in the contralateral basis pontis by magnetic resonance imaging. These authors suggested a disruption of cerebellar pathways as the main pathophysiological mechanism of the DCHS.

We describe a patient with the DCHS whose clumsiness was the consequence of focal bradykinesia caused by a lacunar infarct underlying the left supplementary motor area (SMA). A 62-year-old diabetic man was admitted to the Hospital General Gregorio Marañón in October 1989 because of transient diplopia. At that time the neurological examination and a brain computed tomography (CT) scan were normal. He was readmitted in June 1990 complaining of slurred speech and clumsiness of the right hand of sudden onset. On examination his mental status was normal and there was no buccofacial apraxia nor facial weakness. Speech was slow and dysarthric without dysphasic elements. There was slight pronation of the outstretched right arm, but power was normal in both proximal and hand muscles. Tendon reflexes were symmetrical but a transient right Babinski sign was found. There was no sensory loss. He performed extremely slowly simple repetitive, sequential, and alternate movements with the right hand. The patient could manipulate objects with this hand but in a slow and inefficient manner, and writing

was micrographic. There was no ataxia in the finger-to-nose and heel-to-knee tests. Gait was normal, although a reduced right arm swing was observed. There was no tremor and muscle tone was normal. Formal tests for apraxia did not show significant abnormalities. A brain CT scan showed an area of hypodensity in the subcortical white matter in the left hemisphere underlying the SMA (Fig). The patient was discharged 3 weeks later with a right hand motor function nearly normal.

This case illustrates a variant of DCHS, different in its anatomical and pathophysiological basis from that of Glass and associates [2]. Our patient's clumsiness was in fact bradykinesia, probably related to the lesion underneath the SMA, which may produce deafferentation of this area of the frontal cortex from the basal ganglia [6]. Indeed, patients with SMA lesions may experience difficulty in performing simple but mainly simultaneous and sequential movements, showing a motor disorder similar to that of patients with Parkinson's disease [6, 7].

We believe that the DCHS should be more precisely defined. Terms such as "dysarthria-ataxic hand" or "dysarthria-bradykinetic hand" might be useful to improve clinical-anatomical correlations.

*Servicio de Neurología
Hospital General "Gregorio Marañón"
Madrid, Spain*

References

1. Fisher CM. A lacunar stroke. The dysarthria-clumsy hand syndrome. *Neurology* 1967;17:614-617
2. Glass JD, Levey AI, Rothstein JD. The dysarthria-clumsy hand syndrome: a distinct clinical entity related to pontine infarction. *Ann Neurol* 1990;27:487-494
3. Arboix A, Martí-Vilalta JL, García JH. Clinical study of 227 patients with lacunar infarcts. *Stroke* 1990;21:842-847
4. Orgogozo JM, Bogousslavsky J. Lacunar syndromes. In: Vinken PJ, Bruyn GW, Klawans HL, eds. *Vascular diseases part II. Handbook of clinical neurology*. Amsterdam: Elsevier, 1989;54: 235-271
5. Fisher CM. Lacunar strokes and infarcts: a review. *Neurology* 1982;32:871-876
6. Dick JP, Benecke R, Rothwell JC, et al. Simple and complex movements in a patient with infarction of the right supplementary motor area. *Movement Dis* 1986;1:255-266
7. Benecke R, Rothwell JC, Dick JP, et al. Performance of simultaneous movements in patients with Parkinson's disease. *Brain* 1986;109:739-757

Reply

Jonathan D. Glass, MD, Allan I. Levey, MD, PhD,
and Jeffrey D. Rothstein, MD, PhD

We appreciate the comments of Grandas and associates [1] regarding the localization of lesions responsible for the dysarthria-clumsy hand syndrome. We believe that the case outlined in their letter illustrates a major point of our paper [2], that a distinctive clinical picture, based on the precise definition of findings, predicts a lesion in the basis pontis. Specifically, our methods section describes the inclusion criteria used for identifying patients with the dysarthria-clumsy hand syndrome. All of our patients had "central" facial weak-

ness and "clumsiness" which appeared as ataxic movements. The patient described by Grandas and associates did not have facial weakness and his motor abnormality is characterized as "bradykinetic," without ataxia. Therefore, we would not have labeled this patient as having the dysarthria-clumsy hand syndrome. Also, this patient's lesion was defined solely by computed tomography. Although we would not have predicted a lesion in the basis pontis, the lack of magnetic resonance images (MRIs) makes it difficult to exclude other lesions.

We agree that the clinical syndromes in question need to be more precisely defined, as we have done for the dysarthria-clumsy hand syndrome. The introduction of MRI technology into everyday practice allows us to localize precisely small lesions in the brain. If we are to use this technology to further our understanding of how the brain works, it behooves us to categorize and quantitate neurological dysfunction better, so that the "clinical" can approach the accuracy of the "anatomical" in the clinical-anatomical correlation.

*Neuropathology Laboratory
The Johns Hopkins University School of Medicine
Baltimore, MD*

References

1. Grandas F, Villanueva JA, Mateo D, Gimenez-Roldan S. The dysarthria-clumsy hand syndrome: ataxic or bradykinetic hand? *Ann Neurol* 1991;30:430-431
2. Glass JD, Levey AI, Rothstein JD. The dysarthria-clumsy hand syndrome: a unique clinical entity related to pontine infarction. *Ann Neurol* 1990;27:487-494

Does a Retrovirus Cause Amyotrophic Lateral Sclerosis?

W. King Engel, MD

In their review of earlier amyotrophic lateral sclerosis (ALS) patients having lymphoma, Younger and associates [1] cited our 1964 article [2] describing a patient with lymphosarcoma (malignant lymphoma). We point out that autopsy confirmation of his degeneration in the corticospinal tracts and lower motor neurons was subsequently illustrated [3]. Younger and colleagues raised the question of a retrovirus causing both disorders in their 9 patients plus 23 from the literature. Another of our early patients [2, 3] had chronic lymphocytic leukemia, which also can be caused by a retrovirus.

From a different approach, I have also recently raised the question of a retrovirus causing ALS. Based on a comparison of ALS with human T-lymphotropic virus type I (HTLV-I)-associated myelopathy (HAM) (Table) [4], my suggestion was that there may be a putative "human ALS virus (HAV)," which in different patients can act (1) directly on neurons, (2) indirectly through a metabolic mechanism involving intermediate Cells-X, or (3) indirectly through a dysimmune mechanism.