

B. Wildemann, MD  
S. Jarius, MD  
M. Hartmann, MD  
J.U. Regula, MD  
C. Hametner, MD

### ACUTE DISSEMINATED ENCEPHALOMYELITIS FOLLOWING VACCINATION AGAINST HUMAN PAPILLOMA VIRUS

We report a case of severe encephalitis evolving shortly after administration of a new vaccine against human papilloma virus (HPV) recently approved for the prevention of diseases caused by HPV types 6, 11, 16, and 18.

**Case report.** A 20-year-old woman developed headache, nausea, vomiting, and diplopia within 28 days of the second immunization with the quadrivalent HPV vaccine Gardasil<sup>®</sup>. She did not report signs of a preceding infection. On neurologic examination, the patient was without focal deficits. Cranial MRI showed multifocal white matter edema with abnormal patchy or streaky contrast enhancement along deep venular structures. CSF analysis disclosed 80 cells/ $\mu$ L consisting of lymphocytes and 2% eosinophils, increased total protein (0.8 g/L) and immunoglobulin M ratio, no oligoclonal bands (OCB), and normal lactate. Serology and PCR ruled out an infectious etiology with negative testing for *Borrelia*, *Treponema*, *Listeria*, herpes simplex virus 1/2, varicella zoster virus, human herpesvirus 6, HIV, enterovirus, and arbovirus. Laboratory screening revealed elevated antinuclear (1:320; ANA) and antithyroglobulin (445 IU/mL; normal  $\leq$ 60) antibodies, and increased thyroid-stimulating hormone (5.2 mU/L; normal 0.4–4). ANA subspecificities, neutrophil cytoplasmic, cardiolipin, and aquaporin-4 antibodies, and routine laboratory studies were negative. Visual evoked potentials, ultrasound imaging of cerebral vessels, abdominal ultrasound, and echocardiography revealed nothing of note. Acute disseminated encephalomyelitis (ADEM) was thought to be the most likely cause of clinical symptoms and treatment with  $5 \times 1,000$  mg IV methylprednisolone (IVMP) followed by oral tapering was initiated. One month after cessation of corticosteroids, headache and vomiting recurred, and the patient experienced two generalized seizures. Repeat MRI showed swelling of nearly the entire subcortical white matter as well as left frontal and left temporal microbleeds (figure). The CSF had persistent lymphocytic pleocytosis (213 cells/ $\mu$ L), intrathecal synthesis of IgM and IgA, and negative OCB. One week after retreatment with high dose IVMP ( $1 \times 500$  mg,  $3 \times 1,000$  mg) supplemented by glycerol and levetiracetam the patient presented with lethargy, irritability, paraesthesia of the left hand, and papilledema. MRI demonstrated regressive subcortical edema but a novel contrast-

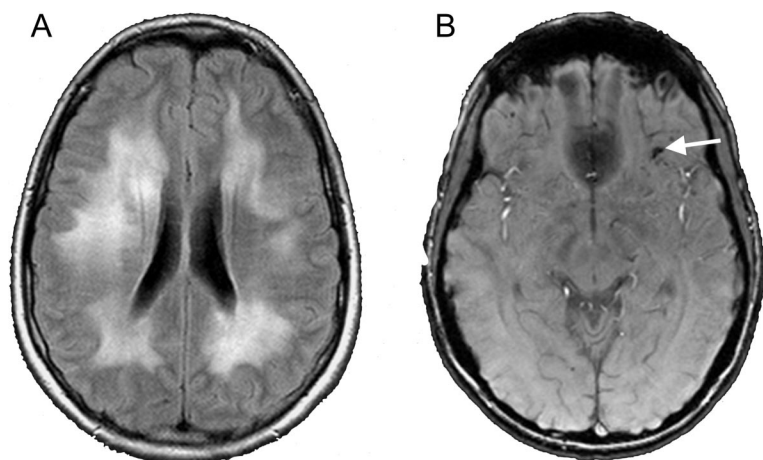
enhancing lesion located in the pons. CSF cells were 149/ $\mu$ L; OCB remained negative. A third course of  $5 \times 1,000$  mg IVMP with subsequent oral treatment for several weeks (80 mg initially followed by tapering at weekly intervals) led to resolution of clinical symptoms and marked improvement of MRI abnormalities. However, while on maintenance treatment with 2 mg methylprednisolone daily, the patient developed gait instability together with multifocal white matter lesions finally requiring immunosuppression with cyclophosphamide. The third immunization with Gardasil<sup>®</sup> scheduled at month 6 after the first dosing was cancelled.

**Discussion.** This previously healthy woman (HLA status: A\*01; B\*08; Cw\*06; DRB1\*03; DQB1\*02, DQA1\*0501; A\*24; B\*13; Cw\*07; DRB1\*07; DQB1\*02; DQA1\*0201) presented with signs of raised intracranial pressure, seizures, and mental changes in close temporal proximity to the second administration of the HPV vaccine Gardasil<sup>®</sup>. The encephalopathy evolved over several months and was incompletely responsive to repetitive courses of high-dose corticosteroids. This coincided radiologically with progressive edema involving almost the entire subcortical hemispheres and the successive appearance of multifocal white matter lesions and several small hemorrhages.

Although a causal link between both events cannot be definitely established, the close temporal association as well as the protracted clinical course, the repeated absence of OCB despite sustained inflammatory CSF changes, and the dramatic imaging abnormalities including microbleeds suggest an aggressive form of ADEM possibly induced by Gardasil<sup>®</sup> mediated immune activation in our patient.

In a large epidemiologic study, vaccination was found to precede ADEM in around 5% of cases.<sup>1</sup> As in our case, symptoms tend to occur after booster vaccination rather than after first application. Recently, Sutton et al.<sup>2</sup> reported five cases of an inflammatory CNS disorder following booster vaccination with Gardasil<sup>®</sup>. However, contrasting with our patient, four individuals had already experienced previous symptoms suggestive of a first demyelinating event and were thus diagnosed with or subsequently developed multiple sclerosis. Moreover, cranial MRI findings were less severe in those patients with no edema or bleeding. CSF cell counts were reported in one patient and were only slightly elevated and asso-

**Figure** Follow-up MRI 2 months after disease onset



Follow-up MRI 2 months after disease onset shows progressive hyperintense lesions on fluid-attenuated inversion recovery-weighted images (A) and a new left frontal hemorrhage on susceptibility-weighted MRI (B, arrow).

ciated with persistent OCB, which were not present in our case.

Pathophysiologically ADEM has been linked to experimental allergic encephalomyelitis (EAE). An autoimmune type demyelinating disorder, EAE was first elicited after immunization of monkeys with a rabies vaccine preparation containing CNS tissue.<sup>3</sup> Thus, molecular mimicry between vaccine epitopes and neural antigens with subsequent activation of cross-reactive immune cells is the favored pathomechanism underlying the CNS-specific autoim-

mune process in EAE and postimmunization ADEM.<sup>4</sup>

We describe a further case of CNS inflammation occurring after vaccination with Gardasil<sup>®</sup> shortly after its approval for broad usage in girls and young women for the prevention of HPV-associated conditions, indicating that increased vigilance and eventually phase IV studies are warranted to recognize further neurologic complications.

*From the Divisions of Molecular Neuroimmunology (B.W., S.J., J.U.R., C.H.) and Neuroradiology (M.H.), Department of Neurology, University of Heidelberg, Germany.*

*Disclosure: The authors report no disclosures.*

*Received November 28, 2008. Accepted in final form February 10, 2009.*

*Address correspondence and reprint requests to Prof. Dr. Brigitte Wildemann, Division of Molecular Neuroimmunology, Department of Neurology, University of Heidelberg, Heidelberg, Germany; [brigitte.wildemann@med.uni-heidelberg.de](mailto:brigitte.wildemann@med.uni-heidelberg.de)*

Copyright © 2009 by AAN Enterprises, Inc.

1. Leake JA, Albani S, Kao AS, et al. Acute disseminated encephalomyelitis in childhood: epidemiologic, clinical and laboratory features. *Pediatr Infect Dis J* 2004;23:756–764.
2. Sutton I, Lahoria R, Tan I, Clouston P, Barnett M. CNS demyelination and quadrivalent HPV vaccination. *Mult Scler* 2009;15:116–119.
3. Baxter AG. The origin and application of experimental autoimmune encephalomyelitis. *Nat Rev Immunol* 2007;7:904–912.
4. Tenembaum S, Chitnis T, Ness J, Hahn JS. Acute disseminated encephalomyelitis. *Neurology* 2007;68:S23–S36.

## Did You Know . . .

. . . you can browse by subspecialty topics on [www.neurology.org](http://www.neurology.org)?

Go to: <http://www.neurology.org/collections> and click on the specific topic for a complete list of articles.

# Neurology<sup>®</sup>

## ACUTE DISSEMINATED ENCEPHALOMYELITIS FOLLOWING VACCINATION AGAINST HUMAN PAPILLOMA VIRUS

B. Wildemann, S. Jarius, M. Hartmann, et al.

*Neurology* 2009;72;2132-2133

DOI 10.1212/WNL.0b013e3181aa53bb

**This information is current as of June 15, 2009**

|   |   |
|---|---|
| <b>Updated Information &amp; Services</b> | including high resolution figures, can be found at:<br><a href="http://www.neurology.org/content/72/24/2132.full.html">http://www.neurology.org/content/72/24/2132.full.html</a>  |
| <b>References</b>                         | This article cites 4 articles, 2 of which you can access for free at:<br><a href="http://www.neurology.org/content/72/24/2132.full.html##ref-list-1">http://www.neurology.org/content/72/24/2132.full.html##ref-list-1</a>  |
| <b>Citations</b>                          | This article has been cited by 7 HighWire-hosted articles:<br><a href="http://www.neurology.org/content/72/24/2132.full.html##otherarticles">http://www.neurology.org/content/72/24/2132.full.html##otherarticles</a>   |
| <b>Subspecialty Collections</b>           | This article, along with others on similar topics, appears in the following collection(s):<br><b>Coma</b><br><a href="http://www.neurology.org/cgi/collection/coma">http://www.neurology.org/cgi/collection/coma</a><br><b>Critical care</b><br><a href="http://www.neurology.org/cgi/collection/critical_care">http://www.neurology.org/cgi/collection/critical_care</a><br><b>DWI</b><br><a href="http://www.neurology.org/cgi/collection/dwi">http://www.neurology.org/cgi/collection/dwi</a><br><b>Gastrointestinal</b><br><a href="http://www.neurology.org/cgi/collection/gastrointestinal">http://www.neurology.org/cgi/collection/gastrointestinal</a><br><b>MRI</b><br><a href="http://www.neurology.org/cgi/collection/mri">http://www.neurology.org/cgi/collection/mri</a> |
| <b>Permissions &amp; Licensing</b>        | Information about reproducing this article in parts (figures, tables) or in its entirety can be found online at:<br><a href="http://www.neurology.org/misc/about.xhtml#permissions">http://www.neurology.org/misc/about.xhtml#permissions</a>   |
| <b>Reprints</b>                           | Information about ordering reprints can be found online:<br><a href="http://www.neurology.org/misc/addir.xhtml#reprintsus">http://www.neurology.org/misc/addir.xhtml#reprintsus</a>   |

*Neurology*® is the official journal of the American Academy of Neurology. Published continuously since 1951, it is now a weekly with 48 issues per year. Copyright . All rights reserved. Print ISSN: 0028-3878. Online ISSN: 1526-632X.

