

Othello Syndrome Secondary to Right Cerebrovascular Infarction

Emily D. Richardson, PhD; Paul F. Malloy, PhD; Janet Grace, PhD

Abstract

The Othello syndrome, or delusional jealousy, occurs in idiopathic psychoses and in neurodegenerative diseases, but has rarely been described in patients with cerebrovascular infarction. A patient was observed to exhibit the delusion shortly after cerebral ischemic injury in the absence of other psychiatric symptoms. The underlying pathology was consistent with recent reports on content-specific delusions, implicating right hemisphere and frontal lobe involvement in the misinterpretation and misidentification of complex information. Psychological factors were hypothesized to shape the content of the delusional misinterpretations. (*J Geriatr Psychiatry Neurol* 1991;4:160-165).

The Othello syndrome, or delusional jealousy, is a content-specific delusion characterized by the unshakable but false conviction of the spouse's infidelity.¹ By definition, this delusion is often persistent, unremitting, and totally unresponsive to discussion or argument. It has been reported to occur most often in association with chronic alcoholism² and as a feature of schizophrenia or affective disorder.³ There is little information regarding the incidence of this disorder. However, Crowe and his colleagues⁴ found that paranoid jealousy occurred in 0.17% of all admissions to a psychiatric facility over a 61-year period.

As the syndrome is generally viewed as a "functional" psychosis, most previous reports have focused on possible dynamic or intrapsychic causes for the delusions.¹ Delusional jealousy secondary to demonstrable or presumed cerebral dysfunction has only recently been described.^{5,6} It has been most often mentioned in conjunction with diffuse or degenerative disease, such as Alzheimer's dementia and Huntington's chorea.⁷ In these reports, however, little information has been provided regarding premorbid psychological status, development and

course of the illness, or neuroradiologic and neuropsychological findings. Furthermore, although morbid jealousy has been clinically observed in association with the general paranoid reactions of postinfarction aphasia, there has been a dearth of published reports on this association.

We present the case of a previously happily married elderly man who developed the delusion of his wife's infidelity shortly following recovery from a large right middle cerebral artery infarction. The current case represents the first complete report of the Othello syndrome developing secondary to a focal structural cerebral lesion. Key features of the syndrome, which are not discernible in previous reports on organic cases, are described, including the extent to which the delusion was (1) persistent, rather than merely a transient symptom; (2) monosymptomatic, ie, not imbedded in the context of general paranoia; and (3) incongruent with premorbid personality functioning. Furthermore, the neuroradiologic findings, described below, are consistent with the burgeoning neuropsychiatric literature on other content-specific delusions that implicate right hemisphere pathology superimposed on dysfunctional frontal systems.⁸

Received Dec 29, 1990. Received revised Feb 26, 1991. Accepted for publication April 11, 1991.

From the Department of Psychiatry (Drs Richardson, Malloy, and Grace), Brown University Medical School, and Butler Hospital (Drs Richardson and Malloy), Providence, and Memorial Hospital of Rhode Island (Dr Grace), Pawtucket, RI.

Address correspondence to Dr Emily D. Richardson, Assistant Clinical Professor, Department of Psychiatry, Butler Hospital, 345 Blackstone Boulevard, Providence, RI 02906.

Case Description

Presentation

A 68-year-old, right-handed, married male was admitted to the psychiatric facility for evaluation of ag-

gressive behavior toward his wife, whom he believed was having an affair with their 25-year-old neighbor. The patient developed the belief of his wife's infidelity shortly after a right cerebrovascular infarction 1 year earlier. He became impotent after the infarction, and a urologic consult discovered no other identifiable medical etiology. The patient became suspicious of the alleged affair when he began "putting together" evidence from various sources. For example, he noticed that his wife began leaving the first floor bedroom window open at night, presumably to allow her "lover" to enter the room while the patient was asleep. He found tracks in the snow beneath the window, and he noticed that the dust was disturbed on the window sill, which he took as evidence that the neighbor had entered through the window. On one occasion, he thought he had heard voices in the kitchen, but when he entered the room, only his wife was there preparing breakfast. The patient assumed that his wife had been making breakfast for the neighbor, who fled through the front door on hearing the patient's approach. When asked why he thought his wife would be interested in the neighbor, the patient stated that he recalled his wife remarking that "that boy is a nice-looking fellow." On another occasion, the patient discovered that his neighbor had generously offered to perform routine chores around the couple's home, including fertilizing their lawn. The patient's physical disabilities prevented him from performing such chores, and he interpreted this gesture as a threat to his marriage.

In response to the patient's accusations, his wife began severely restricting her activities. She became fearful of getting up at night to go to the bathroom because the patient often awoke to reassert his belief that she was getting up to meet with her lover. Furthermore, despite his impotence, he became sexually aggressive with his wife, repeatedly approaching her whenever she came to bed and demanding verbally and physically that she engage in intercourse with him. His advances would keep his wife awake all night, so that she eventually moved to a second bedroom, a decision that was interpreted by the patient as further proof that his wife was having an affair. Psychiatric hospitalization was finally precipitated by the patient's increased threats to assault his wife if she did not discontinue her alleged affair. At one point, the patient became angered at her denials of infidelity, and he tried to strike her with his cane, finally throwing it at her.

Confrontation with the illogical aspects of the patient's belief did not sway his conviction. For ex-

ample, the patient was confronted with the age discrepancy between the neighbor (age 25 years) and the patient's wife (in her early 60s); however, he responded by stating that his wife was an attractive woman who "had needs." The fact that the neighbor was a newlywed also did not seem to sway the patient's belief in the affair, as he merely contended that the neighbor's new bride was also having an affair with another neighbor.

Medical History

The patient had no previous psychiatric history or family history of psychiatric disorder. He denied alcohol or other substance abuse, and developmental history was unremarkable. The patient and his wife denied marital difficulties prior to the infarction. In fact, they described their marriage as "ideal" and stated that they had always had an active and mutually satisfying sexual relationship. The opinion that this couple had a jealousy-free marriage was corroborated by this couple's adult children. The patient and his wife had just completed a trip abroad when the patient suffered left-sided hemiparesis, with left facial droop and loss of motor strength and sensation in the upper and lower extremities on the left. The patient was hospitalized at a medical facility where it was determined that he had a cerebrovascular accident, likely embolic in nature. Computed tomography (CT) scan demonstrated infarction in the right middle cerebral artery territory. He underwent physical rehabilitation and, within 2 months after recovery, the patient developed delusional jealousy. The couple became involved in marital counseling, but little change in the patient's delusion over the course of 6 months was noted. Increasing dosages of antidepressant (nortriptyline and trazodone) and neuroleptic medications (haloperidol and molindone hydrochloride) were tried, with either little lasting effect or exacerbation of symptoms.

Medical history, in addition to the cerebral ischemic injury, was significant for atherosclerotic cardiovascular disease, controlled hypertension, myocardial infarction (10 years previous to this illness), gout, and duodenal ulcer. Five months after the cerebrovascular event (and 3 months after the development of the delusion), the patient experienced a 4-minute episode of involuntary movement of the right upper extremity, which stopped spontaneously. There was no associated loss of consciousness, incontinence, or drowsiness/lethargy, and voluntary movements were noted throughout this period. He was thought to have had a focal motor seizure and was placed on phenytoin, 100 mg qid.

Records indicating whether an electroencephalogram (EEG) was done at that time could not be obtained (a subsequent EEG is described below). There were no other episodes or previous history of seizures. On admission to the psychiatric facility, medications included haloperidol (1 mg prn), phenytoin, cimetidine (for ulcer), baclofen (muscle relaxant), and acebutolol hydrochloride (for hypertension).

Psychiatric Evaluation

Psychiatric examination was notable for depressed affect, decreased thought productivity, and generalized anxiety, with prominent preoccupation regarding his wife's alleged infidelity. On admission, he obtained a 26/30 on the Mini-Mental State Examination,⁹ having lost points for orientation, recall of items, and copy of a design.

Neurologic Evaluation

Examination revealed left-sided spastic hemiparesis, bilateral hyperreflexia greater on the left, positive Babinski reflex on the left, flattened facial expression on the left, and labile affect. The patient was found to have a left lower quadrant visual field cut and a left-sided extinction to double simultaneous stimuli. A tendency to neglect both the left and bilateral lower visual fields was exhibited. He exhibited left hemiparesis, with an awkward gait, and he required use of a cane to ambulate. An EEG was notable for lateralizing disturbance in the right hemisphere, consistent with a structural abnormality, and bifrontal generalized slowing with bisynchronous spike phenomenon, suggesting associated changes at the deep midline pacemaker level. A repeat CT scan was consistent with the patient's history, revealing an old, large ischemic infarct affecting frontal, temporal, and parietal lobes on the right (Figure 1). Other findings included mild generalized cortical atrophy. There were no structural abnormalities evident in the left hemisphere.

Laboratory Evaluation

Laboratory evaluations, including complete blood count, electrolytes, blood urea nitrogen, creatinine, serum vitamin B₁₂ and folate levels, thyroid function tests, serum iron, and iron binding capacity were all normal, with the exception of extreme elevations in alkaline phosphatase, presumably secondary to phenytoin.

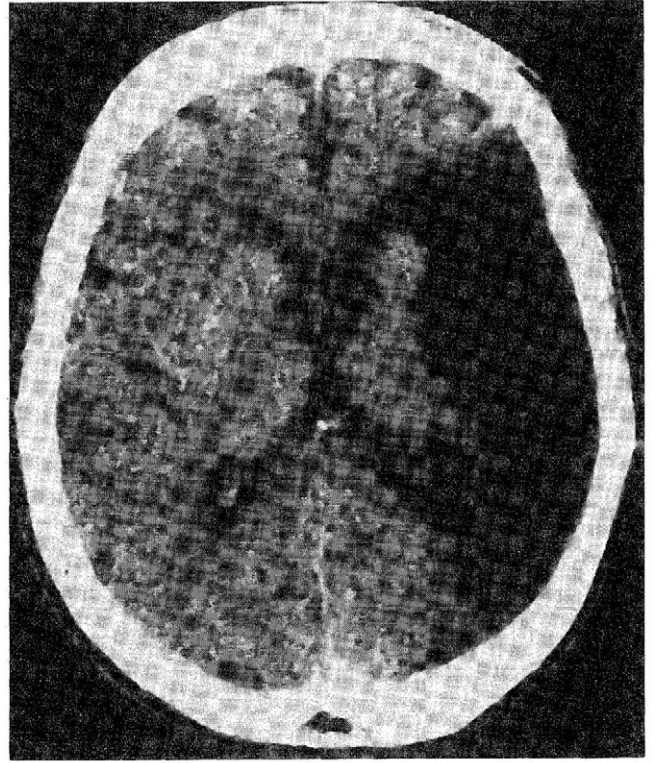


FIGURE 1

Representative CT scan section demonstrating a large low-density defect in the right hemisphere involving frontal, temporal, and parietal lobes. (Right side of image corresponds to right hemisphere.)

Neuropsychological Evaluation

The patient was well oriented, and basic attention was normal. His speech was mildly dysarthric but fluent with adequate articulation, grammatically correct, and he conveyed information adequately. Comprehension, repetition and confrontational naming (Boston Naming Test¹⁰) were normal. Ability to abstract common properties of both verbal and visual stimuli was normal (Dementia Rating Scale¹¹). Mild to moderate impairments on motor sequencing and go/no-go tasks were evident, with oversimplification and loss of task set, suggestive of executive (frontal) dysfunction (Dementia Rating Scale¹¹ and Luria Complex Motor Tests¹²). Spatial perception and visual constructions were moderately to severely impaired (Hooper Visual Organization Test¹³ and Boston Parietal Lobe Battery¹⁴). Misplacements, rotations, and distortions were common, especially for the left aspect of each design. Moreover segmentation of the designs was notable, and the patient failed to demonstrate awareness of his distortions. Visual scanning and search of a complex picture was

limited to the right side, and the patient had to be prompted to view both the bottom and the left side of the scene.¹⁰ Immediate and delayed memory for verbal material was within broad normal limits; however, immediate and delayed memory for non-verbal information was mildly to moderately impaired (Wechsler Memory Scale–Revised¹⁵). These primarily right hemisphere and frontal deficits were consistent with the right hemisphere infarction on CT scan and the bifrontal abnormalities noted on EEG. He was able to discuss the belief in his wife's infidelity but denied any other unusual beliefs, hallucinations, or visual misperceptions.

Treatment and Course

During the course of the patient's 3-week psychiatric hospitalization, acebutolol hydrochloride and cimetidine medications were tapered to assess for their contribution to his depressed presentation and mental status changes. The patient evidenced improvement in his mood, and his affect brightened. However, despite increasing dosages of haloperidol, the patient's delusion remained fixed, although verbal and physical threats toward his wife diminished. He spoke of wanting to mend the relationship with his wife, and was looking forward to their annual vacation in Florida where "maybe my wife will be able to forget [the neighbor] and learn to love me again." The patient was discharged on phenytoin, 200 mg bid, and haloperidol, 1 mg qhs. Acebutolol hydrochloride and cimetidine were discontinued, and he was started on nifedipine for hypertension and allopurinol for gout. Recommendations were made to the patient and his wife to pursue sexual counseling regarding alternatives to coitus; however, they postponed a decision in this regard.

Follow-up neurologic and psychiatric evaluations 4 months after discharge from psychiatric hospitalization (and 17 months after the cerebrovascular accident) revealed continued delusional jealousy, with variability in the extent to which the patient responded aggressively to his erroneous beliefs. He reportedly began accusing his wife of having an affair with "men of different races" after he became suspicious of young Latino men during the couple's vacation in Florida. No changes in neurologic or medical status were otherwise observed. Blood levels of phenytoin were demonstrated to be within the therapeutic range (14.4 mg/L). The patient and his wife decided at the time of follow-up to comply with sexual counseling recommendations, and this therapy is currently ongoing.

Discussion

Misrepresentation or misinterpretation of events is common in brain disease, especially with diffuse or multifocal disorders such as toxic or metabolic encephalopathy, closed head trauma, or degenerative disease.⁵ Delusions associated with toxic/metabolic disturbances are usually simple in form (ie, persecutory or ideas of reference) and often resolve with treatment of the underlying disturbance, while those associated with degenerative dementia tend to remit as the disease progresses.

Recent attention has been focused on delusions that have a specific theme or are confined to one topic. Numerous cases of these monosymptomatic or content-specific delusions have been reported in association with identifiable insults⁸ or degenerative processes.¹⁶ Such delusions as reduplicative paramnesia (the belief that familiar surroundings have been duplicated), Capgras syndrome (the belief that one's family members have been replaced by imposters), and de Clérambault's syndrome (the belief that one is involved in an amorous relationship with a famous person) have been recognized with increasing frequency in association with insults to right hemisphere and bilateral frontal systems.^{8,17,18}

Traditionally, the Othello syndrome, and obsessive jealousy in general, has been treated purely as a symptom of a primary psychiatric disorder. In fact, delusional jealousy is not uncommonly found in association with chronic alcohol abuse, schizophrenia, primary delusional (paranoid) disorder, or as a secondary symptom in affective disorder.³ In this literature, psychodynamic interpretations are usually offered as the underlying causes of the development of pathologic jealousy. Certainly, in the present case one can argue that the patient's inability to "fertilize his lawn" was a metaphor for his sexual dysfunction, and the fact that the young, presumably virile neighbor could perform this task served to highlight the patient's inadequacies with regards to fulfilling his wife's "needs."

Psychodynamic or functional interpretations for the development of this patient's delusion are not incompatible with the presumed organic etiology of the delusion. It is our hypothesis that the cerebral damage sustained by this patient predisposed him to misinterpret and misperceive everyday occurrences. The content of the resulting delusion, we believe, was influenced by psychological factors, most notably the patient's impotence and his wife's resulting alarm at his constant and aggressive sexual advances. In the patient's attempts to understand his wife's rejections to his advances, he erroneously

concluded that she must be having an affair, and he looked for the most viable candidate.

Delusional jealousy is rarely reported as a mono-symptomatic phenomenon of underlying neurologic disease. This is the first reported case of the Othello syndrome that clearly developed in association with a structural lesion and in the absence of general paranoia. The present case illustrates the development of the delusion after ischemic injury to the brain in the absence of other psychotic features. The temporal association between the delusional disorder and the ischemic injury, the absence of personal or family history of psychosis or paranoid personality, and the fact that the patient did not use alcohol are unique features of this case and are indicative of the organic basis for the psychiatric presentation. Furthermore, although the patient did exhibit depressive symptomatology on admission, his delusion persisted despite adequate pharmacologic amelioration of his affective symptoms.

Neuroradiologic findings in the current case are consistent with those findings in patients with other content-specific delusions described by Levine and Grek.⁸ This elderly patient sustained massive damage to the right hemisphere, which appeared to be superimposed on mild cortical atrophy. As suggested by these researchers, the damage sustained by the right hemisphere may predispose the individual to misinterpret complex information and integrate irrelevant stimuli into false beliefs. The intact left hemisphere allows the individual to verbalize these false beliefs. Furthermore, Malloy et al¹⁸ have suggested that, in patients with delusions secondary to demonstrable neurodiagnostic findings, dysfunctional frontal systems preclude the individual from correcting his misbelief in the face of contradictory evidence. Clearly, this inability to alter false conclusions was apparent in our patient. Thus, a pattern of right hemisphere damage superimposed on dysfunctional frontal systems may be a necessary component to the development of fixed delusions, as suggested by studies on other content-specific delusions.¹⁷

The current case illustrates several aspects of the Othello syndrome that have been described in the psychiatric literature. It has been suggested that the Othello syndrome occurs more often in males than in females. This ratio, however, may be a reporting bias due to the increased likelihood of males to respond in an aggressive manner to the delusion.¹⁹ In fact, it was the assaultiveness of the patient presented here that finally brought him to the attention of the psychiatric community. Excessive sexual zeal

and increasing attempts at sexual activity with the partner have also been discussed as commonly accompanying the Othello delusion. This was a difficult problem for the patient presented here who, paradoxically with his sexual zeal, was impotent. These apparently paradoxical findings are actually consistent with the literature on sexual functioning after brain damage. Sexual dysfunction is a common sequela of both traumatic brain injury and of cerebrovascular infarction. Coslett and Heilman,²⁰ in fact, found that individuals with a right hemisphere infarction are more likely to experience impaired sexual function than those with a left hemisphere infarction. Perseverative maladaptive attempts to ameliorate the sexual dysfunction may occur, due to disinhibition secondary to frontal lobe injury.²¹ Finally, the literature has suggested that the prognosis is poor with individuals exhibiting delusional jealousy and other specific secondary delusions.¹⁸ Our patient has continued to evidence the persistence of the delusion, although his willingness to act on his belief has fluctuated.

One final point bears mention regarding sexual functioning of brain-injured individuals. There is a voluminous literature on sexuality after cerebrovascular infarctions^{22,23} suggesting not only that sexual dysfunction is common in this population, but that sexuality is often ignored by health care professionals. In cases as striking as the present one, for example, it is tempting to focus on the irrationality of the jealous behaviors and dismiss the psychological impact of the patient's impotence. However, one then misses the opportunity to address the central issues of sexual dysfunction and to explore adjunct, non-pharmacologic interventions to help such couples alleviate or diminish the jealousy.

References

1. Enoch MD, Trethowan WH: *Uncommon Psychiatric Syndromes*. Chicago, Year Book Medical, 1979, pp 36-49.
2. Shrestha K, Rees DW, Rix KJB, et al: Sexual jealousy in alcoholics. *Acta Psychiatr Scand* 1985;72:283-290.
3. Shepherd M: Morbid jealousy: Some clinical and social aspects of a psychiatric symptom. *J Ment Sci* 1961;107:687-753.
4. Crowe RR, Clarkson C, Tsai M, Wilson R: Delusional disorder: Jealous and nonjealous types. *Eur Arch Psychiatr Neurol Sci* 1988;237:179-183.
5. Cummings JL: Organic delusions: Phenomenology, anatomical correlations, and review. *Br J Psychiatry* 1985;146:184-197.
6. Kala AK, Kala R: Psychotic jealousy: A phenomenological study. *Indian J Psychiatry* 1981;23:237-241.
7. Cummings JL, Miller B, Hill MA, Neshkes R: Neuropsychiatric aspects of multi-infarct dementia and dementia of the Alzheimer's type. *Arch Neurol* 1987;44:389-393.

Othello Syndrome

8. Levine DN, Grek A: The anatomic basis of delusions after right cerebral infarction. *Neurology* 1984;34:577–582.
9. Folstein MF, Folstein SE, McHugh PR: "Mini-mental state": A practical method for grading the cognitive state of patients for the clinician. *J Psychiatry Res* 1975;12:189–198.
10. Goodglass H, Kaplan E: *Assessment of Aphasia and Related Disorders*. Philadelphia, Lea & Febiger, 1972.
11. Mattis S: *The Dementia Rating Scale*. Odessa, FL, Psychological Assessment Resources, 1988.
12. Malloy PF, Webster JS, Russell W: Tests of Luria's frontal lobe syndromes. *Int J Clin Neuropsychol* 1985;7:88–95.
13. Hooper HE: *The Hooper Visual Organization Test. Manual*. Los Angeles, Western Psychological Services, 1958.
14. Borod JC, Goodglass H, Kaplan E: Normative data on the Boston Diagnostic Aphasia Examination, Parietal Lobe Battery, and the Boston Naming Test. *J Clin Neuropsychol* 1980;2:209–216.
15. Wechsler D: *Wechsler Memory Scale-Revised. Manual*. New York, Psychological Corp, 1987.
16. Cummings JL, Victoroff JI: Noncognitive neuropsychiatric syndromes in Alzheimer's disease. *Neuropsychiatry Neuropsychol Behav Neurol* 1990;3:140–158.
17. Alexander M, Stuss DT, Benson DF: Capgras syndrome: A reduplicative phenomenon. *Neurology* 1979;29:334–339.
18. Malloy PF, Cimino C, Westlake R: Differential diagnosis of primary and secondary Capgras delusions. *Neuropsychiatry Neuropsychol Behav Neurol*, in press.
19. Munro A: Excellent response of pathologic jealousy to pimozide. *Can Med Assoc J* 1984;131:852–853.
20. Coslett HB, Heilman KM: Male sexual function: Impairment after right hemisphere stroke. *Arch Neurol* 1986;43:1036–1039.
21. Kreutzer JS, Zasler ND: Psychosexual consequences of traumatic brain injury: Methodology and preliminary findings. *Brain Injury* 1989;3:177–186.
22. Burgener S, Logan G: Sexuality concerns of the post-stroke patient. *Rehab Nursing* 1989;14:178–181, 195.
23. Sjogren K, Damber J, Liliequist B: Sexuality after stroke with hemiplegia. *Scand J Rehab Med* 1983;15:55–61.