

- In: Kertesz A, ed. *Localization in neuropsychology*. New York: Academic Press, 1983: 323-56.
- 4 Damasio AR, Damasio H. The anatomic basis of pure alexia. *Neurology* 1983;33:1573-83.
  - 5 Greenblatt SH. Subangular alexia without agraphia or hemianopia. *Brain Lang* 1976;3: 229-45.
  - 6 Assal G, Hadj-Djilani M. Une nouvelle observation d'alexie pure sans hémianopsie. *Cortex* 1976;12:169-84.
  - 7 Pirozzolo FJ, Kerr KL, Obrzut JE, et al. Neurolinguistic analysis of the language abilities of a patient with a "double disconnection syndrome": A case of subangular alexia in the presence of mixed transcortical aphasia. *J Neurol Neurosurg Psychiatry* 1981;44:152-5.
  - 8 Friedman RB, Albert ML. Alexia. In: Heilman KM, Valenstein E, eds. *Clinical neuropsychology*. New York: Oxford University Press, 1985:49-73.
  - 9 Kinkel PR, Kinkel WR, Jacobs L. Nuclear magnetic resonance imaging in patients with stroke. *Semin Neurol* 1986;6:43-52.

### Minor hemisphere syndrome following left hemispheric lesion in a right handed patient

Some degree of unawareness of hemiplegia occurs in about one third of cases of right hemisphere patients with left hemiplegia.<sup>1-4</sup> Anosognosia for hemiplegia may be associated with left hemiasomatognosia. Such patients behave as if the left half of their body was no longer part of themselves.<sup>3</sup> In contrast to the relative frequency of such phenomena following damage to the right hemisphere, anosognosia and hemiasomatognosia have rarely been reported following left hemisphere lesions. None of the reported cases has concerned authentic right-handed patients and the degree of language impairment has often been unknown.

We describe a case of a strongly right handed patient with asomatognosia and anosognosia for right hemiplegia. She exhibited other deficits relating to the so-called minor hemisphere syndrome, and had no language disorders.

On the thirteenth day after aortic valve replacement for aortic regurgitation, the patient, a 68 year old right handed woman, developed an acute hemiplegia. On the fourth day following onset, neurological examination showed massive right motor deficit affecting the face, the arm and the leg. Right plantar reflex was extensor, there was severe hypesthesia and tactile extinction on the right side of the body, and right homonymous hemianopia on confrontation. Language and praxis were normal on bedside evaluation. The patient had motor impersistence and strongly tended to keep her head and eyes turned to the left, even on verbal stimulation from the right. CT scan at 10 days post onset revealed a left hemispheric infarct involving the territory of the middle cerebral artery, both deep and superficial, and the territory of the anterior choroidal artery.

The following observations were gathered during the first three weeks following the stroke, during which period the neurological condition of the patient remained essentially unchanged. Right sided visual neglect was seen on the dot cancellation test: she failed to cancel 7/9 dots in the right half of the test sheet, although she did not miss any of the eight dots in the left half. The patient was

presented with a list of 40 pairs of items (10 pairs of digit names, 20 pairs of object names, 10 pairs of sentence fragments). She showed clearcut right auditory neglect: she correctly reported all of the 40 items presented to her left ear, but none of those presented to her right ear.

She was largely unaware of her hemiplegia. When asked if she could move her right hand, sew, or knit, she answered that she could. When asked if she could move her right leg, she answered positively and moved her left leg as a proof. Sometimes, the patient admitted that she needed some help with walking or running. Once, when asked if she could cut her meat and eat all by herself, she affirmed that she could, if only helped to sit in her bed. She occasionally showed some abstract knowledge of her deficit. She said that doctors had told her she had hemiplegia, but that she did not believe it, since she was not paralysed and could walk.

The patient also showed a variable degree of right asomatognosia. In several instances, when shown her right hand, she would answer that it was the hand of a corpse that had been introduced into her bed. However, she sometimes correctly identified the hand as her own. Touching it with her left hand apparently facilitated the identification. When asked to designate her right hand she was initially unable to find it in the bed. Twelve days after onset, she could correctly designate her right arm, leg, eye and cheek.

Her spontaneous speech was considerably aprosodic and she was initially unable to sing at all, although she previously used to participate in an amateur choir. Two weeks after the stroke, her few attempts at singing were very much out of tune. Moreover, her perception of melodies was also impaired. Five days post-onset, she could not identify common tunes that were hummed to her, but recognised them readily as soon as the lyrics were added. Three weeks later, she could identify five out of 10 popular tunes whose melodies were sung to her.

The patient described herself as completely right handed, and denied having been forced to use her right hand as a child. There was no record of any significant cerebral trauma in birth or early childhood. She was submitted to a 24 item questionnaire about her preferred hand or foot in various everyday-life activities. She always unambiguously chose the right side. Her parents, grand-parents, and two children were all reported to be right handed.

Language evaluation was normal in all respects. Spontaneous speech, repetition, object and picture naming, designation, fluency in controlled association, comprehension, and reading were flawless. She was too awkward with her left hand to allow evaluation of writing. There was no left hand apraxia. Visual identification of objects, colours and faces was normal.

The patient was a right handed woman, with no family history of left handedness. After a left parieto-temporal infarction, she showed several symptoms that usually follow right hemispheric lesions, that is, symptoms encompassed in the so-called minor hemisphere syndrome. She had right hemispatial neglect,<sup>5</sup> right hemiasomatognosia, anosognosia for right hemiplegia, motor aprosodia<sup>6</sup> and a severe impairment in identifying and producing musical tunes<sup>7</sup> but no aphasia.

Two main conclusions can be drawn concerning the patient's pattern of cerebral dominance. First, her right hemisphere was

certainly dominant for language. If the left hemisphere was dominant for language, or if language was bilaterally represented, the extensive left hemispheric softening would have caused aphasic symptoms, which was not the case. Second, her left hemisphere was strongly dominant for manuality, spatial attention, and body schema.

Few cases of right asomatognosia or anosognosia for right hemiplegia have been reported. Dronkers and Knight<sup>8</sup> have described a left handed patient with clear-cut anosognosia for right hemiplegia, right spatial neglect and aprosodia, following left hemispheric infarct. Cambier *et al*<sup>9</sup> have reported a similar case, but their patient seems to be ambidextrous. Such is also the case of the patient reported by Hermann and Pözl.<sup>10</sup> Among their patients with left-hemispheric lesions, Hécaen and Sauguet<sup>11</sup> mention right hemiasomatognosia in two out of 47 left-handed patients, but in none of 293 that were right-handed. Gross and Kaltenbäck<sup>1</sup> have described two patients with such a denial of right hemiplegia, including one case with hemiasomatognosia. These patients were both aphasic, but there is no mention of their manual dominance. Cutting<sup>2</sup> has reported three instances of denial of hemiplegia out of 22 testable right hemiplegic patients. Their manual dominance and degree of language impairment, however, are not reported.

The dominant hemisphere for body schema is usually the right hemisphere. However, as we have just seen, considerable evidence exists of reversed dominance, as revealed by right asomatognosia and anosognosia for right hemiplegia. The left hemisphere is usually dominant for manuality and language, although reversed dominance in this domain is also well known. But are all the different patterns of co-dominance concerning language, manuality and body-schema biologically possible? Or are some of these functions necessarily supported by the same hemisphere (or by opposite hemispheres)? We shall consider each pair of functions in turn. First, the left hemisphere is usually dominant for both language and manuality. Our patient falls into the 4% of those that are right handed with right hemispheric dominance for language, according to Rasmussen and Milner's figures<sup>12</sup> (for discussion, see Geschwind and Galaburda<sup>13</sup>). Second, manuality and body schema are usually dissociated since in most right handed subjects, the right hemisphere is dominant for body schema. The patient reported by Dronkers and Knight<sup>8</sup> shows exactly the opposite pattern of dominance. However, Hécaen and Sauguet<sup>11</sup> mention several left handed patients with left asomatognosia, suggesting that the right hemisphere can occasionally support both functions. The pattern of impairment in our patient demonstrates that that can also occur for the left hemisphere. Third, language and body-schema are usually dissociated, but one hemisphere can occasionally be dominant for both functions, as illustrated by the patients of Gross and Kaltenbäck,<sup>1</sup> who have at the same time aphasia and anosognosia for hemiplegia following left hemispheric lesion. Our patient's dominance pattern is the exact opposite of the pattern which prevails in most of those that are right handed, since her left hemisphere is dominant for body schema, and her right hemisphere for language.

The case favours the idea that there is no obligatory link between any two of the three cerebral functions we have considered, and

that each can be supported by one hemisphere or the other.

LAURENT COHEN  
PHILIPPE RÉMY  
ANNE LEROY  
CHRISTIAN GÉNY  
JEAN-DENIS DEGOS

*Clinique des Maladies du Système Nerveux,  
\*Hôpital de la Salpêtrière,*

*Paris,  
Service de Neurologie, Hôpital Henri Mondor,  
Créteil,  
France*

Correspondence to: L. Cohen, Clinique des Maladies du Système Nerveux, Hôpital de la Salpêtrière, 47 Bd de l'Hôpital, 75651 Paris Cedex 13, France.

1 Gross H, Kaltenböck E. Die Anosognosie. *Wiener Zeitschrift für Nervenheilkunde*

- 1955;11:374-418.  
2 Cutting J. Study of anosognosia. *J Neurol, Neurosurg Psychiatry* 1978;41:548-55.  
3 Bisiach E, Vallar G, Perani D, Papagno C, Berti A. Unawareness of disease following lesions of the right hemisphere: anosognosia for hemiplegia and anosognosia for hemianopia. *Neuropsychologia* 1986;24:471-82.  
4 Hécaen H. *Introduction à la neuropsychologie*. Larousse: Paris, 1972.  
5 Heilman KM, Watson RT, Valenstein E. Neglect and related disorders. In: Heilman KM, Valenstein E, eds. *Clinical neuropsychology*. New York: Oxford University Press, 1985.  
6 Ross ED. The aprosodias: Functional-anatomic organisation of the affective components of language in the right hemisphere. *Arch Neurol* 1951;38:561-9.  
7 Zatorre RJ. Musical perception and cerebral function: a critical review. *Music Perception* 1984;2:196-221.

- 8 Dronkers NF, Knight RT. Right-sided neglect in a left-hander: Evidence for reversed hemispheric specialisation of attention capacity. *Neuropsychologia* 1988;27:729-35.  
9 Cambier J, Masson M, Guillot M, Robine B. Négligence droite avec hémiasomatognosie, confusion mentale, apraxie et agrophie sans aphasie. *Revue Neurologique* 1985;141:802-6.  
10 Hermann G, Pözl O. *Über Agraphie und ihre lokal-diagnostischen Beziehungen*. S Karger: Berlin, 1926.  
11 Hécaen H, Sauguet J. Cerebral dominance in left-handed subjects. *Cortex* 1971;7:19-48.  
12 Rasmussen T, Milner B. Clinical and surgical studies of the cerebral speech areas in man. In: Zulch KJ, Creutzfeldt O, Galbraith GC, eds. *Otfried Foerster symposium on cerebral lateralisation*. Heidelberg: Springer, 1975.  
13 Geschwind N, Galaburda AM. Cerebral lateralisation. Biological mechanisms, associations, and pathology: 1. A hypothesis and a program for research. *Arch Neurol* 1985;42:428-59.

### Pure sensory stroke due to midbrain haemorrhage

After reading the interesting case reported by Azouvi *et al.*,<sup>1</sup> we would like to report a similar case, but in our patient the underlying disease was a cavernous angioma.

A 42 year old woman was admitted to our hospital because of a mild occipital pain, and dysaesthesia in the left part of her body. Neurological examination showed a fully oriented patient, loss of touch and pain sensations then involved the entire left side of her body, including the face. Vibration and position sensations were normal as were motor and cerebellar functions. Tendon jerks were symmetrical and plantar responses were flexor. Laboratory examinations, ECG and chest radiographs were normal. A CT showed a haematoma in the right dorsal and lateral aspect of the pons. An arteriographic study of both vertebral arteries showed no abnormalities. The neurological disorder resolved within three months. An MRI performed three months later revealed a hypodensity, of 0.8 × 1.8 cm diameter, in the right dorsal and lateral aspect of the pons, suggesting a cavernous angioma (fig).

Since the first description in 1977,<sup>2</sup> only eight cases of haemorrhagic pure sensory stroke (PSS) have been described. All of them were secondary to small haematomas in the

thalamus, internal capsule or pons.<sup>1</sup> As far as we know, this is the first case of haemorrhagic PSS secondary to cavernous angioma located in the pons. In our patient, as in the one reported by Azouvi *et al.*,<sup>1</sup> the damage was restricted to the right dorsal spinothalamic tract without involving the medial lemniscus. We agree with the authors that small haematomas located on the sensory pathways, before they reach the thalamus, can produce partial PSS. MRI is useful in detecting vascular malformations, even when, as in our case, angiographic studies are normal.

J ALVAREZ-SABIN  
J MONTALBÁN  
M TINTORÉ  
A CODINA  
*Department of Neurology,  
Hospital General Vall d'Hebron,  
Barcelona, Spain*

Correspondence to: Dr Alvarez-Sabin, Rda San Antonio, 5 Ppal, 08011 Barcelona, Spain.

- 1 Azouvi Ph, Tougeron A, Hussonois C, Schouman-Claeys E, Bussel B, Helkd JP. Pure sensory stroke due to midbrain haemorrhage limited to the spinothalamic pathway. *J Neurol Neurosurg Psychiatry* 1989;52:1427-8.  
2 Groothuis DR, Duncan GW, Fisher CM. The human thalamocortical sensory path in the internal capsule: evidence from a small capsular haemorrhage causing a pure sensory stroke. *Ann Neurol* 1977;2:328-31.

### Parkinsonism and defects of praxis following methanol poisoning

The neurological sequelae of methanol intoxication shows marked individual variation, but Parkinsonism, optic atrophy and focal cranial nerve deficits have been described.<sup>1-3</sup> We report a patient who presented with Parkinsonism and dyspraxia and who recovered from acute severe methanol poisoning. The MRI scan showed damage of the deep grey nuclei.

A 28 year old woman with a history of depression and recurrent alcohol abuse experienced nausea, vomiting, ataxia and blurred vision for 24 hours before she was admitted stuporose, with dilated pupils that did not react to light. The optic fundi were normal, and there were no localising neurological signs. The liver was enlarged. She had a leucocytosis of 12900/mm<sup>3</sup> and a severe metabolic acidosis (pH 7.15; bicarbonate 2.8 mEq/l; pO<sub>2</sub> 129 mm Hg; pCO<sub>2</sub> 8 mm Hg).

With the possibility of methanol poisoning in mind, she was given intravenous infusions of sodium bicarbonate and ethanol, and haemodialysis. The level of methanol in the blood was 2.85 g/l. After three hours, the acidosis was controlled. When the patient's level of consciousness improved, she admitted drinking some 200 ml of methanol in the past 48 hours. She left the hospital after four days without apparent neurological or ocular abnormalities.

She was examined two years later, complaining of motor slowness and loss of memory. She had been working at the same factory at which she was employed before taking the methanol. The work required sequential and repetitive movements of both hands and feet. The employers stated that her productivity was reduced by 50%.

Neurological examination showed a mild dysarthria, a Parkinsonian-like syndrome, with an expressionless face, limb bradykinesia, and abnormal postural reflexes. Rapid alternating finger movements were poorly performed. The glabella tap sign was positive and palmar-mental and peri-oral reflexes were present; her gait was characterised by poverty of associated movements, with reduced arm-swinging and body turning. The optic fundi displayed bitemporal pallor. Visual acuity was normal. Chest radiographs, ECG and EEG were normal. An unenhanced CT scan showed bilateral areas of decreased density, especially in the putamen. An MRI scan (fig) showed bilateral lesions involving the claus-

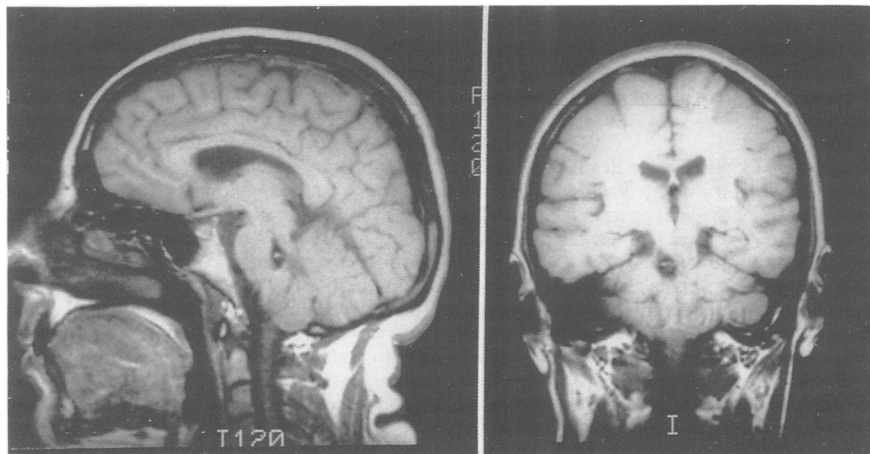


Figure Axial and sagittal T<sub>1</sub> MRI showing a cavernous angioma in the right dorsal part of the pons.