



## SHORT COMMUNICATION

# Unilateral thalamic lesions and generalized or lateralized spike wave discharges

F. Irsel Tezer<sup>a,\*</sup>, Serap Saygi<sup>b</sup>

<sup>a</sup> *Institute of Neurological Sciences and Psychiatry, Hacettepe University, School of Medicine, Ankara, Turkey*

<sup>b</sup> *Department of Neurology, Hacettepe University, School of Medicine, Ankara, Turkey*

Received 24 January 2009; received in revised form 27 May 2009; accepted 31 May 2009

Available online 3 July 2009

## KEYWORDS

Spike wave discharges;  
Thalamic lesion;  
Thalamus;  
Cortex;  
Idiopathic generalized epilepsy

**Summary** We report four adult patients who had thalamic lesions and lateralized or generalized spike wave discharges (SWDs). The first two patients also had cortical lesions. The role of the cortex and thalamus in the generation of SWDs is discussed. The third patient had a history of idiopathic generalized epilepsy (IGE) with intractable seizures. The last patient had partial seizures and absences. The coexistence of IGE with refractory focal epilepsy and the relation with thalamic lesions are discussed.

© 2009 Elsevier B.V. All rights reserved.

## 1. Introduction

Spike wave discharges (SWDs), which are characteristic EEG findings in idiopathic generalized epilepsy (IGE), are generated through corticothalamic and thalamocortical connections (Steriade, 2005). Maintaining these discharges requires the integrity of both the cortex and the thalamus (Avoli and Gloor, 1982). Thalamic lesions associated with epileptic seizures like focal or multifocal motor seizures (Adams et al., 1988), gyratory seizures (Leiguarda et al., 1992), infantile spasms (Incorpora et al., 1999), or epilepsy with continuous SWDs during sleep (Incorpora et al., 1999, Kelemen et al., 2006) have been previously reported. Recently only four adult patients with clinical histories

compatible with IGE (Inghilleri et al., 2002; Kelemen et al., 2006; Nguyen et al., 2006) who had unilateral thalamic lesions and generalized SWDs on electroencephalogram (EEG), have been reported. Three of them had intractable seizures (Kelemen et al., 2006; Nguyen et al., 2006) and one patient had absence status (Inghilleri et al., 2002). In this paper we present four adult patients with lateralized or generalized SWDs possibly related to unilateral thalamic lesions. Due to the lateralization of the discharges, their clinical presentations may be important for understanding the relation between thalamic lesions and occurrence of SWDs.

## 2. Patients

### 2.1. Patient 1

A 23-year-old female was admitted to our clinic after she had her first generalized tonic clonic seizure (GTCS) in the first week of the postpartum period. She also had dysphasia and right-sided hemiparesis. She had no history of epilepsy

\* Corresponding author at: Hacettepe University, School of Medicine, Department of Neurology, O6100, Sıhhiye, Ankara, Turkey. Tel.: +90 312 305 11 82; fax: +90 312 309 34 51.

E-mail address: [irseltezer@yahoo.com.tr](mailto:irseltezer@yahoo.com.tr) (F.I. Tezer).

or risk factor, but eclampsia had been diagnosed at the seventh month, leading to cesarean section. A venous infarction in the left temporoparietal area and thrombosis in transverse and sigmoid sinus were seen on her cranial magnetic resonance imaging (MRI). Her EEG revealed slow waves on the left side. She was anticoagulated because of the high level of factor VIII and levetiracetam was given for seizure control. Three weeks after discharge, she was admitted due to recurrent GTCS and difficulty in speech. Her MRI showed a new ischemic lesion in the left pulvinar region of the thalamus (Fig. 1A) and her INR was 1.2. Her EEG showed slow background on the left side and brief generalized spike and multiple spikes and waves. She also had isolated spikes or sharp waves on the left side (Fig. 1B). These lateralized EEG findings were persistent in six EEG recordings during the 2 years of follow up. She had a few mild seizures during follow up and was given anticoagulation and antiepileptic treatment.

## 2.2. Patient 2

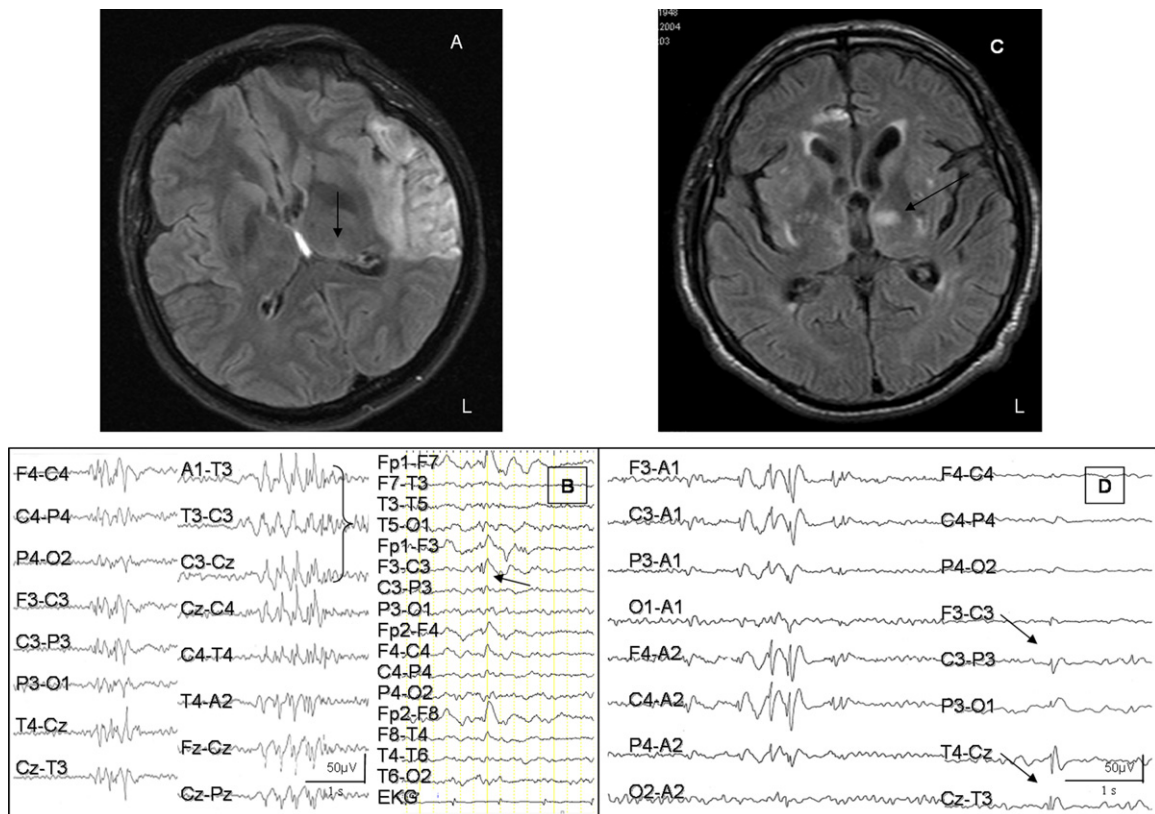
A 56-year-old hypertensive, diabetic man was admitted to hospital due to a diabetic ulcer on his left foot. During treatment of that complaint in the internal ward, 2 mg daily risperidone was started because of his behavioral disturbances. On the fifth day, he had his first GTCS. He had no obvious seizure risk factor. His blood biochemistry was nor-

mal. His EEG showed generalized SWDs for 1–2 s with frontal dominance mostly on the right side. An acute ischemic lesion was reported on the right cingulate gyrus on diffusion MRI. His transthoracic echocardiography and cranial MR angiography were normal. He was treated with subcutaneous heparin and acetyl salicylic acid; valproic acid was given for seizures.

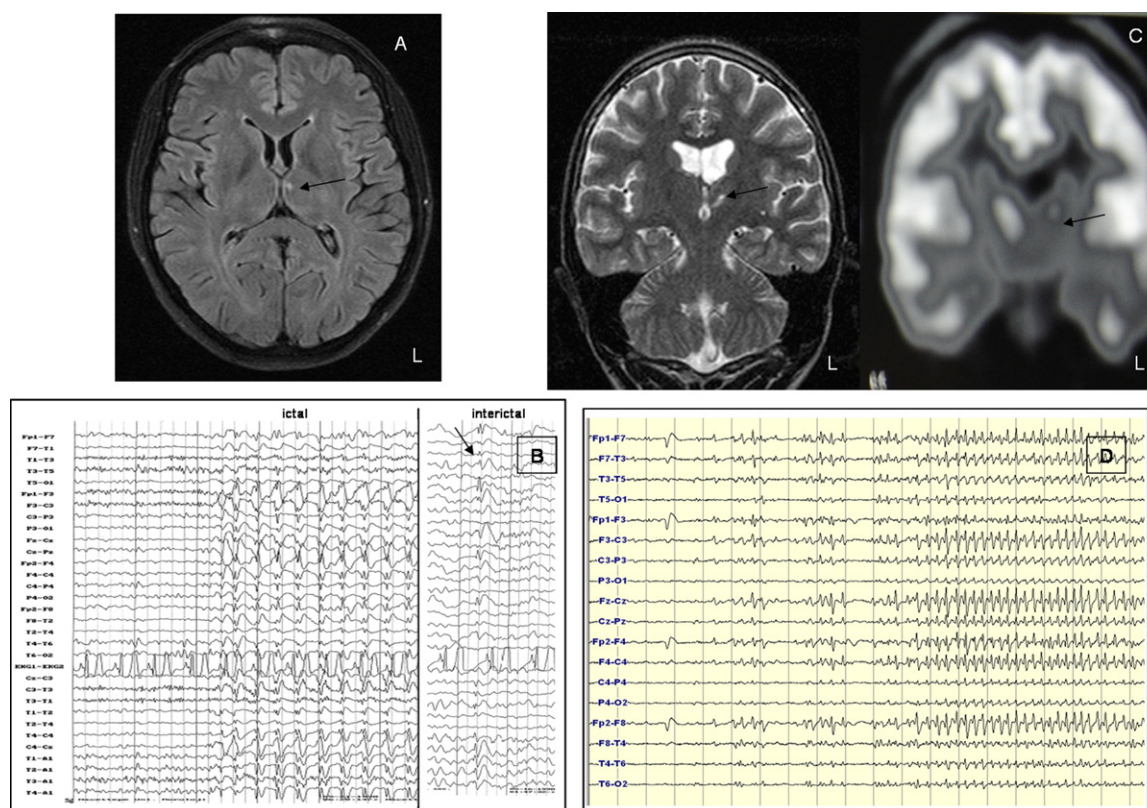
On day 32 after admission, his left leg, with the intractable diabetic foot ulcer, was amputated. Cranial MRI and EEG were performed after this operation because of lethargy. His MRI showed a new acute ischemic lesion in the left thalamomesencephalic region (Fig. 1C) and his EEG revealed mild slow background activity with generalized SWDs and isolated spikes in the left centroparietal region (Fig. 1D). Additionally pneumonia was diagnosed, antibiotic therapy was expanded but the antiepileptic treatment was not changed. There was no recurrence of seizures but left-sided epileptiform discharges were present in his one follow-up EEG recording. Unfortunately we were unable to follow him up or contact him by telephone after discharge.

## 2.3. Patient 3

A 27-year-old female was admitted because of generalized convulsions that had started at the age of 14. She also had daily attacks with loss of contact or jerks of her arms. Her family history was unremarkable but she had a febrile convulsion at the age of 2. She had taken phenytoin, car-



**Figure 1** (A) MRI of patient 1 with a new ischemic lesion in the left pulvinar region of thalamus. (B) EEG of patient 1 with brief generalized spike and multiple spikes and waves predominantly on the left side. She also had isolated spikes or sharp waves on the left side. (C) MRI of patient 2 with a new acute ischemic lesion on left thalamomesencephalic region in addition to an old ischemic lesion on the right cingulate gyrus. (D) EEG of patient 2 with generalized SWD and isolated spikes in the left centroparietal region.



**Figure 2** (A) MRI of patient 3 with a lacunar lesion on the left medial thalamus. (B) EEG of patient 3 with generalized SWDs (ictal) and isolated spike discharges on left side (interictal). (C) MRI of patient 4 with a sequela left thalamic lesion and thalamic atrophy (left side) and PET with hypoperfusion on the anteromedial part of the left thalamus. (D) EEG of patient 4 with generalized 3.5–4 Hz SWDs.

bamazepine, and phenobarbital in different combinations for 13 years. Due to the intractability of her seizures she was monitored in the video-EEG monitoring unit. Absence seizures with mild hand automatisms associated with generalized SWDs and one absence-clonic-tonic-clonic seizure were recorded. Isolated spike discharges on the left side were seen in her interictal EEG recordings during five days of monitoring (Fig. 2B). Her MRI showed a lacunar lesion on the left medial thalamus (Fig. 2A). She had no risk factor for ischemia in her history and laboratory examinations including echocardiography. Her antiepileptic therapy was changed to monotherapy with valproic acid. She had no further generalized convulsive seizures with valproic acid, but absences and mild jerks persisted. Lamotrigine was added and she became seizure free, and follow-up EEGs were either normal or showed rare left-sided spikes.

#### 2.4. Patient 4

A 16-year-old boy had his first GTCS at 9 years old. He had recurrent seizures with bilateral hand and oral automatisms. His daily attacks with loss of contact were witnessed by his family. His mother's and father's cousins had a history of epilepsy with GTCS, but there was no consanguinity between his parents. Due to the lack of seizure control with the combination of clonazepam, valproic acid, lamotrigine, and carbamazepine, he was monitored for six days in the video-EEG monitoring unit. He had frequent generalized 3.5–4 Hz

SWDs for 10–30 s (Fig. 2D). In a few of these short time periods with SWDs nurses checked whether he was conscious. Mostly he remained conscious and he was able to answer questions or remember the given code after the end of the paroxysm. He also had seizures with staring and automatisms. Ictal EEGs showed bilateral frontotemporal onset with rhythmic activity prominently on the left side.

His cranial MRI showed a sequela left thalamic lesion with thalamic atrophy (Fig. 2C, left side) and positron emission tomography (PET) showed hypoperfusion on the anteromedial part of the left thalamus (Fig. 2C, right side). Ethosuximide was added to his therapy but his seizures persisted.

### 3. Discussion

We report new four adult patients with unilateral thalamic lesions that altered the integrity of the thalamocorticothalamic circuits. The difference between our cases and those reported previously (Inghilleri et al., 2002; Kelemen et al., 2006; Nguyen et al., 2006) was the presence of persistent and frequent lateralizing findings on EEG. That may be related to the preceding cortical lesions leading to a hyperexcitable cortex (Meeren et al., 2002), like in our first two patients. However, there was a strong temporal relation with thalamic lesion and occurrence of SWDs, especially in patient 1. SWDs were seen after the occurrence of an



acute thalamic pulvinar lesion and lateralized to that lesion. Involvement of the posterior–inferior part of the thalamus, instead of the medial–anterior region, including thalamocortical cells and surrounding reticular nucleus, which are responsible for the generation of SWDs (Steriade, 2005) might be unexpected for the occurrence of SWDs. However, the cytotoxic edema near the pulvinar region may affect these structures. Furthermore, neuroimaging evidence of pulvinar involvement in patients with temporal lobe epilepsies (Guye et al., 2006) has been reported. The pulvinar area might be activated by the hyperexcitable temporal cortex. Additionally, the possibility of a genetic background for IGE in such a young patient must be considered, although she had no history of absences or myoclonia and no family history.

Patient 2 had an acute right frontal ischemic lesion initially and SWDs lateralizing to the right. In the second EEG with left lateralizing findings and SWDs, he had a new ischemic lesion in the left thalamomesencephalic region. Frontal lesions causing SWDs or secondary bilateral synchrony have been reported (Pavone and Niedermeyer, 2000). Therefore, his first attack might have been related to the lesion of the right cingulate gyrus. In the second EEG the generalized SWD and localized epileptogenic activity in the left centroparietal region showed a temporal relation with a new left thalamic lesion. We hypothesize that the large left thalamic lesion could easily have affected the SWD generating structures and might have been an additional factor. The lateralizing finding in the second EEG was concordant with the side of the recent thalamic lesion. The thalamus and cortex, especially the perioral region of the frontal cortex, actively participate in the generation of SWDs (Meeren et al., 2002; Steriade, 2005). Focal cortical or thalamic lesions in this thalamocortical circuit may cause SWDs with lateralized findings on EEG. Additionally risperidone could facilitate the cortical and/or thalamic excitation.

The presence of absences in patient 3 and 4 was similar to previously reported cases of intractable IGE and unilateral thalamic lesions (Nguyen et al., 2006). Importantly our patients had SWDs with lateralizing findings compatible with the thalamic lesions. It is difficult to explain why these destructive subcortical–thalamic lesions cause unilateral cortical discharges, but they might have activated a superimposed hyperexcitable cortex.

In patient 4 the coexistence of IGE with refractory focal epilepsy and/or secondary bilateral synchrony could have been due to the presence of multiple seizure types and EEG findings. In animal studies administration of proconvulsive agents to caudal or rostral parts of the reticular nucleus of the thalamus produced different semiology related to the presence of different connections to the limbic motor area or sensory area (Aker et al., 2006). Left thalamic atrophy

and hypometabolism in patient 4 may be related to partial seizure facilitation or propagation via corticothalamic pathways (Guye et al., 2006). The presence of thalamic atrophy or asymmetries of thalamic metabolism has been associated with poorer outcome (Newberg et al., 2000).

In conclusion, in our patients the cause of the generalized and/or lateralized SWD may be the presence of a hyperexcitable cortex or an irritative thalamic lesion. To identify these mechanisms experimental animal studies may be helpful in future.

## References

- Adams, C., Hochhauser, L., Logan, W.J., 1988. Primary thalamic and caudate hemorrhage in term neonates presenting with seizures. *Pediatr. Neurol.* 4, 175–177.
- Aker, R.G., Ozyurt, H.B., Yananli, H.R., Cakmak, Y.O., Ozkaynakçi, A.E., Sehirli, U., Saka, E., Cavdar, S., Onat, F.Y., 2006. GABA(A) receptor mediated transmission in the thalamic reticular nucleus of rats with genetic absence epilepsy shows regional differences: functional implications. *Brain Res.* 1111, 213–221.
- Avoli, M., Gloor, P., 1982. Interaction of cortex and thalamus in spike and wave discharges of feline generalized penicillin epilepsy. *Exp. Neurol.* 76, 196–217.
- Guye, M., Regis, J., Tamura, M., Wendling, F., McGonigal, A., Chauvel, P., Bartolomei, F., 2006. The role of corticothalamic coupling in human temporal lobe epilepsy. *Brain* 129, 1917–1928.
- Incorpora, G., Pavone, P., Smilari, P.G., Trifiletti, R., Parano, E., 1999. Late primary unilateral thalamic hemorrhage in infancy: report of two cases. *Neuropediatrics* 30, 264–267.
- Inghilleri, M., Clemenzi, A., Conte, A., Frasca, V., Manfredi, M., 2002. Bilateral spike-and-wave discharges in a hemideafferented cortex. *Clin. Neurophysiol.* 113, 1970–1972.
- Kelemen, A., Barsi, P., Gyorsok, Z., Sarac, J., Szucs, A., Halasz, P., 2006. Thalamic lesion and epilepsy with generalized seizures ESES and spike-wave paroxysms—report of three cases. *Seizure* 15, 454–458.
- Leiguarda, R., Nogues, M., Berthier, M., 1992. Gyrate epilepsy in a patient with a thalamic neoplasm. *Epilepsia* 33, 826–828.
- Meeren, H.K., Pijn, J.P., Van Luijtelaar, E.L., Coenen, A.M., Lopes da Silva, F.H., 2002. Cortical focus drives widespread corticothalamic networks during spontaneous absence seizures in rats. *J. Neurosci.* 22, 1480–1495.
- Newberg, A.B., Alavi, A., Berlin, J., Mozley, P.D., O'Connor, M., Sperling, M., 2000. Ipsilateral and contralateral thalamic hypometabolism as a predictor of outcome after temporal lobectomy for seizures. *J. Nucl. Med.* 41, 1964–1968.
- Nguyen, D.K., Podubnaia, A.B., Carmant, L., Guilbert, F., Cossette, P., 2006. Generalized epilepsy and classic spike-wave discharges with unilateral thalamic lesions. *Arch. Neurol.* 63, 1321–1323.
- Pavone, A., Niedermeyer, E., 2000. Absence seizures and the frontal lobe. *Clin. Electroencephalogr.* 31, 153–156.
- Steriade, M., 2005. Sleep, epilepsy and thalamic reticular inhibitory neurons. *Trends Neurosci.* 28, 317–324.