

Short communication

Superior divisional vestibular paresis in anterior inferior cerebellar artery infarction

Hyung Lee^a, Hyo-Jung Kim^b, Ja-Won Koo^c, Ji Soo Kim^{b,*}^a Department of Neurology, Keimyung University School of Medicine, Daegu, Republic of Korea^b Department of Neurology, Seoul National University College of Medicine, Seoul National University Bundang Hospital, Seoul, Republic of Korea^c Department of Otolaryngology, Head and Neck Surgery, Seoul National University College of Medicine, Seoul National University Bundang Hospital, Seoul, Republic of Korea

ARTICLE INFO

Article history:

Received 24 March 2009

Accepted 11 June 2009

Available online 4 July 2009

Keywords:

Anterior inferior cerebellar artery

Vertigo

Stroke

Evoked potential

ABSTRACT

A 74-year-old woman with sudden vertigo and dysarthria showed spontaneous nystagmus beating rightward, upward and clockwise. She also exhibited dysfunction of the left utricle and superior and horizontal canals, which was documented by head impulse and heave tests, measurements of ocular torsion and subjective visual vertical tilt, bithermal caloric tests, and rotation axis analysis of the spontaneous nystagmus. In contrast, functions of the left posterior canal, saccule, and cochlea were remained intact, as evidenced by normal head impulse test, audiometry and vestibular evoked myogenic potential. MRI revealed an acute infarction in the left lateral pons of anterior inferior cerebellar artery (AICA) territory. Our patient with AICA infarction showed isolated damage to the superior vestibular labyrinth or its afferents with preservation of the inferior vestibular labyrinth and auditory function. Our patient provides further evidence that isolated damage to the superior vestibular labyrinth or its afferents may be a mechanism of isolated vascular vertigo.

© 2009 Elsevier B.V. All rights reserved.

1. Introduction

The mechanisms of isolated vertigo remain to be elucidated in ischemia of the vertebrobasilar artery territory. Since the inner ear is supplied by the internal auditory artery (IAA) which is usually a branch of the anterior inferior cerebellar artery (AICA), vertigo is a common symptom of AICA infarction [1]. However, AICA infarction mostly manifests with vertigo and hearing loss in addition to other brainstem or cerebellar signs [2].

The vestibular labyrinth may be divided into two compartments, the superior and inferior, according to innervation and vascular supply [1]. The superior vestibular labyrinth, including the anterior (ASC) and horizontal (HSC) semicircular canals and the utricle, is supplied by the anterior vestibular artery (AVA) [1]. In contrast, the posterior vestibular artery (PVA), which is a branch of the vestibulocochlear artery, usually irrigates the saccule and the posterior semicircular canal (PSC) [1]. Since PVA has a close relationship with the cochlear supply and has more abundant intraosseous collaterals than AVA [1], isolated AVA infarction has been postulated as a mechanism of isolated vascular vertigo [3]. We report a patient with AICA infarction who suffered from damage to the superior vestibular labyrinth or its afferents with preservation of the inferior vestibular labyrinth and auditory function.

2. Materials and methods

2.1. Case report

A 74-year-old woman with hypertension and hypercholesterolemia for 15 years developed sudden vertigo and vomiting on awakening. She also noticed mild dysarthria, but denied associated tinnitus or hearing loss. Six days after symptom onset, examination showed mixed horizontal–vertical–torsional nystagmus beating rightward, upward and clockwise (from the patient's perspective), which increased on rightward gaze and decreased on leftward gaze. Horizontal head shaking and vibratory stimuli on either mastoid augmented the spontaneous nystagmus. Head impulse test revealed corrective catch-up saccades during stimulation of the left HSC and ASC [4]. Head heave was also positive leftward [5]. Horizontal and vertical saccades were normal. Rightward smooth pursuit was interrupted by the nystagmus. She showed mild dysarthria and ataxia of the lower extremities. She fell to the left on attempted standing. Other findings of neurological and neurotological examinations were normal.

2.2. Oculography

Three dimensional recording of the spontaneous nystagmus was performed using video-oculography (SMI, Teltow, Germany), and the eye positions were computed in head-fixed coordinates (X, Y, Z) [6]. Leftward, downward, and clockwise directions from the patient's view were positive for horizontal (Z), vertical (Y), and torsional (X) eye rotations.

* Corresponding author. Department of Neurology, Seoul National University Bundang Hospital, Seoul National University College of Medicine, 300 Gumi-dong, Bundang-gu, Seongnam-si, Gyeonggi-do, 463-707, Republic of Korea. Tel.: +82 31 787 7463; fax: +82 31 719 6828.

E-mail address: jisookim@snu.ac.kr (J.S. Kim).

To determine rotation axis of the spontaneous nystagmus, the slow-phase eye velocity of the nystagmus was calculated from three-dimensional analysis of eye positions [7]. Then, the rotation axis of each nystagmus was analyzed off-line and plotted in three dimension using MATLAB software. The axes orthogonal to the average human semicircular canal planes were defined as the semicircular canal axes [8]. Since the nystagmus was from the inhibition of the semicircular canals, the rotation axis of the nystagmus was inverted.

2.3. Vestibular-evoked myogenic potential (VEMP)

To record VEMP, the SCM muscle was activated by actively turning the head contralaterally in the supine position [9]. The patient had to hold this position precisely to achieve a constant tonic activation of the SCM during the whole recording period. Electromyographic activities of the SCM were recorded using surface electrodes from the upper half of the SCM muscle with a ground electrode on the forehead and a reference electrode over the upper sternum. The resulting impedance of the recording electrodes was maintained below 3 k Ω by cleaning the skin with a peeling gel. VEMP was detected using a Nicolet VikingSelect unit (Nicolet Biomedical, WI, USA). A short alternating tone burst (95 dB nHL, 108 dB SPL; 500 Hz; ramp = 2 ms; plateau = 3 ms) was given at 2.1 Hz monaurally. The analysis time for each stimulus was 50 ms and responses for up to 200 stimuli were averaged for each test. The signal was filtered at a bandpass of 30–1500 Hz, and the mean values of at least two trials were obtained from each ear for all participants.

The absolute VEMP amplitude was then normalized against mean tonic activation of SCM during the recording. The electromyographic activities of SCM were also recorded using another surface electrode with a lowpass filter at 50 Hz and were digitized at 1 KHz using an AD converter (National Instruments Corp, Austin, TX, USA). The peak to peak amplitudes (mV) were analyzed using Labview program (National Instruments Corp, Austin, TX, USA) and mean tonic activation during the recording was calculated.

To compare the normalized p13–n23 amplitude of VEMP responses on the affected side with that on the intact side, the interaural difference ratio of the normalized amplitude (IAD_{amp} , %) was calculated using $[(Au - Aa) / (Aa + Au) 100]$, where Au is the normalized p13–n23 amplitude on the unaffected side and Aa is the amplitude on the affected side.

Normative data were obtained from 52 healthy volunteers (23 women) with ages ranging from 22 to 76 years (mean \pm SD = 36.7 \pm 12.4, median = 32). In healthy volunteers, the difference in the normalized amplitudes between the ears was divided by the sum of the amplitudes from both ears and this was then multiplied by 100 to obtain IAD_{amp} (%). Regarding p13 and n23 latencies, absolute values and interaural differences were obtained to determine delayed responses.

2.4. Other neurotological tests

Detailed methods of measuring ocular torsion and rotation of the subjective visual vertical have been described previously [10]. The patient also underwent standardized audiometry, brainstem auditory evoked potentials (BAEP), bithermal caloric tests and brain MRI [10,11].

3. Results

Recording of the spontaneous nystagmus six days after the symptom onset documented nystagmus beating rightward, upward and clockwise (from the patient's perspective, Fig. 1A). The rotation axes of the spontaneous nystagmus clustered between the rotation axes of the left horizontal and anterior semicircular canals, which indicate dysfunction of those canals (Fig. 1B).

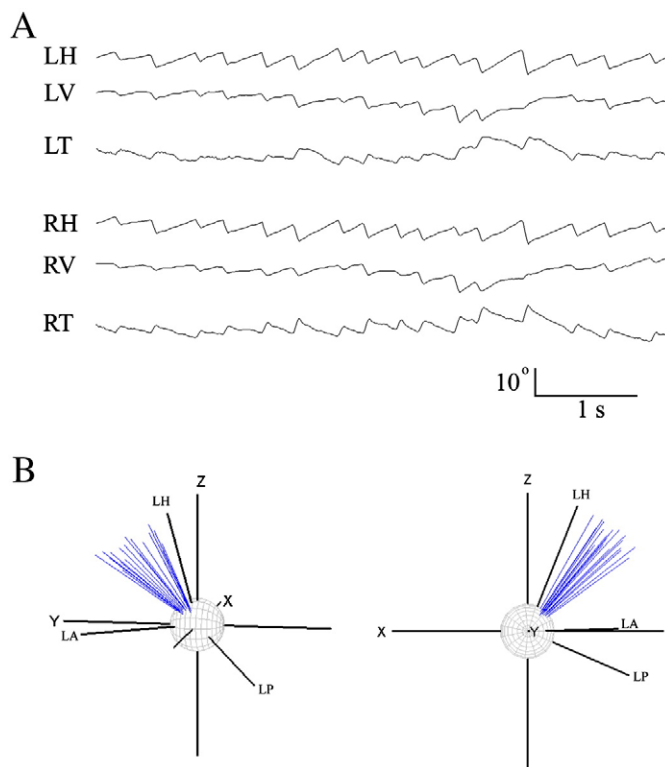


Fig. 1. A. Recording of the spontaneous nystagmus six days after the symptom onset shows nystagmus beating rightward, upward and clockwise (from the patient's perspective). B. Rotation axes of the spontaneous nystagmus cluster between the rotation axes of the left horizontal and anterior semicircular canals, which indicates dysfunction of those canals. The rotation axis of the nystagmus is inverted since the nystagmus was from the inhibition of the semicircular canals.

She also showed counterclockwise ocular torsion (Fig. 2A) and rotation of the subjective visual vertical (SVV, -7.5° with both eyes). Pure tone audiometry showed symmetric high-tone sloping, consistent with presbycusis, with normal speech discrimination (Fig. 2B). Bithermal caloric tests documented 60% left caloric paresis (Fig. 2C). VEMP and brainstem auditory evoked potentials were normal (Fig. 2D).

MRI revealed an acute infarction in the left lateral pons of AICA territory (Fig. 3A) and MR angiography disclosed a stenosis in the vertebrobasilar junction and atherosclerotic changes in the basilar artery. Another stenosis was noted in the proximal portion of the left middle cerebral artery (Fig. 3B).

4. Discussion

Our patient with AICA infarction showed impaired function of the superior vestibular labyrinth or its afferents without damages to the inferior vestibular labyrinth or auditory system. Involvement of the superior vestibular labyrinth is evidenced by abnormal head impulse tests during stimulation of ASC and HSC, caloric paresis (HSC), abnormal head heave test (utricle), and ipsiversive ocular torsion and SVV tilt (utricle). In contrast, sparing of the inferior vestibular labyrinth is inferred from the normal VEMP (saccul) and normal head impulse test during stimulation of PSC [4,9]. Furthermore, results of 3-dimensional recording and vector analysis of the spontaneous nystagmus were consistent with dysfunction of left ASC and HSC.

AICA infarction may result in either peripheral or central vestibular damage [2]. The intrapontine vestibular nerve may have been damaged by the lesion in our patient. Previous primate studies also showed the greatest degree of canal paresis in lesions involving the vestibular nerve up to the level of the root entry zone [12]. However,

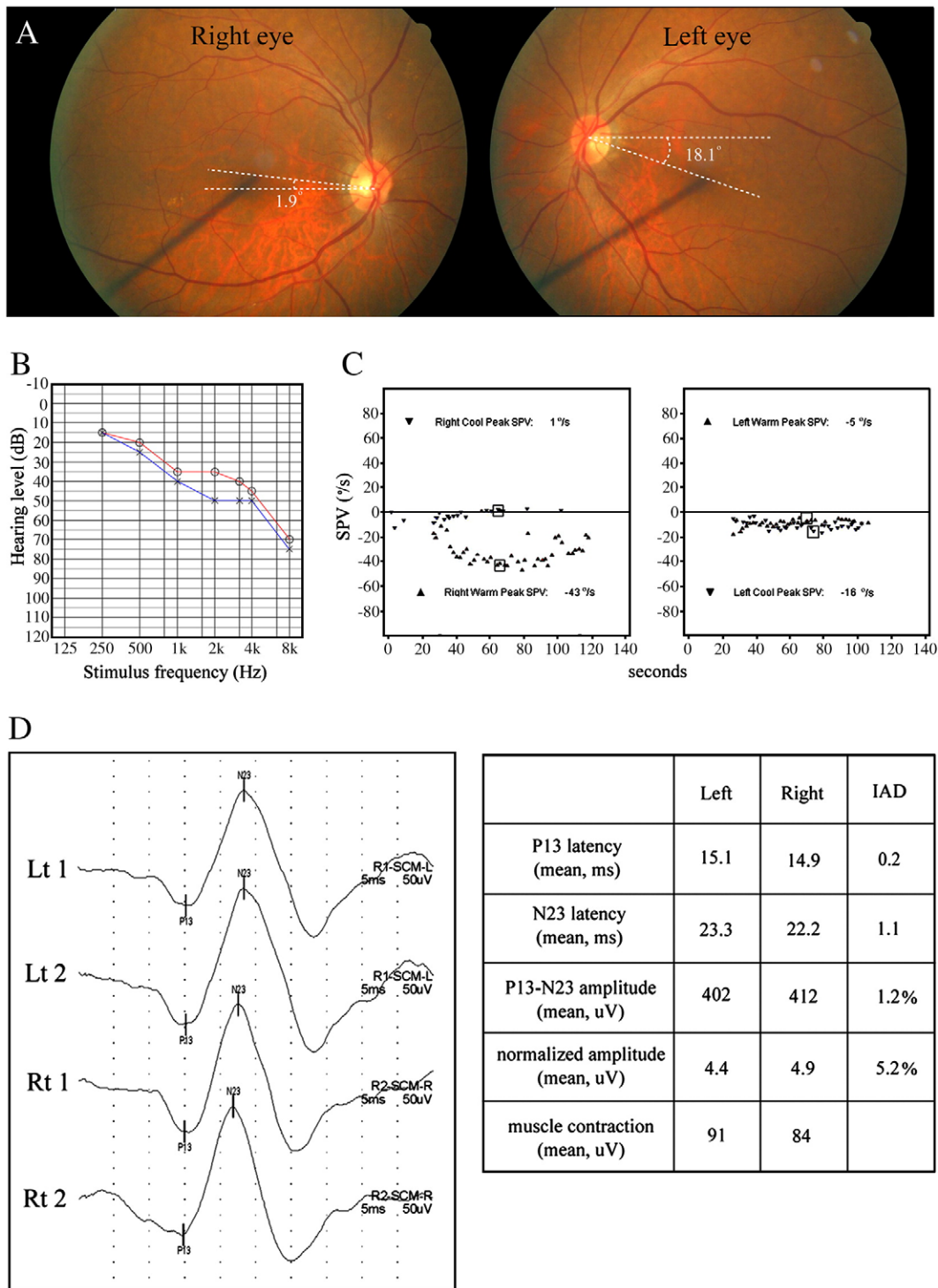


Fig. 2. A. Fundus photos show an abnormal intorsion of the right eye (-1.9° , normal range $=0^\circ$ to 12.6° , the negative value indicates intorsion of the eye) and increased extorsion of the left eye (18.1°). B. Pure tone audiometry demonstrates symmetric sensorineural hearing loss with high-tone sloping, which is consistent with presbycusis. The patient's hearing levels are plotted against stimulus frequency on a logarithmic scale. Measurements were made according to the American National Standards Institute, 1989. Circle, air conduction on the right side; cross, air conduction on the left side. C. Video-oculographic recordings (ICS medical, IL, USA) of bithermal caloric tests show left canal paresis (60%) with normal fixation suppression. SPV, slow-phase velocity. D. Vestibular-evoked myogenic potential recorded on the contracting ipsilateral sternocleidomastoid muscle shows symmetric responses. Lt, left; Rt, right.

central canal paresis mostly occurs in the medial and lateral vestibular nuclei and proximal portion of the vestibular fascicle [13], distinct from the lesion found in our patient. Furthermore, selective involvement of the afferents from the superior vestibular labyrinth should be rare in lesions involving the root entry zone where the nerve fibers from the labyrinth have a compact organization. Instead, isolated AVA

infarction may be a possibility. Since AVA is an end artery with less intraosseous collaterals than PVA, the superior vestibular labyrinth may be more vulnerable to ischemia [1]. Indeed, a previous pathologic study of IAA infarction also documented relative sparing of the inferior vestibular labyrinth. Furthermore, sensorineural hearing loss in AICA infarction is mostly of cochlear origin [2].

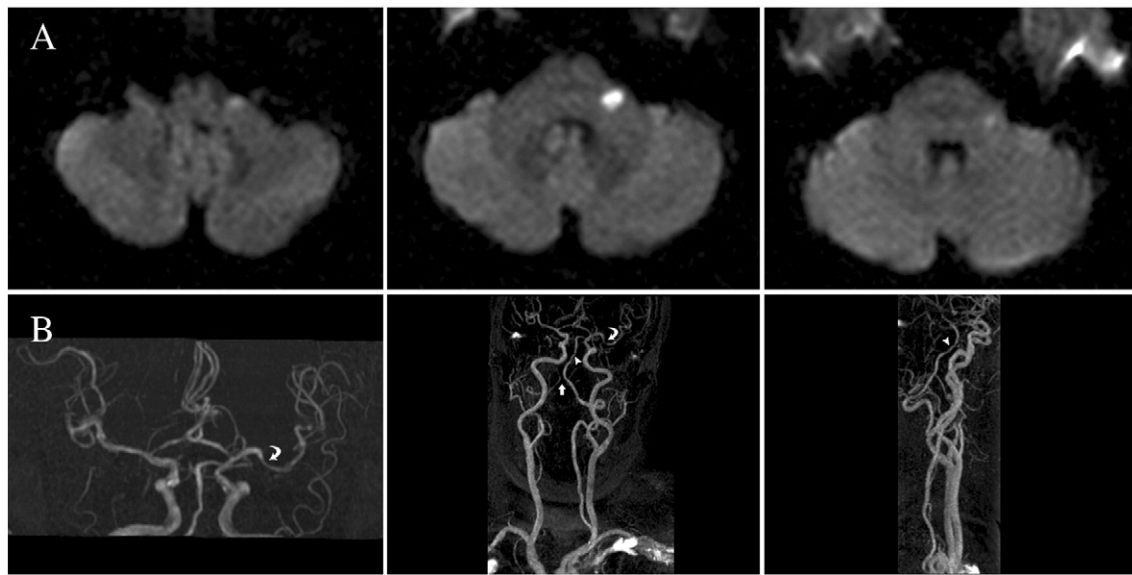


Fig. 3. A. Diffusion-weighted MRIs exhibit an acute infarction in the left lateral pons of the anterior inferior cerebellar artery (AICA) territory. B. MR angiography discloses a stenosis in the vertebrobasilar junction (arrow) and atherosclerotic changes in the basilar artery (arrow head). Another stenosis was also noted in the proximal portion of the left middle cerebral artery (curved arrow).

Our patient provides further evidence that selective damage to the superior vestibular labyrinth or its afferents may be a mechanism of isolated vascular vertigo.

References

- [1] Mazzoni A. The vascular anatomy of the vestibular labyrinth in man. *Acta Otolaryngol* 1990;472(suppl):1–83.
- [2] Lee H, Sohn SI, Jung DK, et al. Sudden deafness and anterior inferior cerebellar artery infarction. *Stroke* 2002;33:2807–12.
- [3] Kim JS, Lopez I, DiPatre PL, Liu F, Ishiyama A, Baloh RW. Internal auditory artery infarction: clinical–pathologic correlation. *Neurology* 1999;52:40–4.
- [4] Halmagyi GM, Curthoys IS. A clinical sign of canal paresis. *Arch Neurol* 1988;45:737–9.
- [5] Ramat S, Zee DS, Minor LB. Translational vestibulo–ocular reflex evoked by a “head heave” stimulus. *Ann N Y Acad Sci* 2001;942:95–113.
- [6] Choi KD, Oh SY, Park SH, Kim JH, Koo JW, Kim JS. Head-shaking nystagmus in lateral medullary infarction: patterns and possible mechanisms. *Neurology* 2007;68:1337–44.
- [7] Aw ST, Todd MJ, Aw GE, McGarvie LA, Halmagyi GM. Benign positional nystagmus. A study of its three-dimensional spatio-temporal characteristics. *Neurology* 2005;64:1897–905.
- [8] Blanks RH, Curthoys IS, Markham CH. Planar relationships of the semicircular canals in man. *Acta Otolaryngol* 1975;80:185–96.
- [9] Colebatch JG, Halmagyi GM. Vestibular evoked potentials in human neck muscles before and after unilateral vestibular deafferentation. *Neurology* 1992;42:1635–6.
- [10] Choi KD, Oh SY, Kim HJ, Park SH, Koo JW, Kim JS. Recovery of vestibular imbalances after vestibular neuritis: one-year follow-up. *Laryngoscope* 2007;117:1307–12.
- [11] Oh YM, Oh DH, Jeong SH, Koo JW, Kim JS. Sequential bilateral hearing loss in multiple sclerosis. *Ann Otol Rhinol Laryngol* 2007;117:186–91.
- [12] Uemura T, Cohen B. Effects of vestibular nuclear lesions on vestibulo-ocular reflexes and posture in monkeys. *Acta Otolaryngol* 1973(Suppl 315):1–71.
- [13] Francis DA, Bronstein AM, Rudge P, du Boulay EPGH. The site of brainstem lesions causing semicircular canal paresis: an MRI study. *J Neurol Neurosurg Psychiatry* 1992;55:446–9.