

encephalitis, tumors and Todd's paralysis following seizures.¹⁶ For this reason research into the use of imaging to target acute thrombolytic therapy at the retrievable penumbra may be required in line with recent multicentre adult studies.¹⁷

Geographically located stroke units within tertiary paediatric centres are not feasible given the small numbers of patients presenting at any one time with stroke. However, the principles of adult stroke units can still be applied to the paediatric population by identifying health professionals with an interest and expertise in various aspects of diagnosis and management. Involvement of neurologists, haematologists, radiologists, emergency physicians, paediatricians, neonatologists, paediatric intensivists, cardiologists, neurosurgeons and the extended allied health team are essential to the coordinated care of children with stroke. There are now consensus-based guidelines with recommendations for standardised diagnostic and treatment protocols.^{10–12}

4. Conclusions

With increased awareness of the importance of early presentation to hospital with stroke symptoms from advertising campaigns (e.g. the Australian National Stroke Foundation's campaign "FAST = face, arm, speech, time") and health professional education, the rates of teenagers and young adults presenting acutely to large stroke centres is likely to increase. In the patient described, the young girl was referred directly to the stroke unit by her family GP, familiar with the acute stroke service in his metropolitan area. We should therefore be focusing research attention on the lack of evidence of acute thrombolytic intervention in children and teenagers. Development of paediatric stroke programs and multicentre international collaborations are required to achieve these goals. A consortium of paediatric neurologists and haematologists has been enrolling patients in the International Paediatric Stroke Study (<https://app3.ccb.sickkids.ca/cstrokestudy/>). This registry aims to increase knowledge about risk factors and mechanisms of stroke and to establish accurate recurrence risks. A multicentre study to

establish safe and appropriate tPA dosing in the paediatric population is planned for the near future.¹⁴

References

1. Saver JL, Yafeh B. Confirmation of tPA treatment effect by baseline severity-adjusted end point reanalysis of the NINDS-tPA stroke trials. *Stroke* 2007;**38**:414–6.
2. deVeber GGroup. TCISS. Canadian Pediatric Ischaemic Stroke Study Registry: analysis of children with arterial ischaemic stroke. *Ann Neurol* 2000;**48**:514.
3. Murphy SL. Deaths: final data for 1998. *Natl Vital Stat Rep* 2000;**48**:1–105.
4. Ganesan V, Hogan A, Shack M, et al. Outcome after ischaemic stroke in childhood. *Develop Med Child Neurol* 2000;**42**:455–61.
5. Chabrier S, Husson B, Lasjaunias P, et al. Stroke in childhood: outcome and recurrence risk by mechanism in 59 patients. *J Child Neurol* 2000 May;**15**:290–4.
6. Ganesan V, Prengler M, McShane MA, et al. Investigation of risk factors in children with arterial ischemic stroke. *Ann Neurol* 2003 Feb;**53**:167–73.
7. Gruber A, Nasel C, Lang W, et al. Intra-arterial thrombolysis for the treatment of perioperative childhood cardioembolic stroke. *Neurology* 2000;**54**:1684–6.
8. Janjua N, Nasar A, Lynch JK, et al. Thrombolysis for ischemic stroke in children: data from the nationwide inpatient sample. *Stroke* 2007 Jun;**38**:1850–4.
9. Amlie-Lefond C. Thrombolysis in children with arterial ischemic stroke: initial results from the International Pediatric Stroke Study (Abstract). *Proceedings of the 32nd International Stroke Conference* 2007;**38**:485.
10. Paediatric Stroke Working Group. *Stroke in Childhood: Clinical Guidelines for Diagnosis, Management and Rehabilitation*. Suffolk, UK: Royal College of Physicians; Lavenham Press; 2004.
11. Monagle P, Chalmers E, Chan A, et al. Antithrombotic Therapy in Neonates and Children: American College of Chest Physicians Evidence-Based Clinical Practice Guidelines (8th ed.). *Chest* 2008;**133**(Suppl. 6):887S–968S.
12. Roach ES, Golomb MR, Adams R, et al. Management of stroke in infants and children: a scientific statement from a Special Writing Group of the American Heart Association Stroke Council and the Council on Cardiovascular Disease in the Young. *Stroke* 2008;**39**:2644–91.
13. Andrew M, Vegh P, Johnston M, et al. Maturation of the hemostatic system during childhood. *Blood* 1992 Oct 15;**80**:1998–2005.
14. Whelan HT, Cook JD, Amlie-Lefond CM, et al. Practical model-based dose finding in early-phase clinical trials: optimizing tissue plasminogen activator dose for treatment of ischemic stroke in children. *Stroke* 2008 Sep;**39**:2627–36.
15. Gabis LV, Yangala R, Lenn NJ. Time lag to diagnosis of stroke in children. *Pediatrics* 2002;**110**:924–8.
16. Braun K, Kappelle L, Kirkham F, et al. Diagnostic pitfalls in paediatric ischaemic stroke. *Dev Med Child Neurol* 2006;**48**:985–90.
17. Butcher KS, Parsons M, MacGregor L, et al. Refining the perfusion–diffusion mismatch hypothesis. *Stroke* 2005;**36**:1153–9.

doi:10.1016/j.jocn.2009.01.014

Transcortical sensory aphasia following a left frontal lobe infarction probably due to anomalously represented language areas

E.J. Kim^a, M.K. Suh^b, B.H. Lee^b, K.C. Park^c, B.D. Ku^d, C.S. Chung^b, D.L. Na^{b,*}

^a Department of Neurology, Pusan National University School of Medicine and Medical Research Institute, Busan, Korea

^b Department of Neurology, Samsung Medical Center, Sungkyunkwan University School of Medicine, 50 Ilwon-dong, Kangnam-gu, Seoul 135-710, Korea

^c Department of Neurology, Kyunghee University College of Medicine, Seoul, Korea

^d Department of Neurology, Kwandong University College of Medicine, Myongji Hospital, Gyeonggi, Korea

ARTICLE INFO

Article history:

Received 4 April 2008

Accepted 18 January 2009

Keywords:

Anomalous language representation

Left frontal lobe

Transcortical sensory aphasia

ABSTRACT

A 57-year-old right-handed man presented with speech disturbance 1 day prior to his admission. The standardized aphasia test batteries showed transcortical sensory aphasia. MRI revealed a left frontal and insular infarct. Positron emission tomography scans also revealed a glucose hypometabolism in the same region as the infarcted area on MRI. Repeated aphasia testing showed that his aphasia only partially improved.

© 2009 Elsevier Ltd. All rights reserved.

* Corresponding author. Tel.: +82 2 3410 3591; fax: +82 2 3410 0052.
E-mail address: dukna@skku.edu (D.L. Na).

1. Introduction

Transcortical sensory aphasia (TSA) is a fluent aphasia syndrome characterized by impaired auditory comprehension with

preserved repetition that is mainly associated with left temporo-occipital or parieto-occipital lesions.¹ We report a patient with TSA, whose lesion was mainly localized to the left frontal lobe, and discuss possible mechanisms.

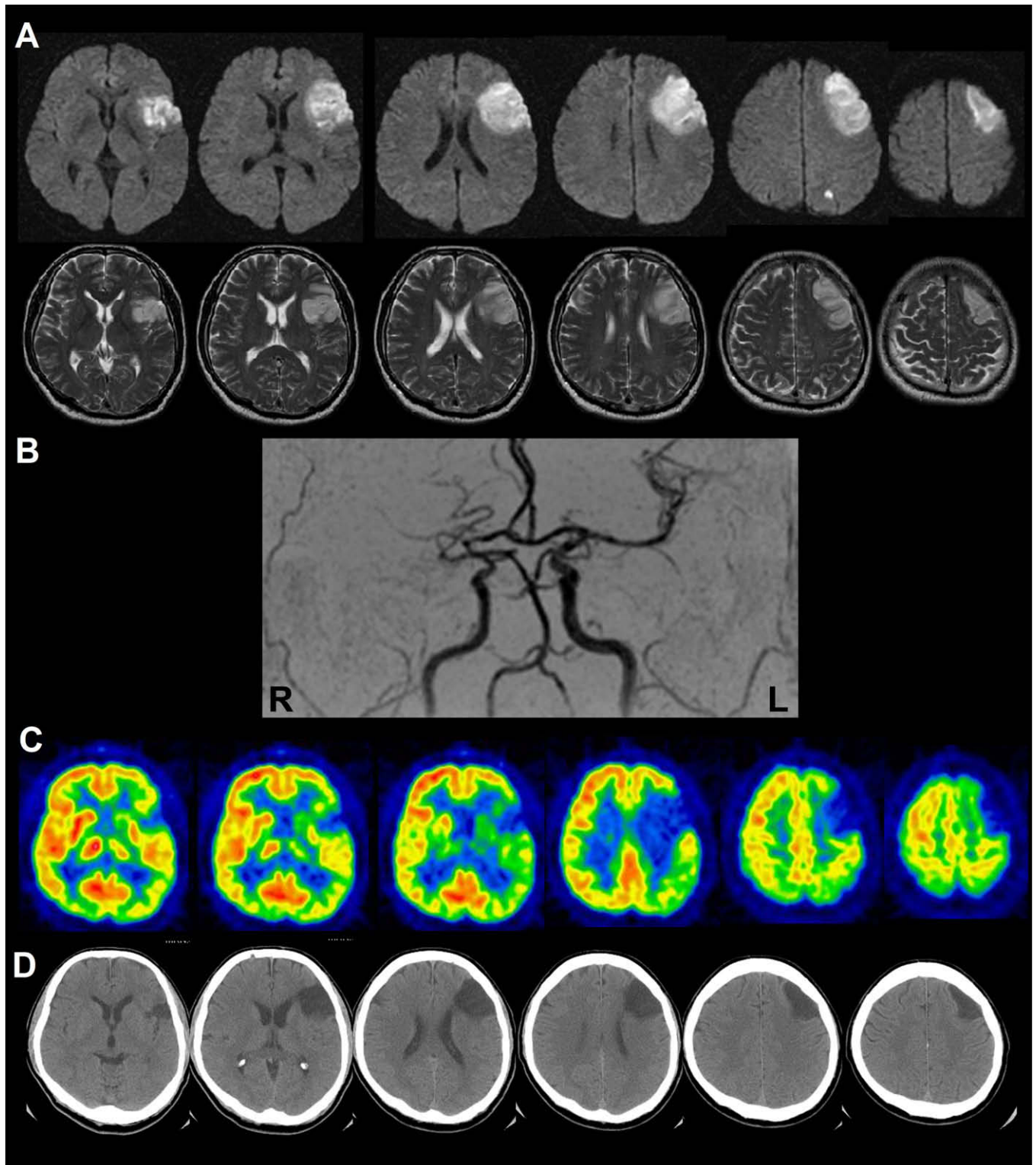


Fig. 1. (A) Diffusion-weighted (upper row) and T2-weighted (lower row) axial MRIs performed on the first day of onset showing high signal intensity in the left middle frontal gyrus, the lower part of the left precentral gyrus, the left inferior frontal gyrus, left insula and a small lacune in the left superior parietal lobule. (B) Magnetic resonance angiography revealed occlusion of the right proximal middle cerebral artery (MCA) and the distal branch of the left MCA. (C) [18F]-Fluorodeoxyglucose positron emission tomography axial images taken 1 month after onset showing large metabolic defects in the left frontal area with mild hypometabolism in the left parietotemporal area. (D) Axial CT scans taken 4 months post-stroke showed chronic infarction in the left frontal area. L = left, R = right.

2. Case report

A 57-year-old right-handed man presented with sudden onset language disturbance 1 day prior to his admission. The Korean version of the Western Aphasia Battery (K-WAB)² administered 1 day post-stroke showed global aphasia with severe impairment in both spontaneous speech and auditory comprehension (Table 1). MRI performed on the same day revealed an acute infarction in the left superior middle cerebral artery (MCA), involving the middle frontal gyrus, posterior parts of the inferior frontal gyrus, inferior parts of the precentral gyrus, and the dorsal anterior insula. A small acute infarction was also detected in the left superior parietal lobule (Fig. 1A). Magnetic resonance angiography showed total occlusion of the right proximal MCA and partial occlusion of the distal branches of the left MCA (Fig. 1B).

Three days after symptom onset, his spontaneous speech markedly improved. Seven days after the stroke, he could speak in sentences, with a mean length of approximately 3 phrases, and had normal articulation and prosody. On repetition tests, he was able to repeat up to 5-word sentences. In contrast, his auditory comprehension was severely impaired, as was confrontation and generative naming. His difficulty in auditory comprehension was not limited to sentences with complicated grammar. That is, it occurred not only at the sentence level (yes/no questions: 15/60) but also at word level (auditory word comprehension: 10/60). His reading and writing abilities were also severely impaired. Therefore, at that time, his language abnormality clearly met the definition of TSA (Table 1). Repeated K-WAB testing 1 month post-stroke showed improvements in auditory comprehension, but the scores still fell within the range of TSA.² Fluorodeoxyglucose positron emission tomography (FDG-PET) scans performed 34 days post-stroke revealed a large metabolic defect in the same region as the infarction. Mild glucose hypometabolism was also noted in the left parietotemporal area (Fig. 1C). A fourth administration of K-WAB 100 days post-stroke revealed improvement in his overall language skills, but his TSA persisted. A follow-up CT scan performed 4 months post-stroke confirmed the lesion to be restricted to the left frontal area (Fig. 1D).

3. Discussion

Mechanisms underlying the occasional association of TSA with dominant frontal lesions remain unclear, but there are a few possibilities. First, regarding the relationship between frontal damage and fluent aphasia, Maeshima et al. asserted that preserved perfusion in the precentral gyrus could allow for a fluent aphasia in the left frontal region of damage.³ As our patient's lesion involved the lower part of the precentral gyrus, this hypothesis cannot be applicable. Second, comprehension deficits seen with frontal damage may reflect impaired syntactic comprehension, such as grammatical deficits.⁴ However, comprehension deficits in this patient were severe even at the single word level, arguing against the syntactic comprehension deficit hypothesis.

Finally, Sethi et al. hypothesized that hypoperfusion injury to posterior language areas may cause the comprehension deficits seen in TSA patients with left frontal injuries.⁵ Indeed, on FDG-PET performed 1 month post-stroke, our patient showed mild hypometabolism in the posterior temporo-parietal cortex. However, the posterior hypometabolism may reflect an intrahemispheric diaschisis, such that damage to the frontal operculum, which has bidirectional connections with the superior temporal gyrus and inferior parietal lobule,⁶ might have caused mild temporo-parietal metabolic deficits. Alternatively, the parietotemporal hypometabolism could have been associated with the small focal infarction of the superior parietal lobule demonstrated on initial MRI. Whatever the causes, left posterior hypometabolism is less likely to account for the comprehension deficits of our patient.

Comprehension deficits caused by such a mild structural–metabolic lesion should have been mild and improved rapidly, especially since the patient's acute motor speech and fluency deficits resolved in days despite a dense infarct in the operculum. Furthermore, global aphasia due to lesions located in the superior division of the MCA typically evolve into Broca's or transcortical motor aphasia,⁷ which was not the case in our patient.

Our findings, based on serial language tests and neuroimaging findings, suggest that TSA associated with left frontal lobe lesions may reflect anomalous intrahemispheric transposition of the language centers such that Broca's area is located posteriorly, while Wernicke's area is located in anterior parts of the brain. There

Table 1
Results of language testing using the Korean version of the Western Aphasia Battery

K-WAB	Day 1*	Day 7	Day 30	Day 100
Spontaneous speech	0/20	15/20	18/20	18.5/20
Information content	0/10	7/10	9/10	9/10
Fluency, grammatical competence and paraphasias	0/10	8/10	9/10	9.5/10
Auditory comprehension	0.2/10	1.6/10	6.1/10	6.85/10
Yes/no questions	0/60	15/60	45/60	48/60
Auditory word recognition	2/60	10/60	40/60	54/60
Sequential commands	2/80	10/80	37/80	35/80
Repetition	0.4/10	7.8/10	9.2/10	9.2/10
Naming	0/10	1.5/10	2.5/10	6.0/10
Object naming	0/60	8/60	17/60	41/60
Word fluency	0/20	1/20	4/20	7/20
Sentence completion	0/10	4/10	0/10	2/10
Responsive speech	0/10	2/10	4/10	10/10
Reading comprehension	0.1/10	1.6/10	6.5/10	8.2/10
Writing	0/10	3.7/10	7.15/10	9.3/10
AQ (normal criteria, 97.11 ± 2.43)	1.2	51.8	71.6	81.1
LQ (normal criteria, 95.51 ± 3.93)	1.0	38.4	52.2	82.4
Type of aphasia	GA	TSA	TSA	TSA

AQ = aphasia quotient, GA = global aphasia, K-WAB = the Korean version of the Western Aphasia Battery, LQ = language quotient, TSA = transcortical sensory aphasia.

* The number of days post-stroke.

are also other possibilities such as bi-frontal language representation (expressive area in the right and receptive area in the left frontal lobe) or extensive damage to frontal white matter that connects Broca's area with Wernicke's area within the left hemisphere. However, all possibilities should be confirmed by relevant investigations, such as functional MRI studies.

Acknowledgment

The authors thank William W. Seeley for his critical feedback on the paper. This study was supported by a grant of the Korea Health 21 R&D Project, Ministry of Health and Welfare, Republic of Korea (A050079).

doi:10.1016/j.jocn.2009.01.013

References

1. Kertesz A, Sheppard A, MacKenzie R. Localization in transcortical sensory aphasia. *Arch Neurol* 1982;**39**:475–8.
2. Kim H, Na DL. Normative data on the Korean version of the Western Aphasia Battery. *J Clin Exp Neuropsychol* 2004;**26**:1011–20.
3. Maeshima S, Kuwata T, Masuo O, et al. Transcortical sensory aphasia due to a left frontal subcortical haemorrhage. *Brain Inj* 1999;**13**:927–33.
4. von Stockert TR, Bader L. Some relations of grammar and lexicon in aphasia. *Cortex* 1976;**12**:49–60.
5. Sethi NK, Burke L, Torgovnick J, et al. Transcortical sensory aphasia as a result of left frontal cortical-subcortical infarction. A case report. *Eur Neurol* 2007;**57**:52–3.
6. Armstrong E, Falk D, editors. *Primate Brain Evolution: Methods and Concepts*. New York: Plenum Press; 1982. p. 203–16.
7. Ferro JM, Mariano G, Madureira S. Recovery from aphasia and neglect. *Cerebrovasc Dis* 1999;**9**(Suppl. 5):6–22.

Lymph node metastasis of medulloblastoma in a young adult

A. Frankel*, Q. Lau, S. Olson

Princess Alexandra Hospital, Department of Neurosurgery, Ipswich Rd, Woolloongabba, Queensland 4102, Australia

ARTICLE INFO

Article history:

Received 5 August 2008

Accepted 8 January 2009

Keywords:

Adult

Desmoplastic medulloblastoma

Neoplasm metastasis

ABSTRACT

Medulloblastoma is the commonest primary central nervous system malignancy in childhood, but is rare in adults. Rarer still is metastasis of such a tumour to a lymph node. This report describes such a case, and briefly discusses relevant pathophysiology and epidemiology.

© 2009 Elsevier Ltd. All rights reserved.

1. Introduction

Medulloblastoma is a cerebellar tumour of neuroepithelial origin. It is highly malignant; however, extraneural metastases are rare.¹ It is an exceptionally radiosensitive tumour, and two recent prospective studies found overall 5-year survival rates of 75% and 89.7% respectively.^{2,3} Most cases are found in children.^{1,4} This report describes a patient with a metastatic medulloblastoma in the cervical lymph node of a young female adult. The histology, imaging, and insights from the literature are discussed.

2. Case report

The patient was a 23-year-old woman, who had a 5 cm desmoplastic medulloblastoma in her left cerebellopontine angle (Fig. 1). In comparison with children, nearly 50% of adult medulloblastomas are eccentrically located within the cerebellar hemisphere, and tend to be poorly defined with less contrast enhancement. The tumour was surgically resected, followed by radiotherapy (36 Gy in 20 fractions to the craniospinal axis, with a posterior fossa boost of 18 Gy in 10 fractions). Her postoperative MRI scan showed no evidence of residual tumour, and sub-

sequent MRI scans at routine follow-up appointments showed no recurrence.

One year later, she represented with left cervical lymphadenopathy of 2 months duration. Histological examination of a fine-needle aspirate showed a dissociated population of large atypical cells.

Unfortunately, no clinical history was submitted with the sample, and so it was interpreted as a large cell non-Hodgkin's lymphoma. A subsequent excisional biopsy of the lymph node was received with the appropriate history, and after immunohistochemical investigation (Supplementary Fig. 1), the diagnosis of metastatic medulloblastoma with progression to large cell/ana-plastic morphology was made.

A further year on, she was receiving palliative chemotherapy and radiotherapy. She has multiple sclerotic vertebral, sacral and iliac lesions, as well as histologically-proven metastases to her breasts, left cervical region and head.

3. Discussion

Dissemination of medulloblastoma via the cerebrospinal fluid is well documented.^{4–6} In contrast, extraneural metastasis is rare – between 4.8%⁵ and 7.1%.⁶ When it does occur, the usual site is bone. Although even less common, metastases to lymph nodes have been reported. Rochkind et al. found that only 33% of those with proven metastases were nodal in origin.⁶ The distinction

* Corresponding author. Tel.: +61 7 3240 6949; fax: +61 7 3240 7474.
E-mail address: adam_frankel@health.qld.gov.au (A. Frankel).