

# Lacunar Infarction as an Embolic Complication of Cardiac and Arch Angiography

Anh Cacciatore, MD, and Louis S. Russo Jr., MD

**Background:** Lacunar infarcts are small, deep cerebral infarcts resulting from occlusion of small, penetrating cerebral arteries. They are most commonly associated with hypertension. Cardiac sources of embolization are sometimes present in patients with lacunes, but direct proof of a causal relationship is lacking. This report attempts to support the contention that emboli can cause lacunar syndromes and lacunar infarction.

**Case Descriptions:** We report two cases of pure motor hemiplegia, each of which developed while the patient was undergoing cardiac or aortic arch angiography. Neither patient had a history of previous transient ischemic attack or stroke. Initial computed tomography of the brain was normal in each. Repeat computed tomography in one confirmed a small, low-density lesion in the posterior limb of the internal capsule on the side appropriate to the patient's symptoms and remained normal in the second patient.

**Conclusions:** These two cases offer evidence that the classic lacunar stroke syndrome of pure motor hemiplegia can occur on an embolic basis. (*Stroke* 1991;22:1603–1605)

Lacunes are small, deep infarcts found almost exclusively in the lenticular nucleus, caudate, thalamus, pons, and internal capsule. In the mid 1960s, the classical theory of lacunes was developed from the detailed works of Fisher and colleagues.<sup>1–4</sup> Fisher described several lacunar syndromes<sup>2</sup> and provided pathological evidence of an underlying microvascular disorder, lipohyalinosis.<sup>3</sup> Fisher himself, however, questioned whether emboli could give rise to lacunes.<sup>3</sup> Subsequent pathological and radiological studies have suggested,<sup>5–7</sup> but not proven, the relationship between embolic stroke and lacunar syndromes. We present two cases of pure motor hemiplegia, which occurred during cardiac and arch angiography, as supporting evidence that emboli can cause lacunar infarction.

## Case Reports

### Case 1

A 48-year-old hypertensive male with non-insulin-dependent diabetes was admitted following an acute myocardial infarction. He was without neurological symptoms on admission. He was treated with tissue

plasminogen activator and was stable for the first 24 hours of hospitalization, at which point cardiac catheterization was performed. No mural thrombus was seen in the left ventricle. During the left ventricular injection, the patient experienced the sudden onset of left-sided weakness. There was no evidence of transient cardiac arrhythmia, hypotension, or hypertension. He was examined by one of us within minutes of onset.

The patient's blood pressure was 158/86 mm Hg, pulse rate 96 and regular, respiration rate of 20 breaths/min, and temperature of 98.8°F. General physical exam was unchanged from that before catheterization. Neurological examination revealed an alert man who was oriented to time, place, and person. His memory for recent and remote events was normal. He recalled three of three objects at 5 minutes. Spontaneous speech, comprehension, repetition, and naming were normal. He showed no signs of denial of illness or hemispatial neglect. Mapping ability was normal. No errors were made in a line cancellation task. Cranial nerve function was intact except for a moderate left, central facial paresis. Motor exam was normal in the right-sided extremities. The left arm and leg showed no volitional movement, flaccid tone, and hypoactive tendon reflexes. Sensory exam showed normal appreciation of pin, touch, joint-position sense, vibration, graphoesthesia, stereognosis, and two-point discrimination. He did not extinguish the left side on double simul-

From the Departments of Internal Medicine (A.C.) and Neurology (L.S.R.), University of Florida Health Science Center/Jacksonville, Fla.

Address for correspondence: Louis S. Russo Jr., MD, Department of Neurology, UFHSC/Jacksonville, 655 West 8th Street, Jacksonville, FL 32209.

Received June 4, 1991; accepted August 23, 1991.

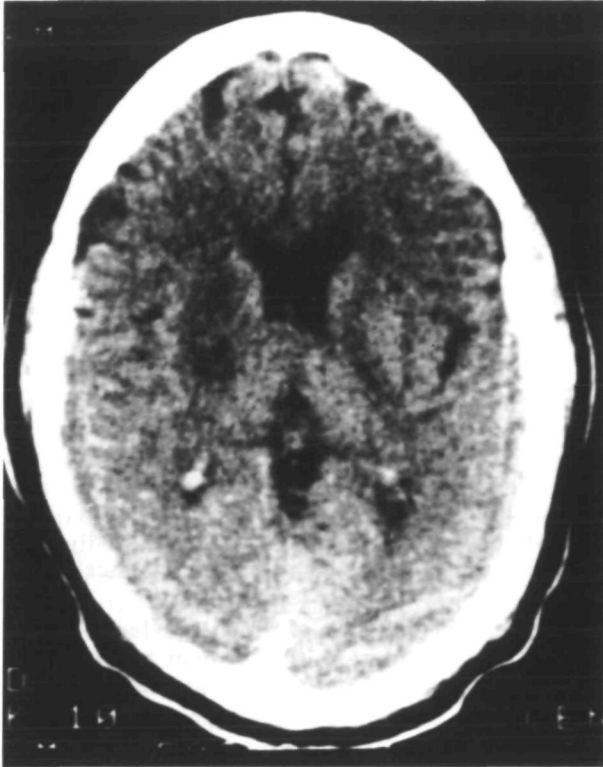


FIGURE 1. Unenhanced computed tomographic scan of the brain in case 1 on day 7.

taneous stimulation with pin. No cranial or carotid bruits were heard.

A computed tomographic (CT) scan of the brain done within the first 4 hours was normal. Carotid ultrasound revealed minimal atherosclerotic disease at the origin of both internal carotid arteries. He was treated with aspirin and antihypertensive medication. He began to regain strength within the first week and was ambulating with a cane and ankle-foot orthosis within 3 weeks. A repeat CT scan done on day 14 (Figure 1) revealed a well-defined, low-density lesion in the posterior limb of the right internal capsule.

#### Case 2

A 61-year-old hypertensive female with non-insulin-dependent diabetes was admitted for evaluation of a suspected thoracic aortic aneurysm. No neurological symptoms were present on admission. Admission physical examination was normal. While undergoing arch aortography, she experienced the sudden onset of right-sided weakness. This was unaccompanied by change in vital signs or mental status.

Initial neurological examination was performed within 1 hour of onset. The patient's blood pressure was 170/100 mm Hg, pulse rate 82 and regular, respiration rate 14 breaths/min, and temperature 99°F. General physical examination was unchanged from admission. Neurological examination revealed an alert woman who was fully oriented. Memory for remote and recent events was normal. She recalled three of three objects at 5 minutes. Spontaneous

speech was normal, as were comprehension and repetition. There was no difficulty with naming, calculation, finger recognition, or left-right orientation. Cranial nerve function was normal except for a mild right, central facial paresis. Motor function was normal on the left side. The right-sided extremities showed a dense hemiplegia, with flaccid tone and hypoactive tendon reflexes. A Babinski sign was present on the right. Pin, touch, joint-position sense, and vibration were normally appreciated throughout. Graphesthesia, stereognosis, and two-point discrimination were normal. There was no extinction of either side on double simultaneous testing with pin. No cranial or carotid bruits were heard.

A CT scan of the brain done within the initial 6 hours was normal, as was one repeated 10 days later. She was treated with aspirin and antihypertensive medication. Strength began to return on the right side within 96 hours; significant improvement was apparent within 3 weeks. Three months after the event, she was left with minimal weakness in the right side and was ambulatory without assistance.

#### Discussion

In 1965, Fisher and Curry<sup>4</sup> described detailed autopsies of nine cases of pure motor hemiplegia and established the clinicopathologic relationship between this syndrome and lacunar infarction. Hypertension was present in 96–98% of patients with these infarcts, and Fisher postulated that hypertension produced a specific intracerebral arteriolar lesion, lipohyalinosis, that caused lacunes. More than 10 years later, he provided the pathological evidence to support this theory, with extensive reports on 11 cases of capsular infarcts.<sup>3</sup> Of these 11 patients with infarcts, nine were shown to have underlying microvascular disease. Only one, however, had lipohyalinosis. Embolism was mentioned as a possible explanation for the remaining two cases because the penetrating arteries in the distribution of the infarct showed no pathologic change.

In a subsequent pathologic review of 169 patients with 327 lacunar infarcts, Tuszynski et al<sup>5</sup> demonstrated a source of emboli in more than 30% of those cases with no hypertension or disease in the perforating arteries at the base of the brain. This high prevalence was derived by using liberal criteria in defining possible embolic sources; in addition to known rheumatic heart disease with atrial fibrillation, they included generalized atherosclerosis and presumed nonbacterial thrombotic endocarditis not persisting at autopsy. Demonstration of a source of emboli, however, does not prove a cause-effect relationship between embolic stroke and lacunes.

More recent clinical studies, using CT scans in the diagnosis of lacunes, have also raised the possibility that microemboli can obstruct deep penetrating arteries and produce lacunes.<sup>6,7</sup> Pullicino et al<sup>6</sup> reported possible cardiac and carotid sources of emboli in 33% of 38 cases with small, deep lesions found on CT. Only two (5%) were considered to have a highly

probable source of emboli, however. In a later study of the relationship between embolism and infarction in the basal ganglia, Santamaria et al<sup>7</sup> reported eight cases of radiologically confirmed deep subcortical lesions with clear evidence of emboli. Only one patient had a classic lacunar syndrome, and this patient's CT revealed a large hemorrhagic lesion in the capsulolenticular region and caudate rather than a lacune. Hart et al,<sup>8</sup> in reporting strokes in patients with infective endocarditis, mentioned three cases of small subcortical infarcts. These infarctions, occurring in young patients during an acute illness known to produce embolic cerebral lesions, strengthen the association between emboli and lacunes. Unfortunately, clinical and radiological details are lacking.

In the two cases presented here, both patients had abrupt onset of pure motor hemiplegia shortly after the injection of radiographic contrast material. In each case, the patient was actively being monitored and there was no transient arrhythmia or change in blood pressure. The acuteness of the development of symptoms, the presence of maximal deficit immediately upon onset, and the rapid resolution speak for an embolic etiology. The clinical feature of pure motor hemiplegia is consistent with a lacunar syndrome in each case. In one, CT confirmed a small, deep infarct in the posterior limb of the internal capsule. Although hypertension was present in both cases, it is difficult to refute the temporal relationship between the injection of angiographic contrast and the onset of neurological symptoms.

One may question the ability of emboli to lodge in an individual small, penetrating artery as opposed to the proximal middle cerebral artery. In an animal study, Futrell et al<sup>9</sup> produced a model for embolic cerebral infarction by laser irradiation of the common carotid artery in rats. This induced a nidus for

platelet aggregation and secondary embolism. Several of the animals developed basal ganglia infarctions with the pathologic characteristics of lacunes.

In summary, our two cases provide the clinical hallmarks of embolic disease, the clinical characteristics of a known lacunar syndrome, and radiological proof of a small infarction in the posterior limb of the appropriate internal capsule. These two cases, although lacking angiographic or pathological proof, provide further evidence that lacunar infarction and pure motor hemiplegia can be caused by emboli. An embolic source, therefore, should be sought in patients with lacunar infarcts, especially those who lack the classic presence of hypertension.

#### References

1. Fisher CM: Lacunes: Small, deep cerebral infarcts. *Neurology* (Minneapolis) 1965;15:774-784
2. Fisher CM: Lacunar strokes and infarcts: A review. *Neurology* 1982;32:871-876
3. Fisher CM: Capsular infarcts: The underlying vascular lesions. *Arch Neurol* 1979;36:65-73
4. Fisher CM, Curry H: Pure motor hemiplegia of vascular origin. *Arch Neurol* 1965;13:30-45
5. Tuszynski M, Petito C, Levy D: Risk factors and clinical manifestations of pathologically verified lacunar infarctions. *Stroke* 1982;20:990-999
6. Pullicino P, Nelson R, Kendall B, Marshall J: Small deep infarcts diagnosed on computed tomography. *Neurology* 1980;30:1090-1096
7. Santamaria J, Graus F, Rubio F, Arbizu T, Peres J: Cerebral infarction of the basal ganglia due to embolism from the heart. *Stroke* 1983;14:911-914
8. Hart R, Foster J, Luther M, Kanter M: Stroke in infective endocarditis. *Stroke* 1990;21:695-700
9. Futrell N, Millikan C, Watson BD, Dietrich WD, Ginsberg M: Embolic stroke from a carotid arterial source in the rat: Pathology and clinical implications. *Neurology* 1989;39:1050-1056

KEY WORDS • cerebral infarction • embolism • hemiplegia • lacunar infarction



**Lacunar infarction as an embolic complication of cardiac and arch angiography.**  
A Cacciatore and L S Russo, Jr

*Stroke*. 1991;22:1603-1605

doi: 10.1161/01.STR.22.12.1603

*Stroke* is published by the American Heart Association, 7272 Greenville Avenue, Dallas, TX 75231

Copyright © 1991 American Heart Association, Inc. All rights reserved.

Print ISSN: 0039-2499. Online ISSN: 1524-4628

The online version of this article, along with updated information and services, is located on the  
World Wide Web at:

<http://stroke.ahajournals.org/content/22/12/1603>

**Permissions:** Requests for permissions to reproduce figures, tables, or portions of articles originally published in *Stroke* can be obtained via RightsLink, a service of the Copyright Clearance Center, not the Editorial Office. Once the online version of the published article for which permission is being requested is located, click Request Permissions in the middle column of the Web page under Services. Further information about this process is available in the [Permissions and Rights Question and Answer](#) document.

**Reprints:** Information about reprints can be found online at:  
<http://www.lww.com/reprints>

**Subscriptions:** Information about subscribing to *Stroke* is online at:  
<http://stroke.ahajournals.org/subscriptions/>