

# **New Pull-through Technique Using the Superficial Temporal Artery for Transbrachial Carotid Artery Stenting**

## **—Technical Case Report—**

Yutaka MITSUHASHI, Akimasa NISHIO, Taichiro KAWAKAMI,  
Kazunori SHIBAMOTO, Tohru YAMAGATA,  
Tsutomu ICHINOSE, and Kenji OHATA

*Department of Neurosurgery, Osaka City University, Graduate School of Medicine, Osaka*

### **Abstract**

Carotid artery stenting (CAS) is an effective and less invasive alternative to carotid endarterectomy for internal carotid artery (ICA) stenosis, but the guiding catheter is often technically difficult to introduce into the common carotid artery (CCA) in patients with concomitant atherosclerotic disease in the peripheral vessels or aorta. A new pull-through technique between the superficial temporal artery (STA) and the brachial artery was used to deliver the guiding catheter into the CCA safely and steadily. An 83-year-old male presented with repeated transient left hemiparesis caused by severe stenosis of the origin of the right ICA. He also had severe systemic atherosclerotic disease with occlusion of the bilateral femoral arteries. The innominate artery branched at an acute angle from the aorta. Therefore, catheterization of the right CCA seemed to be impossible using a conventional approach. The guidewire introduced from the right STA was lassoed by a loop snare wire and pulled out of the left brachial artery, forming the pull-through system. The guiding catheter could be introduced into the CCA from the left brachial artery over this guidewire. Subsequently, successful stent placement was performed under the distal protection. This new technique may facilitate safe and stable CAS even in patients with a severely tortuous access route due to concomitant atherosclerotic disease.

Key words: brachial approach, carotid artery, pull-through technique, stenting, superficial temporal artery

### **Introduction**

Carotid artery stenting (CAS) has recently been recognized as an effective and less invasive alternative to carotid endarterectomy for the treatment of internal carotid artery (ICA) stenosis because of the improvement of protection devices.<sup>8,17)</sup> In general, the transfemoral approach has been preferred for CAS, because of the size of the devices and the relative ease in introducing the guiding catheter into the common carotid artery (CCA). However, the transfemoral route is occasionally unavailable due to severe atherosclerotic stenosis or aneurysm of the femoral artery, iliac artery, or aorta. In such cases, the transbrachial approach can be used to perform CAS,<sup>1,3,14,16)</sup> but advancing the guiding catheter into the CCA may present some difficulties because of the tortuous access route. Various devices to solve this problem have been described, including the use of stiff guidewires or anchoring a PercuSurge GuardWire (Medtronic, Minneapolis, Minn., U.S.A.)

with its balloon inflated in the external carotid artery (ECA).<sup>3,14,16)</sup>

Here we describe a new technique to perform CAS via the left transbrachial approach, a pull-through method via the right superficial temporal artery (STA), which was used to treat a patient with symptomatic stenosis of the origin of the right ICA complicated by severe concomitant systemic atherosclerotic disease.

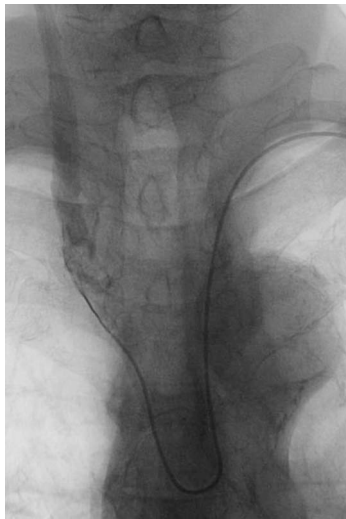### **Case Report and Technique**

An 83-year-old male was admitted to a previous hospital with angina pectoris and heart failure. During the hospitalization, he also suffered transient left motor weakness repeated several times a week for 3 months. These transient ischemic attacks (TIAs) were not suppressed by administration of aspirin (100 mg/day) and ticlopidine (200 mg/day). Therefore, the patient was referred to our institute after percutaneous coronary intervention (PCI).

Laboratory examination on admission showed no

Received June 18, 2008; Accepted January 15, 2009

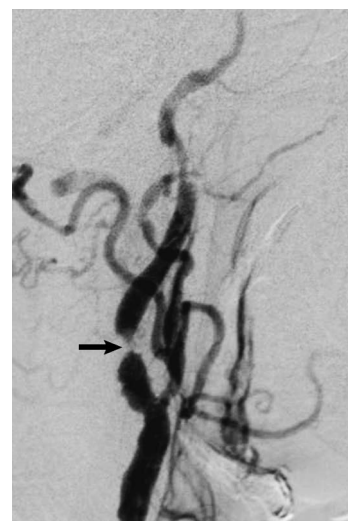particular abnormality including platelet count of  $151 \times 10^3/\text{mm}^3$ , prothrombin time of 11.8 seconds, and activated partial thromboplastin time of 39.4 seconds, except for the elevated brain natriuretic peptide level of 711 pg/ml suggesting the presence of severe heart failure. Magnetic resonance (MR) angiography showed severe stenosis of the right cervical ICA. The bilateral femoral arteries could not be palpated, and MR angiography demonstrated severe obstructive changes in these arteries. Ultrasonography demonstrated significant stenosis of the right brachial artery that did not allow PCI through this artery in the previous hospital. The PCI was completed by the left brachial approach. Therefore, we performed diagnostic cerebral angiography via the left brachial artery, which demonstrated a serious atherosclerotic ectatic change in the aortic arch, and the right innominate artery branching at an acute angle (Fig. 1). A 4F Simmons type diagnostic catheter could be barely inserted into the orifice of the right CCA, but could not be advanced further cranially. Severe stenosis (99%) in the origin of the right ICA was confirmed (Fig. 2), which was considered to be responsible for the TIAs. He had very severe chronic heart failure that did not allow general anesthesia. The stenosis in the right ICA was located in a relatively high position at the C2-3 intervertebral level. Furthermore, he had mild cognitive impairment, so had the risk of unexpected movement during the therapeutic procedure. Therefore, carotid endarterectomy did not seem to be suitable even under local anesthesia. Planning of CAS via the left transbrachial approach anticipated that catheterization of the right CCA and stabilizing the guiding catheter during the therapeutic procedures might be



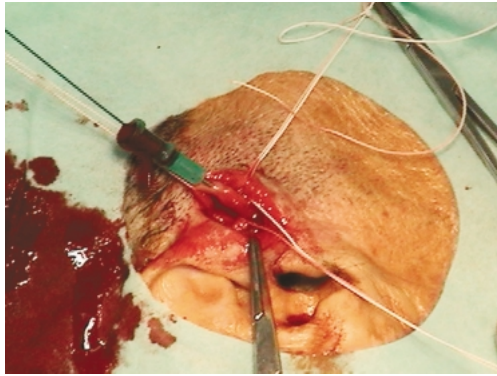
**Fig. 1** Angiogram via the left brachial artery showing the right innominate artery branching at an acute angle from the aorta, and tip of the diagnostic catheter placed just in the orifice of the right common carotid artery.

particularly difficult because of the very tortuous access route. Accordingly, we devised a pull-through technique between the left brachial artery and the right STA to achieve smooth and safe catheterization.

Under local anesthesia, 5F and 3F sheath introducers were inserted into the left and right brachial arteries, respectively. The right STA was exposed in the preauricular area, and an 18G cannula was inserted into the STA using a cut-down technique (Fig. 3). Systemic anticoagulation was initiated by intravenous bolus administration of 5,000 U of heparin, and activated coagulation time became 297 seconds. A snare wire with a 7-mm diameter loop (Goose-Neck Snare SK 700; Microvena, White Bear Lake, Minn., U.S.A.) was introduced through the right brachial artery into the right innominate artery. A 0.035-inch 300-cm guidewire was inserted from the right STA and introduced retrogradely into the ascending aorta through the right ECA, CCA, and innominate artery, then the tip of the guidewire was passed through the loop of the snare wire (Fig. 4A). This guidewire was lassoed in the ascending aorta with another snare wire with a 25-mm diameter loop (Goose-Neck Snare GN2500; Microvena), introduced from the left brachial artery, and pulled out of the left brachial sheath, thus completing the STA-brachial artery pull-through system (Fig. 4B). The 5F sheath in the left brachial artery was exchanged for a 6F 90-cm kink-resistant guiding catheter (Super Arrow-Flex sheath; Arrow International, Reading, Pa., U.S.A.). This 6F guiding catheter with an inner 4F catheter was introduced into the right CCA along the guidewire, passing through the loop of the snare wire introduced from the right brachial sheath (Fig. 4C). Then the 6F guiding catheter was firmly grasped with the loop snare,



**Fig. 2** Right common carotid angiogram showing severe stenosis (arrow) in the origin of the right internal carotid artery.



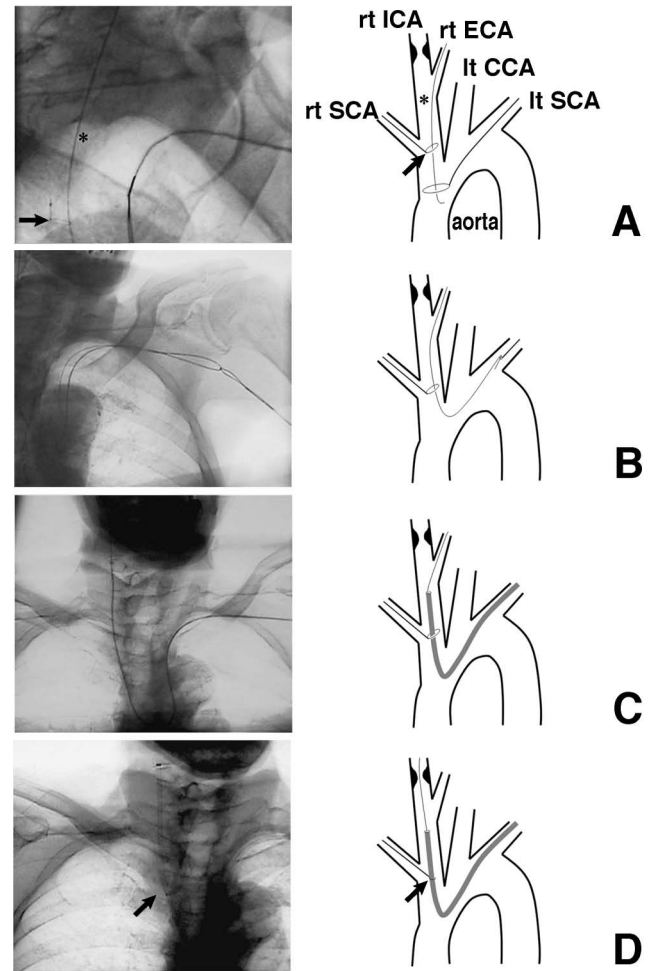
**Fig. 3** Photograph showing the right superficial temporal artery exposed in the preauricular area and cannulated.

and stabilized in the left CCA with tension loading through this snare wire. Next, the guidewire used for the pull-through method and the 4F inner catheter were removed. The ICA stenosis was crossed with a distal protection device (PercuSurge GuardWire) (Fig. 4D). A 3.5-mm  $\times$  20-mm balloon angioplasty catheter (Gateway; Boston Scientific, Boston, Mass., U.S.A.) was inserted across the lesion and predilation (6 atm, 30 sec) was performed, then an 8-mm  $\times$  20-mm stent (Precise; Cordis, Miami, Fla., U.S.A.) was deployed successfully. Subsequently, postdilation (10 atm, 5 sec) was carried out with a 5.5-mm  $\times$  20-mm balloon (Amiia; Cordis) under distal protection. During the procedure, the guiding catheter was firmly stabilized with the snare loop wire. Final angiography showed adequate dilation of the stenosis (Fig. 5). Hemostasis at the puncture sites of the bilateral brachial arteries was established by manual compression, the exposed STA was ligated, and the wound was closed with nylon sutures. The total operation time was 105 minutes.

The patient has not experienced any further cerebral ischemic episodes during a 5-month follow-up period.

## Discussion

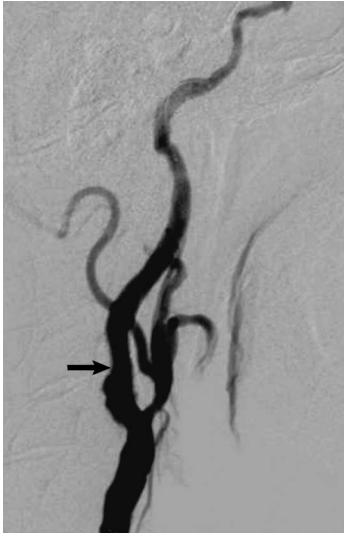The pull-through technique is a very useful way to introduce a catheter into a tortuous vessel, and was first reported in 1988 for interventional treatment of totally occluded iliac arteries.<sup>7,11)</sup> The stable wire tension provided by this technique enables safe and steady delivery of the catheter. Recently, a brachiofemoral or brachibrachial pull-through approach was described for the treatment of lesions in the innominate, subclavian, or vertebral arteries.<sup>9,10)</sup> Here we performed CAS with the pull-through method between the STA and the brachial artery. The STA is easy to expose in the preauricular area using a cut-down technique. The STA runs superficially on the galea, and a 15-mm skin incision is ade-



**Fig. 4** Intraoperative photographs and schemas of the procedure to introduce and stabilize the guiding catheter. **A:** The guidewire inserted from the right superficial temporal artery (asterisk) is introduced retrogradely into the ascending aorta through the loop of the snare wire (arrow) delivered from the right brachial artery. **B:** This guidewire is caught by another loop snare wire and pulled out of the left brachial sheath. **C:** The 6F guiding catheter is introduced into the common carotid artery (CCA) over the guidewire. **D:** Even after removing the guidewire used for pull-through method, the guiding catheter is fixed in place by the loop snare (arrow). ECA: external carotid artery, ICA: internal carotid artery, SCA: subclavian artery.

quate. Percutaneous puncture may also be used if the STA has a straight course.

If the guidewire used for the pull-through method can be placed across the lesion on a vessel, such as the iliac, innominate, or subclavian artery, the angioplasty balloon or stent can be delivered over this



**Fig. 5** Right common carotid angiogram showing the stenosis in the internal carotid artery adequately dilated (arrow).

guidewire.<sup>7,9,11</sup>) However, in the present case, the angioplasty and stenting devices had to be delivered separately into the ICA from the guidewire placed for the pull-through method through the ECA. A guiding catheter with a large diameter would be required to deliver both the pull-through guidewire and the therapeutic devices. Recently, a case of stenosis in the left vertebral artery origin was successfully treated by stent placement using the brachio-brachial pull-through method.<sup>10</sup> An 8F guiding catheter was introduced into the left subclavian artery from the right brachial artery over the pull-through system between the bilateral brachial arteries, and devices were delivered for distal protection, angioplasty, and stenting into the left vertebral artery, as well as the guidewire used for pull-through method through the 8F guiding catheter. No hemodynamic events occurred in the forearm despite the use of the guiding catheter with a relatively large diameter.<sup>10</sup> However, use of the smallest guiding system possible will reduce the possibility of complications at the puncture site including insufficient blood flow in the forearm.<sup>4,5,12</sup>)

In our case, the left brachial artery also revealed some atherosclerotic stenosis, so minimizing the size of the guiding system was important. The pull-through guidewire had to be removed to deliver the devices for following angioplasty and stenting through the 6F guiding catheter. We did not have confidence in the stability of the guiding catheter without the pull-through guidewire. Therefore, we used the loop snare wire technique for grasping the guiding catheter, which enabled us to stabilize the guiding catheter even after removal of the guidewire used for the pull-through method, and reduce the size of the guiding catheter. By passing the guidewire for the pull-through method through the loop

snare early in the operation, the guiding catheter was technically easy to lasso. This technique was previously used in the subclavian artery for stenting into the vertebral or basilar artery.<sup>18</sup>)

Direct access to the cervical CCA has been proposed in cases with limited transfemoral access for CAS.<sup>2,6,13,15</sup>) Hemostasis after percutaneous direct puncture of the CCA is not considered to be easy under anticoagulant or antiplatelet agent administration. Hematoma formation from the puncture site might cause serious respiratory complications. Recently, direct cervical carotid access via a small skin incision was reported.<sup>2,13</sup>) Direct suture of the arterial wall allowed by this technique may reduce the risk of the postoperative hemorrhagic complication at the puncture site. In the present case, we also considered this method of direct access to cervical CCA. However, we were concerned about possible uncooperative and unexpected movements of this patient with cognitive impairment, which might cause serious complications such as pulling out of the sheath introducer from the CCA accidentally during the interventional procedures. The STA is a small and non-eloquent artery, and thus hemostasis is relatively easy to obtain. There are no life-threatening structures around the preauricular STA. Percutaneous direct access to the STA carries lower risk of hemorrhagic complications around the access route than direct access to the cervical CCA.

The present case illustrates that the pull-through method using the STA is technically feasible and useful if introduction of the guiding catheter into the carotid artery is difficult due to a tortuous access route. The indications for CAS may be extended by this technique.

## References

- 1) Akaji K, Tanizaki Y, Hiraga K, Akiyama T, Dembo T: [A case of carotid stenting via the transbrachial approach in the bovine arch]. *No Shinkei Geka* 34: 319-323, 2006 (Jpn, with Eng abstract)
- 2) Alexandrescu V, Ngongang C, Proumen J, Dejardin H, Serbanescu R, Horion J, Bour A: Filter-protected carotid stenting via a minimal cervical access with transitory aspirated reversed flow during initial passage of the target lesion. *J Endovasc Ther* 13: 196-204, 2006
- 3) Al-Mubarak N, Vitek JJ, Iyer SS, New G, Roubin GS: Carotid stenting with distal-balloon protection via the transbrachial approach. *J Endovasc Ther* 8: 571-575, 2001
- 4) Basche S, Eger C, Aschenbach R: The brachial artery as approach for catheter interventions — indications, results, complications. *Vasa* 33: 235-238, 2004
- 5) Connors JJ III, Wojak JC: Brachiocephalic angioplasty and stenting: vertebral artery origin, in Connors JJ III, Wojak JC (eds): *Interventional Neuroradiology. Strategies and Practical Techniques*. Philadelphia, WB Saunders, 1999, pp 493-499

- 6) Diethrich EB, Marx P, Wrasper R, Reid DB: Percutaneous techniques for endoluminal carotid interventions. *J Endovasc Surg* 3: 182-202, 1996
- 7) Gaines PA, Cumberland DC: Wire-loop technique for angioplasty of total iliac artery occlusions. *Radiology* 168: 275-276, 1988
- 8) Goodney PP, Schermerhorn ML, Powell PJ: Current status of carotid artery stenting. *J Vasc Surg* 43: 406-411, 2006
- 9) Harada K, Nakahara I, Tanaka M, Iwamuro Y, Watanabe Y, Fujimoto M: [Therapeutic strategy and outcome of stenting for subclavian and innominate artery occlusive disease]. *No Shinkei Geka* 32: 151-158, 2004 (Jpn, with Eng abstract)
- 10) Kusaka N, Tamiya T, Nishiguchi M, Takayama K, Nishiura T: Bilateral brachial pull-through technique for stenting in a patient with stenosis of the vertebral artery origin: technical case report. *Neuroradiology* 49: 837-839, 2007
- 11) Loose HW, Ryall CJ: Common iliac artery occlusion: treatment with pull-through angioplasty. *Radiology* 168: 273-274, 1988
- 12) Manninen HI, Kaukanen ET, Ikäheimo R, Karhapää P, Lahtinen T, Matsi P, Lampainen E: Brachial arterial access: endovascular treatment of failing Brescia-Cimino hemodialysis fistulas—initial success and long term results. *Radiology* 218: 711-718, 2001
- 13) Matsumoto H, Hujita K, Miki J, Tuji N, Terada T, Itakura T: [Direct carotid approach for carotid angioplasty and stenting with a small incision: A technical case report]. *No Shinkei Geka* 32: 735-740, 2004 (Jpn, with Eng abstract)
- 14) Nanto M, Tsuura M, Takayama M, Hirayama K, Okada H, Naka D, Kamei I: [Carotid artery stenting via a transbrachial artery: techniques and problems]. *No Shinkei Geka* 35: 155-160, 2007 (Jpn, with Eng abstract)
- 15) Perez-Arjona EA, DelProsto Z, Fessler RD: Direct percutaneous carotid artery stenting with distal protection: technical case report. *Neurol Res* 26: 338-341, 2004
- 16) Wu CJ, Cheng CI, Hung WC, Fang CY, Yang CH, Chen CJ, Chen YH, Hang CL, Hsieh YK, Chen SM, Yip HK: Feasibility and safety of transbrachial approach for patients with severe carotid stenosis undergoing stenting. *Catheter Cardiovasc Interv* 67: 967-971, 2006
- 17) Yadav JS, Wholey MH, Kunts RE, Fayad P, Katzen BT, Mishkel G, Bajwa TK, Whitlow P, Strickman NE, Jaff MR, Popma J, Snead DB, Cutlip DE, Firth BG, Ouriel K: Stenting and angioplasty with protection in patients at high risk for endarterectomy investigators: Protected carotid-artery stenting versus endarterectomy in high-risk patients. *N Engl J Med* 351: 1493-1501, 2004
- 18) Yoneda K, Matsui O, Sanada J, Kusanagi M, Okamoto Y, Kida S: Usefulness of grasping a guiding catheter with a loop-snare wire for stent placement into the vertebrobasilar artery. *Cardiovasc Intervent Radiol* 29: 646-649, 2006

Address reprint requests to: Yutaka Mitsuhashi, M.D., Department of Neurosurgery, Osaka City University, Graduate School of Medicine, 1-4-3 Asahi-machi, Abeno-ku, Osaka 545-8585, Japan.  
e-mail: y-mitsuhashi@mtf.biglobe.ne.jp

## Commentary

In this Technical Case Report, the authors describe a new pull-through technique using the superficial temporal artery (STA). As far as I know, this technique has not been reported previously, so this is the first report introducing this new technique. This technique, however, is not difficult at all. This is a combination of the standard technique for carotid artery stenting (CAS), pull-through technique, transbrachial holding using the Goose-Neck Snare, and cut-down technique. The important points of the report are some modification of each standard technique. The pull-through technique usually makes a loop between the femoral artery and brachial artery, but the authors made the loop between the left brachial artery and right STA. A 4F or 5F catheter is usually used for the trans-brachial approach, but they used a 3F catheter into the right brachial artery. Cut-down of the common carotid artery is a well-known method for CAS, but STA is not. Such kinds of small modifications result in a great modification which was not previously considered. The introduction of a guiding system is the most important and difficult step in the CAS procedure, especially in elderly patients. The CAS procedure will be successful in more than half of cases if we succeed in introduction of the guiding system. So, it is very important that we have as many choices for introducing the guiding system as possible in the CAS procedure for elderly patients. This new technique will surely be added as one of the choices for the CAS procedure.

Masayuki EZURA, M.D.  
Department of Neurosurgery  
Sendai Medical Center  
Sendai, Japan

Carotid stenting has been validated on the basis of randomized clinical trials. Mitsuhashi and colleagues have developed and shared a clever technique for access to the carotid artery to the catheter. This method is slightly invasive. However, I think that authors' method is important under the present conditions with many patients suffering severe arteriosclerosis in the aging society.

We also encountered a very difficult case of access to the carotid artery. In such a situation, the new type guide wire and coaxial catheter, and also cervical extension with bilateral head rotation may be valuable. I think endovascular surgery is the most important procedure to need many options. This technique provides a safe and easy method for access options during carotid stenting.

Yoshifumi KONISHI, M.D.  
Department of Neurosurgery  
Kyorin University School of Medicine  
Mitaka, Tokyo, Japan