

To the best of our knowledge, this is the first report describing prolonged (150 min) laparoscopic urological surgery in a child with SCD.

CAROLINE J. COOK*

JENNY THOMAS†

*Anaesthetic Registrar

†Associate Professor of Paediatric Anaesthesia,
Red Cross Children's Hospital,
Cape Town, South Africa
(email: cook136@hotmail.com).

References

- 1 Haxby E, Flynn F, Bateman C. Anaesthesia for patients with sickle cell disease or other haemoglobinopathies. *Anaesthesia and Intensive Care Medicine* 2007; **8**: 217–219.
- 2 Vichinsky EP, Haberkern C, Neumayr L *et al*. A comparison of conservative and aggressive transfusion regimens in the perioperative management of sickle cell disease. The Preoperative Transfusion in Sickle Cell Disease Study Group. *N Engl J Med* 1995; **333**: 206–213.
- 3 Wales PW, Carver E, Crawford MW *et al*. Acute chest syndrome after abdominal surgery in children with sickle cell disease: is a laparoscopic approach better? *J Pediatr Surg*, 2001; **36**: 718–721.
- 4 Goers T, Panepinto J, DeBaun M *et al*. Laparoscopic versus open abdominal surgery in children with sickle cell disease is associated with a shorter hospital stay. *Pediatr Blood Cancer* 2008; **50**: 603–606.

Low bispectral index values after treatment for seizures in Dandy-Walker syndrome

doi:10.1111/j.1460-9592.2009.02979.x

SIR—Bispectral index (BIS), an established tool to monitor depth of anesthesia has recently been proposed as an alternative to conventional electroencephalography (EEG) for monitoring seizure activity (1). Previously, an unusual low BIS value has been found associated with cerebral ischemia (2), dementia (3), and hydrocephalus (4). We encountered sustained low BIS in a child of Dandy-Walker syndrome after seizure control with barbiturates. An informed consent was obtained from the father of the patient prior to writing this report.

A 3-year-old male child, weighing 12 kg, known case of Dandy-Walker syndrome was admitted with complaints of refusal to feed and fever since 3 days. History for loss of consciousness and seizures was negative. He had undergone ventriculoperitoneal shunt surgery for hydrocephalus 10 days back. Noncontrast computed tomography revealed enlarged ventricles possibly a result of malfunctioning shunt. The child was taken up for an emergency

shunt revision surgery. Following an uneventful surgical and anesthetic course, child was shifted to ICU after tracheal extubation. Meanwhile, his culture report of cerebrospinal fluid revealed presence of pseudomonas. Three days later, child suffered generalized tonic-clonic seizures which didn't respond to intravenous phenytoin 200 mg and midazolam 2 mg. As seizures persisted, it was decided to infuse thiopentone. No sooner about 30 mg of thiopentone administration, seizures stopped completely. We were prompted to apply BIS monitor on this patient. The A-2000 BIS-monitor (Aspect Medical Systems, Newton, MA, USA) sensor was applied to the forehead. Surprisingly, very low BIS values were observed with a suppression ratio (SR) of 70–90%. At times the BIS value reached zero with 100% SR. [Figure 1] The values remained low for nearly an hour when it gradually increased to normal awake values as the child regained consciousness.

Though a decrease in BIS with administration of anticonvulsants is expected (1), a BIS value reaching zero after a low dose (2.5 mg·kg⁻¹) of thiopentone was unusual. This could probably be explained on basis of a possible low basal BIS value as a result of cerebral hypoperfusion. Low BIS values may be observed in patients with gross hydrocephalus due to cerebral hypoperfusion (4). Hydrocephalus as a result of malfunctioning shunt may have caused increased intracranial pressure with consequent decrease in cerebral perfusion and associated low BIS value. These already low BIS values could have reduced to zero after administration of barbiturates. Epileptogenic activity is generally known to increase BIS values (1), however associated abrupt reductions in BIS abolished with anticonvulsants have also been reported (5). Though a baseline BIS value before the event would have been helpful, we could not monitor BIS before or during seizures as quick control of seizures was our priority. It would not have been possible to employ conventional

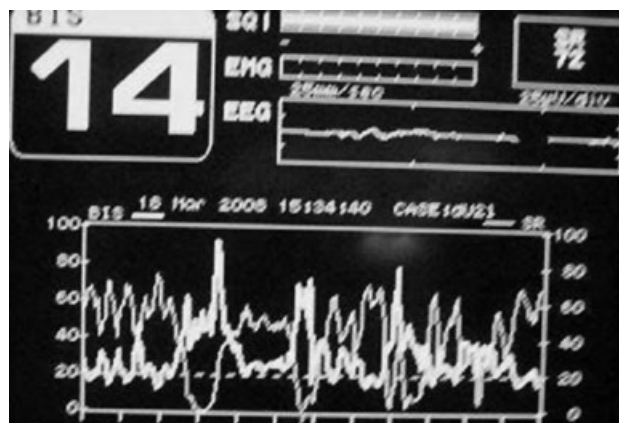


Figure 1
Bispectral index monitor showing persistent low values after small dose barbiturate administration.

EEG analyses during emergency situation. We feel that BIS monitoring may have a possible role in monitoring and interpretation of seizure activity, particularly when conventional EEG analyses are unavailable.

MADHUR MEHTA
ZULFIQAR ALI

HEMANSHU PRABHAKAR
GYANINDER PAL SINGH

Department of Neuroanaesthesiology,
All India Institute of Medical Sciences,
New Delhi-110029, India
(email: prabhakarhemanshu@rediffmail.com).

References

- 1 Tallach RE, Ball DR, Jefferson P. Monitoring seizures with bispectral index. *Anaesthesia* 2004; **59**: 1026–1036.
- 2 Prabhakar H, Ali Z, Rath GP *et al.* Zero bispectral index during coil embolization of intracranial aneurysm. *Anesth Analg* 2007; **105**: 887–888.
- 3 Renna M, Handy J, Shah A. Low baseline bispectral index of the electroencephalogram in patients with dementia. *Anesth Analg* 2003; **96**: 1380–1385.
- 4 Prabhakar H, Rath GP, Ali Z *et al.* Low baseline bispectral index values in a patient with gross hydrocephalus. *J Neurosurg Anesthesiol* 2008; **20**: 155–156.
- 5 Chinzei M, Sawamura S, Hayashida M *et al.* Change in bispectral index during epileptiform electrical activity under sevoflurane anesthesia in a patient with epilepsy. *Anesth Analg* 2004; **98**: 1734–1736.

Hypercapnia and tachycardia in a 2-year old

doi:10.1111/j.1460-9592.2009.02949.x

SIR—A 24-month-old boy presented for an open bilateral inguinal hernia repair and circumcision. His weight was 15 kg. His gestational and birth histories were unremarkable, as were his medical and developmental histories. He had no previous surgical history; his parents denied any familial history of anesthesia complications.

On arrival to the holding area his vital signs were: pulse (P) 110, blood pressure (BP) 80/40, respiratory rate (RR) 20, and temperature (T) 98°F. After an uncomplicated mask induction with sevoflurane in nitrous oxide 70% and oxygen 30%, a peripheral intravenous line was placed without difficulty. A 4.5 mm endotracheal tube was easily placed after 10 mcg of fentanyl and 10 mg of rocuronium. Postintubation vital signs were P 110, BP 90/55, T 97°F. ET_{CO}2 35.

The patient was maintained on 2.2% sevoflurane with fresh gas flows of 1 l each oxygen and air and placed atop a convection warming blanket. A Kimberly-Clark Ballard 1000 heat and moisture exchanger (HME) was inserted

between the endotracheal tube and the circle system Y-piece. The ventilator was set on pressure mode with peak inspiratory pressure of 16 cm (which resulted in a tidal volume of about 90 cc), a RR of 18 breaths per minute, and 5 cm H₂O of positive end expiratory pressure. The endtidal CO₂ (E_TCO₂) was 32 torr.

Twenty-five minutes after intubation the endtidal carbon dioxide had increased to 49 mmHg and the pulse concomitantly increased to 125. Temperature was stable at 98°F. In response we increased the fresh gas flow to 41% of oxygen and the ventilator's rate to 22 breaths per minute. Peak airway pressures did not change and breath sounds remained clear to auscultation. All other vital signs were stable. We removed the HME and in <3 min the ET_{CO}2 normalized and the tachycardia subsided.

Discussion

Our patient had hypercapnia associated with tachycardia. Our differential diagnosis included malignant hyperthermia, light anesthesia, faulty exhaust limb valve, thyroid storm, hypoventilation, increased dead space, and a malfunctioning CO₂ absorber. However, his prompt response after removal of the HME indicated to us that his hypercapnia was secondary to increased respiratory dead space after addition of the HME. The tachycardia was consequent to respiratory acidosis, which can stimulate the sympathetic nervous system.

Increased respiratory dead space because of HMEs in anesthesia circuits has been described previously (1,2). Several other investigators looking at mechanically ventilated patients in an intensive care setting have also found that HMEs may cause hypercapnia by increasing dead space (3,4). In addition to hypercapnia secondary to increased dead space, ventilation changes associated with HME's may include increased inspiratory and expiratory resistance along with mild increases in intrinsic positive end expiratory pressure (PEEP).

The intrathoracic dead space of this child is about 15.5 ml (5). The endotracheal tube, which was 15 cm long, added approximately 2.4 ml, making a total of about 17.9 ml. According to the HME's package, its dead space is 28 ml. Thus, adding this HME to the circuit increased the circuit's dead space by almost 70%.

We present this case to remind anesthesiologists that an HME in the pediatric population is a potential cause of hypoventilation with consequent hypercapnia and tachycardia while using the pressure control ventilation.

ANDREW KARLIN
UCHENNA UMEH

MICHAEL GIRSHIN

Metropolitan Hospital Center,
New York Medical College, New York, NY, USA
(email: m_girshin@yahoo.com)