



ELSEVIER

journal homepage: [www.elsevier.com/locate/epilepsyres](http://www.elsevier.com/locate/epilepsyres)



SHORT COMMUNICATION

# Na VPA-induced acute ischemic stroke in an epileptic patient with methylenetetrahydrofolate reductase gene polymorphism

Asuman Orhan Varoglu\*

Department of Neurology, Medical School, Ataturk University, 25240 Erzurum, Turkey

Received 8 January 2009; received in revised form 19 June 2009; accepted 28 June 2009

Available online 30 July 2009

## KEYWORDS

Methylenetetrahydrofolate reductase (MTHFR);  
Na-Valproic acid (VPA);  
Acute ischemic stroke;  
Homocysteine (Hcy);  
Epilepsy

**Summary** A 23-year-old man using Na-Valproic acid (VPA) was admitted to our clinic due to convulsion. The neurological examination revealed right hemiparesis. From the exitus notes, we learned that his two siblings had died from status epilepticus. Magnetic resonance imaging (MRI), MRI spectroscopy, and diffusion-weighted investigations (DWI) showed acute–subacute ischemic stroke in the left temporo-parieto-occipital region. The patient had an ischemic stroke. Heterozygote methylenetetrahydrofolate reductase (MTHFR) 677C/T polymorphism was determined on genetic examination. The homocysteine (Hcy) level was 18.2 mmol/l (5–15 mmol/l). So VPA treatment was stopped and oxcarbazepine treatment was started. MTHFR 677C/T polymorphism is associated with the risk of vascular diseases due to hyperhomocysteinemia. Heterozygote (MTHFR) 677C/T polymorphism has not been reported to be associated with epilepsy. In patients with heterozygote (MTHFR) 677C/T polymorphism and under long-term use of certain drugs the determination of Hcy plasma levels may be useful to prevent the development of atherothrombotic disease.

© 2009 Elsevier B.V. All rights reserved.

## Introduction

Methylenetetrahydrofolate reductase (MTHFR) plays essential roles in DNA synthesis, repair, and methylation. MTHFR irreversibly converts 5,10-methylenetetrahydrofolate, which is the predominant form of folate in plasma, to 5-methylenetetrahydrofolate. Then 5-methylenetetrahydrofolate catalyzed by methionine synthesis uses Vit B (12) as

a cofactor for the remethylation of homocysteine (Hcy) to methionine (Wang et al., 2009). It has been demonstrated that 677C/T and A1298C are common polymorphisms in MTHFR deficiency. In the literature, the rate of the C677T mutation of MTHFR varies from 5 to 22% (Cattaneo et al., 1997). According to a previous report, homozygotes and heterozygotes have an approximately 70 and 35% reduction of MTHFR activity in vitro, respectively (Zetterberg, 2004). MTHFR deficiency, which is an autosomal recessive disorder, results in hyperhomocysteinemia. Hyperhomocysteinemia is a possible risk factor for occlusive vascular diseases and epilepsy (Xu et al., 2008; Ono et al., 2002).

\* Tel.: +90 442 2317099; fax: +90 442 2361301.  
E-mail address: [asumanorhan@yahoo.com](mailto:asumanorhan@yahoo.com).

MTHFR polymorphisms are associated with elevated Hcy concentrations in epileptic patients receiving anticonvulsants (Caccamo et al., 2004; Yoo and Hong, 1999). Vilaseca et al. (2000) showed that plasma total Hcy concentration was high in epileptic children with the MTHFR 677C/T mutation who are taking Na-Valproic acid (VPA) as monotherapy. Another report showed that chronic VPA treatment decreased methionine adenosyltransferase activity in the rat brain (Carl, 1986). We found no previous reports of epileptic patients with heterozygote MTHFR deficiency.

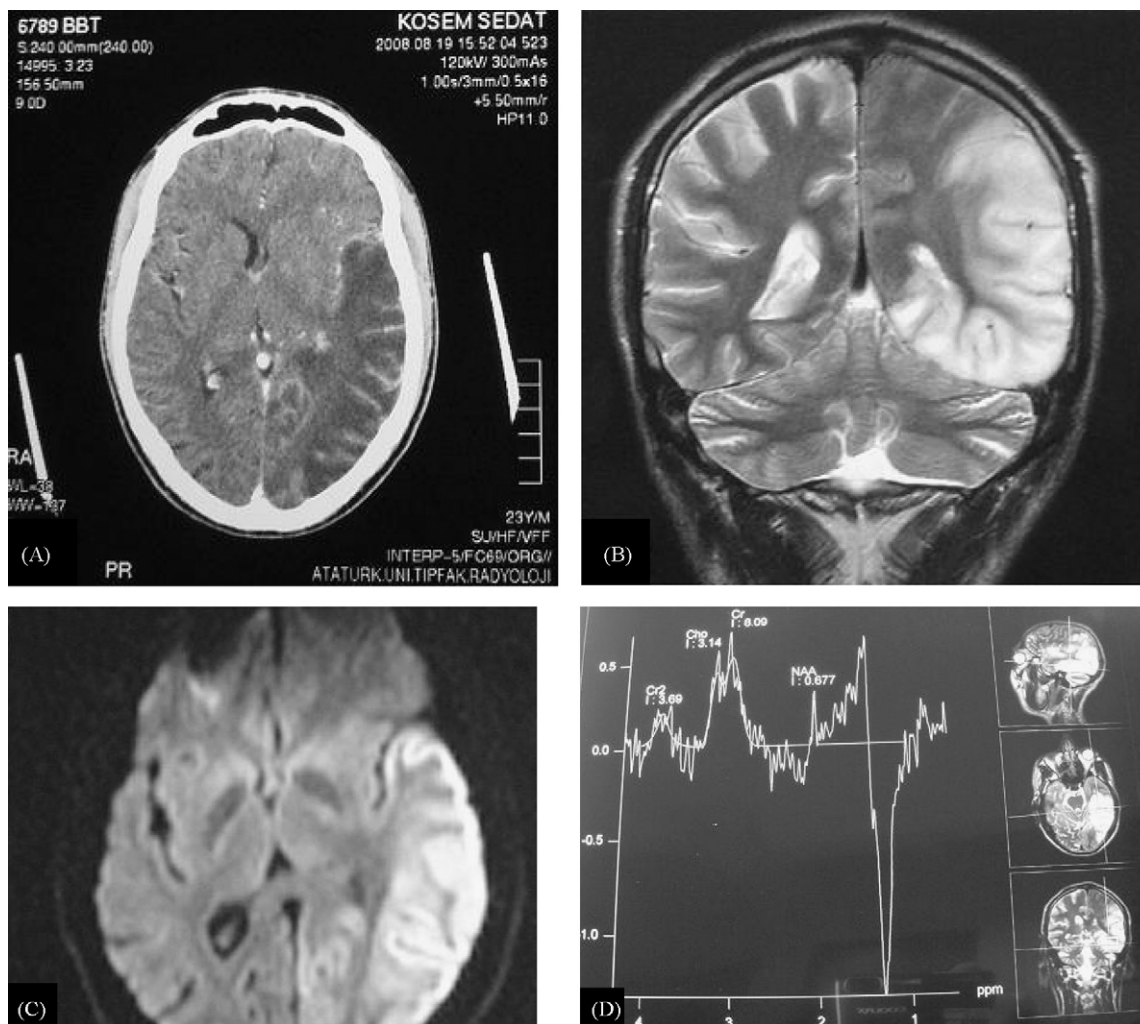
We report a patient with heterozygote MTHFR polymorphism and epilepsy associated with acute ischemic brain stroke. To our knowledge this is the first case of its kind in the literature.

## Case report

A 23-year-old male epileptic patient was admitted to our clinic, presenting with an abnormal mental status and convulsions. VPA was started following the fifth episode. These episodes began two months before VPA was started and con-

tinued more than two months. Computed tomography (CT) obtained two weeks before VPA therapy was unremarkable. The patient was hospitalized in another clinic for uncontrolled seizures before coming to our clinic. In this hospital, CT and MRI were evaluated as normal. There was neither stroke history in the early ages of life, nor genetic epilepsy in the family. According to the hospital documents, specifically the exitus notes, his two siblings had epilepsy and had died from seizures, but we did not have access to any document on these siblings, so there is no information available regarding the presence of the mutation in these two siblings.

At admission, the patient's neurological examination revealed loss of consciousness, right hemiparesis. Additionally, the plantar reflex was also extensor. Body temperature was 38.0°C. The slow activity appeared as commonly in the electroencephalography. After the stroke episode, CT showed a hypodense lesion (Fig. 1A), MRI showed T2-hyperintense lesion (Fig. 1B), and DWI showed hyperintense lesion (Fig. 1C) in the left temporo-parieto-occipital region. However, CT and MRI findings performed 10 days before the present radiologic evaluation were unremarkable. MRI spectroscopy showed a decreased N-acetylaspartate (NAA) peak



**Figure 1** (A) Computerize tomography. (B) Axial T2 MR image showing a lesion spreading at the left temporo-parieto-occipital region. (C) DW imaging showing hyperintensity observed at the left temporo-parieto-occipital region. (D) MRI spectroscopy showing decreasing NAA peak and the presence of lactate peak at the lesion.

and the presence of a lactate peak at the lesion (Fig. 1D). The CSF study was normal. Finally, the present case was diagnosed as ischemic stroke. Acyclovir was stopped and platelet inhibitor treatment was started. Transthoracic and transesophageal echocardiography and carotid artery Doppler were normal. The markers of collagen tissue diseases were negative. Some hematological markers such as fibrinogen, antithrombin, and protein C and S were also in normal ranges. Factor V Leiden and prothrombin G20210A gene mutations were not detected. The genetic analysis revealed that the patient had the heterozygote gene for 677C/T in the MTHFR enzyme. Both siblings were also heterozygotes. In our case, plasma Vit B (12) and folic acid were normal and plasma Hcy level was 18.2 mmol/l (5–15 mmol/l). In his siblings, plasma Vit B (12), folic acid, and Hcy level were normal. In the follow-up, we determined that his fourth sibling, who is still living, has also epilepsy. Before the acute ischemic stroke episode, the neurological examination was also completely normal. The first seizures were generalized tonic–clonic type. After the ischemic stroke, secondary generalized seizures began. Therefore, VPA was stopped and oxcarbazepine (1200 mg/day) was started. In addition, folic acid (174 mg) was given three times a day. Finally, the patient's neurological status was improved and the patient was discharged.

After two months, the patient was assessed in an outpatient clinic. The level of Hcy was 10 mmol/l (5–15 mmol/l) and plasma Vit B (12) and folic acid were normal.

## Discussion

MTHFR catalyzes the reduction of 5,10-methylenetetrahydrofolate to 5-methyltetrahydrofolate for the remethylation of homocysteine to methionine. In 1988, Kang et al. described a thermolabile variant (677C/T) of MTHFR, which is associated with decreased enzyme activity and mildly elevated Hcy plasma levels. Consequently, MTHFR deficiency may cause hyperhomocysteinemia and occlusive vascular diseases.

In the literature, there are some reports concerning the relationship between MTHFR 677C/T mutation and epilepsy (Wang et al., 2009; Yoo and Hong, 1999; Xu et al., 2008). In all of these reports, the MTHFR 677C/T mutation occurred as homozygote. Although there is some speculation about this association, the underlying pathophysiologic mechanism of the relationship between the MTHFR 677C/T mutation and epilepsy has not yet been identified. In the literature, there are two main speculations (Ono et al., 2000; Dean et al., 2008; Marangos et al., 1990). The first one, Ono et al. (2000) reported that seizures are related to cystathionine beta synthase deficiency in homocysteinuric patients, especially in the early infant period. In the second speculation, which was described by Dean et al. (2008), suggested that the production of increasing brain-derived neurotrophic factor for DNA hypomethylation may be responsible for the development of epilepsy in individuals with the MTHFR 677C/T polymorphism.

As mentioned above, living siblings have carried the same mutation and have a normal Hcy level, but one of them also developed epilepsy. The epilepsy in this family is associated with MTHFR 677C/T deficiency. Apart from hyperhomocys-

teinemia, we thought that there might also be different mechanisms involving the MTHFR 677C/T mutation and the development of epilepsy.

A high rate of the MTHFR 677C/T polymorphism is observed in epileptic patients (Yoo and Hong, 1999). From the literature, we know that the Hcy level increases in homozygote patients but not in heterozygote ones (Yoo and Hong, 1999). In a retrospective study on 55 Systemic Lupus Erythematosus patients, Afeltra et al. (2002) reported that levels of Hcy in plasma are in the normal range in five heterozygote cases. To our knowledge, there is no report concerning an elevated Hcy level in heterozygote MTHFR 677C/T deficiency. Our patient is the first case with epilepsy and heterozygote MTHFR 677C/T deficiency that developed acute ischemic stroke after VPA treatment.

It is well known that the use of antiepileptic drugs (AEDs) may lead to hyperhomocysteinemia by reducing the folic acid and Vit B (12) level. As previously reported, phenytoin and carbamazepine (CBZ), but not VPA, induced hyperhomocysteinemia with low folate status, probably by inducing hepatic microsomal enzyme (Yoo and Hong, 1999). The underlying mechanism for hyperhomocysteinemia due to VPA is unknown (Yoo and Hong, 1999). The relationship between serum folate, Vit B (12), and Hcy levels of patients receiving AEDs has been detailed in numerous reports of MTHFR 677C/T deficiency (Ono et al., 2000, 2002; Yoo and Hong, 1999; Vurucu et al., 2008). Ono et al. (2002) reported that folate deficiency was not observed in monotherapy patients, but hyperhomocysteinemia and low folate status occurred in homozygote patients receiving multidrug therapy. Vurucu et al. (2008) reported that low folate level and hyperhomocysteinemia were associated with the using of CBZ or VPA, and also C677T variants of the MTHFR gene have no contribution in hyperhomocysteinemia in epileptic patients receiving CBZ or VPA.

In the absence of other thrombophilic risk factors, the use of VPA may elevate Hcy levels as a side effect in patients without heterozygote MTHFR gene mutation (Sener et al., 2006; Karabiber et al., 2003; Verrotti et al., 2000; Attilakos et al., 2006; Vurucu et al., 2008).

The reduction of serum Vit B (12) and folate levels, and hyperhomocysteinemia is common in the use of CBZ, phenytoin, or phenobarbital treatment. Few studies have shown that there is a negative correlation between low folate status and hyperhomocysteinemia in patients treated with hepatic enzyme inductor AEDs such as CBZ, phenytoin, phenobarbital, or pirimidon. Some authors have suggested that cofactors and Hcy levels do not usually change because VPA is a hepatic enzyme inhibitor (Apeland et al., 2000; Fernández-Miranda et al., 2005; Kishi et al., 1997).

Folic acid and Vit B (12) supplementation are suggested in patients with low folate status, a low Vit B (12) level, and hyperhomocysteinemia in order to prevent the development of occlusive vascular disease (Yoo and Hong, 1999). In our case, we administered folic acid (174 mg) three times a day, although the levels of folic acid and Vit B (12) were within the normal range. After two months, the patient was assessed in an outpatient clinic. His neurological examination and plasma Hcy level were normal. Therefore, we thought that the cause of the reduced Hcy level in our case may be ceasing the VPA treatment.

VPA is a widely used antiepileptic drug, but may have serious side effects. In the rat model, it was demonstrated that the mechanism underlying VPA toxicity is the alterations in the methionine cycle (Ubeda et al., 2002). In another report, Hendel et al. (1984) showed that the absorption of folic acid decreased but liver metabolism did not change due to VPA therapy. However, several studies implicated that treatment with VPA was used safely to treat low folate and Vit B (12) status and hyperhomocysteinemia in epileptic patients (Vurucu et al., 2008; Gidal et al., 2005). In contrast, in our case, hyperhomocysteinemia was observed with VPA use.

In the present case, we do not have any imaging findings of the vascular territories of intracranial vessels, but we do have imaging findings of normal carotid arteries. Some studies have reported that serum levels of Hcy were not correlated with the carotid intima-media thickness in patients having this mutation with ischemic stroke (Ntaios et al., 2008; Mousavi et al., 2006).

To our knowledge, there no information regarding the decreased Hcy level leads to acute ischemic stroke. We found no report about the relationship between the duration of exposure to hyperhomocysteinemia and the risk of acute ischemic stroke in the literature.

Heterozygote MTHFR 677C/T polymorphism has not been reported to be definitively linked to epilepsy. There has not even been hyperhomocysteinemia due to heterozygote MTHFR 677C/T polymorphism reported. In our case, although heterozygote MTHFR 677C/T polymorphism was determined, hyperhomocysteinemia was found (18.2 mmol/l). We present a case with epilepsy and heterozygote MTHFR polymorphism associated with acute ischemic brain injury after using VPA.

In conclusion, we may suggest that heterozygote MTHFR gene variant analysis should be taken into consideration in patients with family history of epilepsy, especially in the presence of hyperhomocysteinemia. It is important to measure the homocysteine level, particularly when using drugs for a long time period in patients with this deficiency, because careful follow-up of patients with heterozygote MTHFR 677C/T deficiency might be life-saving.

## Conflicts of interest

The author has no conflict of interest to disclose.

## References

- Afeltra, A., Amoroso, A., Mitterhofer, A.P., Vадacca, M., Galuzzo, S., Francia, A., Del Porto, F., Gandolfo, G.M., 2002. The 677C → T mutation in the methylenetetrahydrofolate reductase (MTHFR) gene in epileptic patients affected by systemic lupus erythematosus. *Seizure* 11, 250–254.
- Apeland, T., Mansoor, M.A., Strandjord, R.E., Kristensen, O., 2000. Homocysteine concentrations and methionine loading in patients on antiepileptic drugs. *Acta Neurol. Scand.* 101, 217–223.
- Attilakos, A., Papakonstantinou, E., Schulpis, K., Voudris, K., Katsarou, E., Mastroianni, S., Garoufi, A., 2006. Early effect of sodium valproate and carbamazepine monotherapy on homocysteine metabolism in children with epilepsy. *Epilepsy Res.* 71 (2–3), 229–232.
- Caccamo, D., Condello, S., Gorgone, G., Crisafulli, G., Belcastro, V., Gennaro, S., Striano, P., Pisani, F., Lentile, R., 2004. Screening for C677T and A1298C MTHFR polymorphisms in patients with epilepsy and risk of hyperhomocysteinemia. *Neuromol. Med.* 6, 117–126.
- Carl, G.F., 1986. Effect of chronic valproate treatment on folate-dependent methyl biosynthesis in the rat. *Neurochem. Res.* 11, 671–685.
- Cattaneo, M., Tsai, M.Y., Bucciarelli, P., Taioli, E., Zighetti, M.L., Bignell, M., Mannucci, P.M., 1997. A common mutation in the methylenetetrahydrofolate reductase gene (C677T) increases the risk for deep-vein thrombosis in patients with mutant factor V (factor V:Q506). *Arterioscler. Thromb. Vasc. Biol.* 17 (9), 1662–1666.
- Dean, J.C., Robertson, Z., Reid, V., Wang, Q., Hailey, H., Moore, S., Rasalam, A.D., Turnpenny, P., Lloyd, D., Shaw, D., Little, J., 2008. A high frequency of the MTHFR 677C > T polymorphism in Scottish women with epilepsy: possible role in pathogenesis. *Seizure* 17, 269–275.
- Fernández-Miranda, C., de la Peña, P., Penas, M., Saiz, R., Gómez, P., Gómez de la Cámara, A., 2005. Hyperhomocysteinemia and treatment with antiepileptic drugs. Effects of different doses of folic acid. *Med. Clin. (Barc)* 124, 521–524.
- Gidal, B.E., Tamura, T., Hammer, A., Vuong, A., 2005. Blood homocysteine, folate and vitamin B-12 concentrations in patients with epilepsy receiving lamotrigine or sodium valproate for initial monotherapy. *Epilepsy Res.* 64, 161–166.
- Hendel, J., Dam, M., Gram, L., Winkel, P., Jørgensen, 1984. The effects of carbamazepine and valproate on folate metabolism in man. *Acta Neurol. Scand.* 69, 226–231.
- Kang, S.S., Zhou, J., Wong, P.W.K., Kowalysyn, J., Strokosch, G., 1988. Intermediate homocysteinaemia: a thermolabile variant of methylenetetrahydrofolate reductase. *Am. J. Hum. Genet.* 43, 414–421.
- Karabiber, H., Sonmezgoz, E., Ozerol, E., Yakinci, C., Otlu, B., Yologlu, S., 2003. Effects of valproate and carbamazepine on serum levels of homocysteine, vitamin B12, and folic acid. *Brain Dev.* 25 (2), 113–115.
- Kishi, T., Fujita, N., Eguchi, T., Ueda, K., 1997. Mechanism for reduction of serum folate by antiepileptic drugs during prolonged therapy. *J. Neurol. Sci.* 145, 109–112.
- Marangos, P.J., Loftus, T., Wiesner, J., Lowe, T., Rossi, E., Browne, C.E., Gruber, H.E., 1990. Adenosinergic modulation of homocysteine-induced seizures in mice. *Epilepsia* 31, 239–246.
- Mousavi, S.A., Ghasemi, M., Hoseini, T., 2006. Association between plasma homocysteine concentrations and extracranial carotid stenosis. *Ann. Saudi Med.* 26 (2), 120–122.
- Ntaios, G., Savopoulos, C., Hatzitolios, A., Ekonomou, I., Destanis, E., Chryssogonidis, I., Chatzinikolaou, A., Pidonia, I., Karamitsos, D., 2008. Homocysteine and carotid intima-media thickness in ischemic stroke patients are not correlated. *Neuropsychiatr. Dis. Treat.* 4 (2), 477–479.
- Ono, H., Sakamoto, A., Mizoguchi, N., Sakura, N., 2000. Methylenetetrahydrofolate reductase 677C > T mutation and epilepsy. *J. Inherit. Metab. Dis.* 23, 525–526.
- Ono, H., Sakamoto, A., Mizoguchi, N., Sakura, N., 2002. The C677T mutation in the methylenetetrahydrofolate reductase gene contributes to hyperhomocysteinemia in patients taking anticonvulsants. *Brain Dev.* 24, 223–226.
- Sener, U., Zorlu, Y., Karaguzel, O., Ozdamar, O., Coker, I., Topbas, M., 2006. Effects of common anti-epileptic drug monotherapy on serum levels of homocysteine, vitamin B12, folic acid and vitamin B6. *Seizure* 15, 79–85.
- Ubeda, N., Alonso-Aperte, E., Varela-Moreiras, G., 2002. Acute valproate administration impairs methionine metabolism in rats. *J. Nutr.* 132, 2737–2742.
- Verrotti, A., Pascarella, R., Trotta, D., Giuva, T., Morgese, G., Chiarelli, F., 2000. Hyperhomocysteinemia in children treated with sodium valproate and carbamazepine. *Epilepsy Res.* 41 (3), 253–257.

- Vilaseca, M.A., Monrós, E., Artuch, R., Colomé, C., Farré, C., Valls, C., Cardo, E., Pineda, M., 2000. Anti-epileptic drug treatment in children: hyperhomocysteinaemia B-vitamins and the 677C → T mutation of the methylenetetrahydrofolate reductase gene. *Eur. J. Paediatr. Neurol.* 4, 269–277.
- Vurucu, S., Demirkaya, E., Kul, M., Unay, B., Gul, D., Akin, R., Gokçay, E., 2008. Evaluation of the relationship between C677T variants of methylenetetrahydrofolate reductase gene and hyperhomocysteinemia in children receiving antiepileptic drug therapy. *Prog. Neuropsychopharmacol. Biol. Psychiatry* 32, 844–848.
- Wang, M., Zhu, H., Fu, G., Wang, M., Zhang, Z., Lu, Q., Wang, S., Zhang, Z., 2009. Polymorphisms of methylenetetrahydrofolate reductase and methionine synthase genes and bladder cancer risk: a case-control study with metaanalysis. *Clin. Exp. Med.* 9, 9–19.
- Xu, X., Li, J., Sheng, W., Liu, L., 2008. Meta-analysis of genetic studies from journals published in China of ischemic stroke in the Han Chinese population. *Cerebrovasc. Dis.* 26, 48–62.
- Yoo, J.H., Hong, S.B., 1999. A common mutation in the methylenetetrahydrofolate reductase gene is a determinant of hyperhomocysteinemia in epileptic patients receiving anticonvulsants. *Metabolism* 48, 1047–1051.
- Zetterberg, H., 2004. Methylenetetrahydrofolate reductase and transcobalamin genetic polymorphisms in human spontaneous abortion: biological and clinical implications. *Reprod. Biol. Endocrinol.* 17, 2–7.