



# Acute Cardiac and Neurologic Decompensation in a High School Athlete

Roshan K. Vatthyam, MD, MPH, John R. Bates, MD, FACC, and Bruce F. Waller, MD, FACC, *Indianapolis, Indiana*

A 19-year-old African American man presented to a local emergency room with atrial flutter, dysarthria, and left-sided hemiparesis. He was previously healthy and a successful high school athlete. The patient decompensated and went into cardiac arrest. Two-dimensional echocardiography revealed biventricular dilation, severe systolic dysfunction, and a spongy myocardial appearance. Postmortem examination was diagnostic of biventricular noncompaction. Such a fulminant presentation of isolated ventricular noncompaction in a previously healthy and physically fit individual has not yet been described. (*J Am Soc Echocardiogr* 2009;22:1420.e1-1420.e3.)

**Keywords:** Noncompaction, Cardiomyopathy, Athlete, Arrhythmia, Death

## CASE PRESENTATION

A 19-year-old African American man presented to a local emergency room with palpitations, dysarthria, and left-sided hemiparesis. He had no prior medical conditions and was a successful high school athlete. Other than the requisite school-age physical examinations, he had undergone no additional preparticipation athletic screening. He had received National Collegiate Athletic Association scholarship offers to play basketball the following academic year. There was no history of alcohol or illicit drug use. Prior to arrival, the patient reported a 2-day history of nausea, vomiting, and malaise. Initial vital signs showed a temperature of 98.9°F, blood pressure of 102/80 mm Hg, and a heart rate of 150 beats/min. On physical examination, there were no cervical bruits or jugular venous distention. The lungs were clear. A cardiac examination demonstrated a regular tachycardic rhythm, with no murmurs, rubs, or gallops. The abdomen was benign, and no peripheral edema was present. A neurologic examination revealed left-sided hemiparesis and dysarthria.

Cardiac consultation was obtained for atrial flutter and a heart rate of 150 beats/min (Figure 1). The patient subsequently decompensated and went into cardiac arrest. His rhythm showed pulseless electrical activity, possibly from hypoxia. He was resuscitated and intubated. Two-dimensional echocardiography revealed biventricular dilatation, severe systolic dysfunction, and a spongy myocardial appearance (Figure 2, Video 1). Upon transfer to our institution, the patient remained in critical condition and was supported with ventilation and pressors. A nuclear brain perfusion scan showed no activity, and he was subsequently pronounced dead. A postmortem examination of the heart showed cardiomegaly (660 g) and biventricular dilatation with marked hypertrophy of the trabeculae carneae. There was spongelike expansion into the ventricular space. Several thrombi were entrapped within the trabecular meshwork. There was a near absence of epicardial fat. The findings were diagnostic of biventricular

noncompaction (Figure 3). Autopsy of the brain revealed bilateral cerebral infarcts involving the left temporal-parietal-occipital region (6-8 cm) and the right parietal region (3-4 cm).

## DISCUSSION

Isolated ventricular noncompaction (IVNC) is a rare cardiomyopathy caused by the intrauterine arrest of compaction of myocardial fibers during organ development.<sup>1</sup> Isolated ventricular noncompaction is manifested by the presence of deep ventricular intertrabecular recesses in hypertrophied and often hypokinetic segments.<sup>2</sup> This diagnosis is not always straightforward<sup>3</sup> and can be facilitated by using contrast echocardiography to illustrate the deep intertrabecular recesses.<sup>4</sup> Although IVNC is seen in both children and adults, familial recurrence appears to be more common in the latter population.<sup>5</sup> Isolated ventricular noncompaction is now considered a distinct cardiomyopathy.<sup>6</sup> One case series showed that 35% of patients died, half from sudden cardiac death, and 12% underwent heart transplantation.<sup>7</sup> Fewer than 50% of patients with left ventricular noncompaction have right ventricular involvement as well. A clinical distinction between biventricular and isolated left ventricular noncompaction is generally not made. Patients have heterogeneous presentations similar to those with reduced systolic function. Management options include appropriate heart failure treatment, arrhythmia control, and anticoagulation when embolic events occur.<sup>8</sup> Diagnosis can be delayed. The most common reasons for referral are heart failure, followed by uncertain echocardiographic findings, then palpitations.<sup>9</sup> Six-year follow-up of 17 patients in this case series<sup>9</sup> showed that 8 died and 2 underwent successful heart transplantation. There is a poor clinical prognosis, with severe left ventricular dysfunction, malignant arrhythmias, and embolic events. Recent studies have shown benefits with cardiac resynchronization therapy in patients with IVNC.<sup>10</sup> Ultimately, if standard drug treatment for heart failure does not succeed, transplantation appears to be the only other treatment option.

## CONCLUSION

We present a case report of biventricular noncompaction in a young man manifesting with an acute cerebrovascular event, atrial flutter,

From St Vincent Hospitals and Health Services, Indianapolis, Indiana; and The Care Group, LLC, Indianapolis, Indiana.

Reprint requests: Roshan K. Vatthyam, MD, MPH, 8333 Naab Road, Indianapolis, IN 46260 (E-mail: [rosh\\_04@hotmail.com](mailto:rosh_04@hotmail.com)).

0894-7317/\$36.00

Copyright 2009 by the American Society of Echocardiography.

doi:10.1016/j.echo.2009.06.010

1420.e1

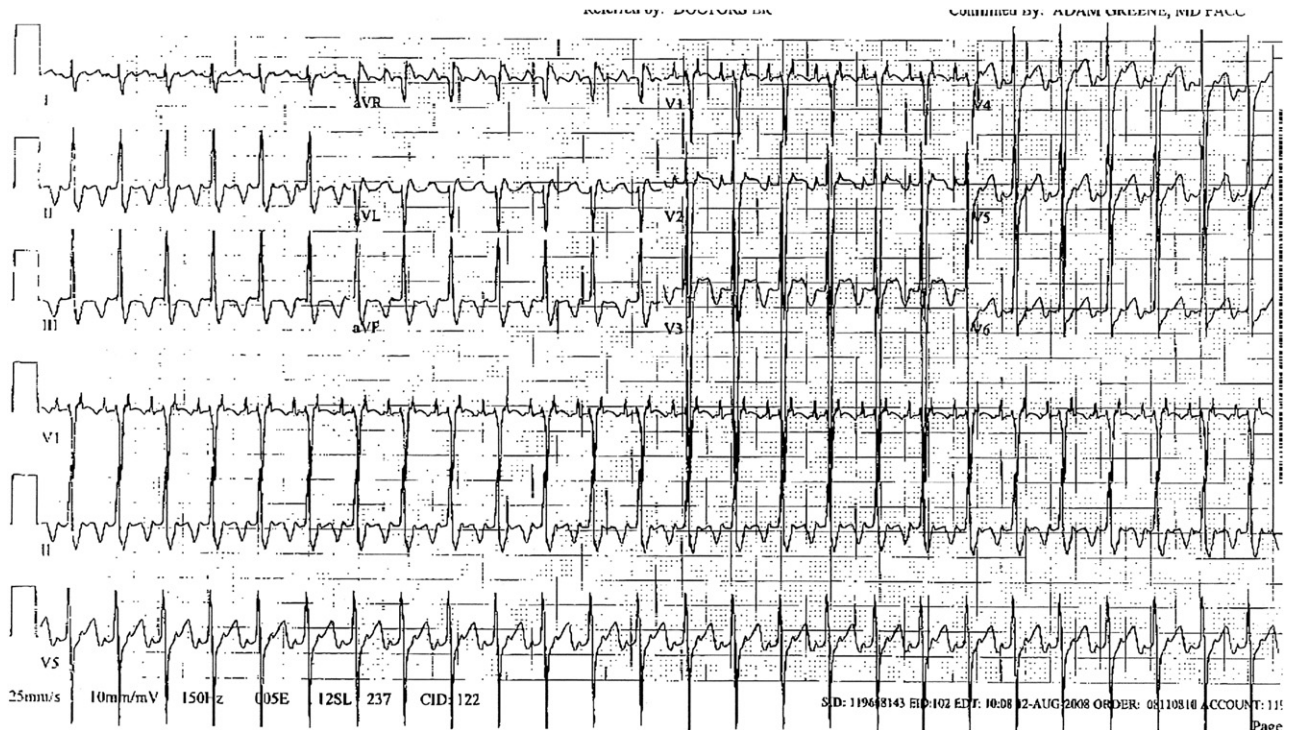


Figure 1 Initial electrocardiogram obtained in the emergency room exhibiting atrial flutter with 2:1 conduction.

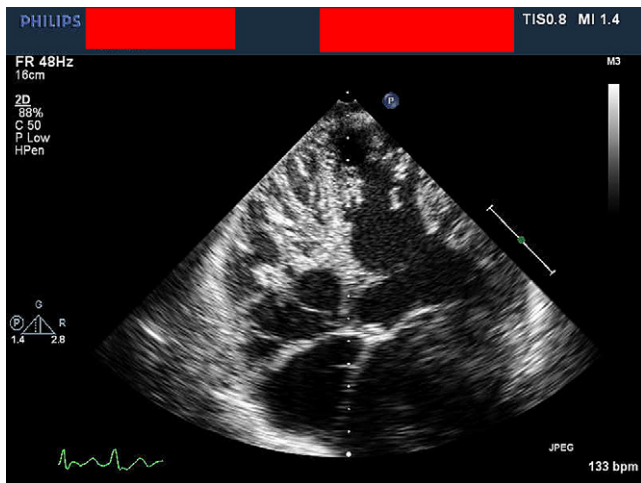


Figure 2 Two-dimensional echocardiogram illustrating biventricular noncompaction. Note spongelike trabeculation of both the right and left ventricles.

and severe dilated cardiomyopathy. This quickly progressed to cardiac arrest and brain death. Such a fulminant and tragic presentation of IVNC in a previously healthy and physically fit individual has not yet been described. The case brings to light many of the complications of IVNC, including atrial (and ventricular) arrhythmias, cardioembolic events, and profound ventricular dysfunction. Furthermore, we present objective clinical and anatomic pathologic findings that confirm the diagnoses. The identification of IVNC is often delayed, possibly because symptoms do not become evident until the disease is fairly advanced, as evidenced by the current case. Limited data exist regarding hereditary patterns of ventricular noncompaction.<sup>6</sup> Further study of the genetic basis of this disease may allow early

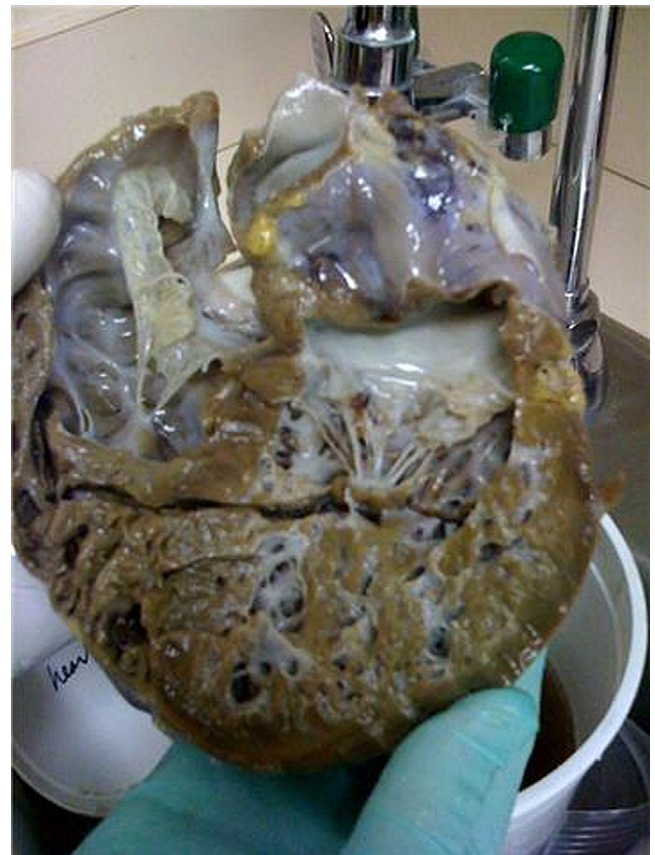

Figure 3 Postmortem examination of the heart. (Right) Left ventricle with noncompacted myocardial tissue and evidence of organized thrombi.

detection and appropriate treatment to prevent such catastrophic presentations.

## REFERENCES

---

1. Freedom RM, Yoo SJ, Perrin D. The morphological spectrum of ventricular noncompaction. *Cardiol Young* 2005;15:345-64.
2. Jenni R, Oechslin EN, Schneider J. Echocardiographic and pathoanatomical characteristics of isolated left ventricular non-compaction: a step towards classification as a distinct cardiomyopathy. *Heart* 2001;86:666-71.
3. Perez-David E, Garcia-Fernandez MA, Gómez-Anta I, Gomez de Diego JJ, García-Robles JA, Lafuente J. Isolated noncompaction of the ventricular myocardium: infrequent because of missed diagnosis? *J Am Soc Echocardiogr* 2007;20:439.e1-4.
4. Mulvagh SL, Rakowski H, Vannan MA, Abdelmoneim SS, Becher H, Bierig SM et al. American society of echocardiography consensus statement on the clinical applications of ultrasonic contrast agents in echocardiography. *J Am Soc Echocardiogr* 2008;21:1179-201.
5. Sasse-Klaasen S, Gerull B, Oechslin E. Isolated noncompaction of the left ventricular myocardium in the adult is an autosomal dominant disorder in the majority of patients. *Am J Med Genet* 2003;119A:162-7.
6. Maron BJ, Towbin JA, Thiene G, Antzelevitch C, Corrado D, Arnett, et al. Contemporary definitions and classification of the cardiomyopathies. *Circulation* 2006;113:1807-16.
7. Oechslin EN, Attenhofer-Jost C, Rojas JR, Kaufmann PA, Jenni R. Long-term follow-up of thirty-four adults with isolated left ventricular noncompaction: a distinct cardiomyopathy with poor prognosis. *J Am Coll Cardiol* 2000;36:493-500.
8. Jenni R, Oechslin EN, van der Loo B. Isolated ventricular non-compaction of the myocardium in adults. *Heart* 2007;93:11-5.
9. Ritter M, Oeschlin E, Sutsch G. Isolated noncompaction of the myocardium in adults. *Mayo Clin Proc* 1997;72:26-31.
10. Oginosawa Y, Nogami A, Soejima K, Aonuma K, Kubota S, Sato T, et al. Effect of cardiac resynchronization therapy in isolated ventricular noncompaction in adults: follow-up of four cases. *J Cardiovasc Electrophysiol* 2008;19:935-8.