

Isolated Posterior Cerebral Artery Infarction Caused by Carotid Artery Dissection

A 45-YEAR-OLD MAN with a history of smoking experienced sudden onset of loss of vision on his left side and transitory left hemiparesis. There was no history of recent trauma. Examination showed mild left hemiparesis and hypoesthesia, and left homonymous hemianopsia. Cranial computed tomographic imaging findings at admission were normal. Magnetic resonance imaging demonstrated a right occipital lobe infarction in the territory of the right posterior cerebral artery (PCA) (**Figure, A and B**). Transcranial Doppler sonography demonstrated collateral blood supply to the right hemisphere via the anterior communicating artery and no flow on the right carotid siphon or right PCA. Magnetic resonance angiographic imaging showed occlusion of both the right internal carotid artery (ICA) and the second portion of the right PCA (P2). There was also asymmetry of the proximal portion (P1) of the PCAs with a hypoplastic right P1, suggesting that the right occipital lobe was originally supplied by the right ICA (fetal pattern) (Figure, D). Digital subtraction angiography showed a cone-shaped complete occlusion of the right ICA, highly suggestive of dissection (Figure, C). Posterior cerebral artery infarct related to emboli-

zation from ICA dissection, associated with a persistent fetal configuration of the right PCA, was diagnosed. The patient was treated with anticoagulation therapy.

COMMENT

Dissection of the ICA is a frequent cause of stroke in young adults.¹ Posterior cerebral artery infarcts represent 5% to 10% of all strokes. Embolism from a cardiac or undetermined source accounts for up to half of the cases.² The PCA territory is supplied exclusively via the ICA in 11% of hemispheres, and in 46% of hemispheres the ICA might contribute via a patent posterior communicating artery.³ In these cases, ICA disease can cause occipital lobe infarction. However, isolated PCA infarct secondary to ICA dissection is very rare, probably because the middle cerebral artery arises as the larger terminal branch of the ICA, being the branch mainly affected by embolism. The diagnosis of PCA infarct due to ICA dissection should be considered, especially in young patients or in those with head or neck trauma and normal vertebro-basilar circulation studies.

Daniel de H. Christoph, MD
 Fabiana Souza-Lima, MD
 Mario A. da C. Saporta, MD
 Gabriel R. de Freitas, MD, PhD

Correspondence: Dr de Freitas, Rua Mário Pederneiras 55, 206-1, Rio de Janeiro, RJ, Brazil CEP 22261-020 (grdefreitas@gmail.com).

Author Contributions: *Study concept and design:* Christoph and de Freitas. *Acquisition of data:* Christoph and de Freitas. *Analysis and interpretation of data:* Christoph, Souza-Lima, Saporta, and de Freitas. *Drafting of the manuscript:* Christoph and de Freitas. *Critical revision of the manuscript for important intellectual content:* Christoph, Souza-Lima, Saporta, and de Freitas. *Administrative, technical, and material support:* Christoph and de Freitas. *Study supervision:* de Freitas. **Financial Disclosure:** None reported.

REFERENCES

1. Benninger DH, Georgiadis D, Kremer C, Studer A, Nedeltchev K, Baumgartner RW. Mechanism of ischemic infarct in spontaneous carotid dissection. *Stroke*. 2004;35(2):482-485.
2. Brandt T, Steinke W, Thie A, Pessin MS, Caplan LR. Posterior cerebral artery territory infarcts: clinical features, infarct topography, causes and outcome: multicenter results and a review of the literature. *Cerebrovasc Dis*. 2000;10:179-182.
3. Jongen JC, Franke CL, Soeterboek AA, Versteeg CW, Ramos LM, van Gijn J. Blood supply of the posterior cerebral artery by the carotid system on angiograms. *J Neurol*. 2002;249(4):455-460.

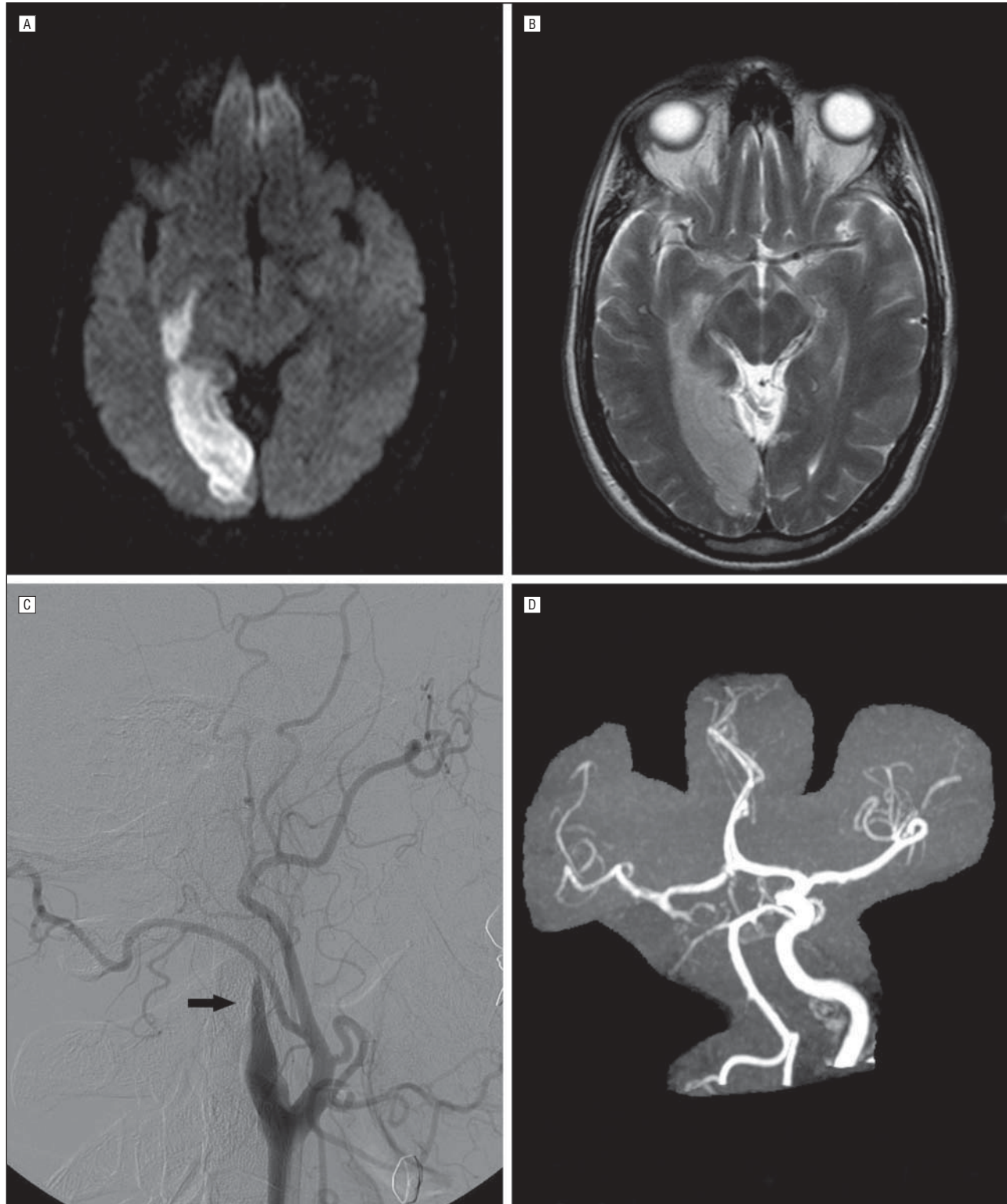


Figure. Magnetic resonance imaging (MRI), digital subtraction angiography, and magnetic resonance angiogram of a 45-year-old man with isolated posterior cerebral artery (PCA) infarction caused by carotid artery dissection. Right PCA infarct is demonstrated by MRI (diffusion-weighted imaging [A] and T2-weighted sequences [B]). Digital subtraction angiography shows a tapered occlusion of the right internal carotid artery (ICA) compatible with dissection (C, arrow). D, Magnetic resonance angiogram reveals an asymmetry of the proximal portion (P1) of the PCAs, with a hypoplastic right P1, suggesting that the right occipital lobe was originally supplied by the right ICA.