



## Dissociation apraxia secondary to right premotor stroke

Simona Luzzi<sup>a,\*</sup>, Massimo Piccirilli<sup>b</sup>, Martina Pesallaccia<sup>a</sup>, Katia Fabi<sup>a</sup>, Leandro Provinciali<sup>a</sup>

<sup>a</sup> Department of Neuroscience, Polytechnic University of Marche Medical School, Ancona, Italy

<sup>b</sup> Unit of Neuropsychological and Behavioural Research and Therapy, Santa Maria Hospital of Terni, University of Perugia, Italy

### ARTICLE INFO

#### Article history:

Received 24 March 2009

Received in revised form 26 June 2009

Accepted 11 August 2009

Available online 18 August 2009

#### Keywords:

Apraxia

Dissociation apraxia

Supplementary motor area (SMA)

Lateral premotor cortex (LPC)

Prefrontal cortex

### ABSTRACT

Apraxia is usually associated with damage to the dominant parietal cortex, but several other areas, including the left dorsolateral frontal cortex and subcortical structures, have also been implicated, suggesting that the praxis system is mediated by an anatomically distributed network. The right premotor frontal cortex is commonly assumed to play a secondary role in this system. We describe a patient who developed left upper limb apraxia after a right premotor ischaemic stroke. The neuropsychological examination ruled out impairment of other cognitive functions, including those subserved by the parietal–temporal cortex. Neither pyramidal signs nor interhemispheric transfer syndrome were detected, suggesting that the right primary motor cortex and corpus callosum were intact and that apraxia arose from a right prefrontal cortical lesion. An additional feature was the patient's inability to copy a gesture or posture demonstrated by the examiner (visual input) or to execute a verbal command (auditory input), even though he could copy the position in which the examiner placed his right arm while blindfolded (proprioceptive input). The disturbance was interpreted as “dissociation apraxia”. To our knowledge this type of dissociation has never been reported in a patient with focal brain damage. The case of this patient highlights the importance of the right premotor cortex in the praxis system, and lends support to the hypothesis of a modular and multimodal organization of brain functioning.

© 2009 Elsevier Ltd. All rights reserved.

### 1. Introduction

The traditional model of apraxia, derived from Liepmann's studies of focal brain damage (Liepmann, 1900), is based on the detailed description of a single case, an “imperial counsellor” with syphilis, who showed a profound impairment in the ability to perform hand movements and “bizarre and distorted movements, which he made during the course of the examination” (see Goldenberg, 2003 for a detailed review). The traditional classification of apraxia is mainly based on Liepmann's interpretation of qualitatively different types of errors in the performance of motor acts, and includes ideational, ideomotor (corresponding to Liepmann's “ideo-kinetic” apraxia), and melokinetic (“limb-kinetic”) apraxia (Goldenberg, 2003; Goldenberg, 2008; Heilman & Watson, 2008). The theoretical bases of this model have been challenged as new interpretations of deficits and neural organization theories have been proposed (Buxbaum, 2001; Goldenberg, 2008; Heilman & Watson, 2008; Leiguarda & Marsden, 2000). Another rare type, “dissociation apraxia” (Heilman & Watson, 2008), was described

by Heilman (1973) in three patients with left hemisphere lesions. These patients were unable to pantomime transitive movements to verbal command, but correctly performed pantomimes to visual input (while seeing the tools); they could also imitate and use objects normally. In 1982 the reverse pattern was described by De Renzi, Faglioni, and Sorgato (1982) in patients who were able to pantomime in response to verbal commands, but not to seeing tools. The precise localization of the lesions resulting in dissociation apraxia is still unclear. According to Heilman and Watson's model (2008) “verbal intrahemispheric dissociation apraxia” is due to a disconnection of the “lexical-semantic network” from “action semantics” and “movement representations”, while “visual intrahemispheric dissociation apraxia” is consequent to a disconnection between the “object recognition units” and “action semantics” or “movement representations”. All such structures are held to lie in the left hemisphere, specifically in the parieto-temporo-occipital cortex (Heilman & Watson, 2008).

The bulk of the complex circuitry involved in the other forms of the disorder is also assumed to lie in the left hemisphere, specifically the parietal–frontal cortex, with a secondary role for the right frontal cortex (Heilman & Watson, 2008; Leiguarda & Marsden, 2000). However, studies of patients with focal brain damage indicating a role in apraxia generation also for the right hemisphere merely classify patients into those with left or right brain damage, but provide no exact data on lesion localization and extent

\* Corresponding author at: Simona Luzzi Clinica Neurologica, Dipartimento di Neuroscienze, Università Politecnica delle Marche – Ospedali Riuniti di Ancona, Via Conca 1, Torrette di Ancona, Italy. Tel.: +39 071 596 4637; fax: +39 071 887 262.

E-mail address: [s.luzzi@univpm.it](mailto:s.luzzi@univpm.it) (S. Luzzi).

(Della Sala, Faglioni, Motto, & Spinnler, 2006; De Renzi, Motti, & Nichelli, 1980; Goldenberg, 1996; Goldenberg & Strauss, 2002; Roy et al., 2000). In some investigations performed in stroke patients, the injury is described as involving the right or left middle cerebral artery territory (Goldenberg, 1996; Goldenberg & Strauss, 2002), suggesting lesions of variable size that may affect frontal, parietal and temporal areas to different extents. Hartmann, Goldenberg, Daumüller, and Hermsdrfer (2005), who calculated lesion size in a patient group with left brain lesions and another with right brain damage, found no significant correlations with neuropsychological test results. Brodmann areas 6, 21, 22, 37, 39, 40, and 44 were affected in five or more patients per group. A significantly different lesion incidence between the groups was found only for area 46.

The scarce information on the contribution of right brain areas to apraxia generation reinforces the hypothesis that the praxis circuits lie in the left hemisphere. However, the assumption has recently been criticized and perplexities have been voiced about the central role of left parietal lesions (Goldenberg, 2008). There is indeed evidence that other areas, such as subcortical structures (Hanna-Pladdy, Heilman, & Foundas, 2001), are implicated in apraxia. On the whole, the data suggest that the praxis system is mediated by an anatomically distributed network (De Renzi & Faglioni, 1996; Hanna-Pladdy et al., 2001; Heilman & Watson, 2008; Leiguarda & Marsden, 2000). This model is consistent with an active role of the right hemisphere in apraxia.

We describe a patient with left upper limb dissociation apraxia secondary to a right prefrontal ischaemic stroke, who was unable to imitate or perform gestures on verbal command, but could imitate the posture in which the examiner placed his right arm while blindfolded. To our knowledge this type of dissociation has never been reported in a patient with focal brain damage.

## 2. Case report

### 2.1. Clinical history, neurological examination and neuroimaging

Lucio, a 72-year-old right-handed retired public employee with 8 years education, came to our attention for difficulties in controlling his left arm that had arisen 8 years earlier, after a right frontal stroke in the territory of the right middle cerebral artery. According to his clinical records his behaviour changed dramatically over a couple of days from a quiet, peaceful personality to increasingly abusive, apathetic and occasionally fatuous behaviour. He became hyperphagic and what his family described as “childish, egoist and indolent”. Confusional state, delusions, topographical disorientation, episodic memory problems, dysperceptions or hallucinations were not reported. About a week later, he experienced a sensory deficit of the left arm and hemiface that lasted a few minutes and recurred a couple of times a day for a few days. He was seen to have high blood pressure and was prescribed an antihypertensive and acetylsalicylic acid. About 1 week later he was admitted to hospital with left arm myoclonic jerking and was again found to have high blood pressure. The following day, Lucio developed a loss of strength in the left hand and lower left hemiface.

The neurological examination performed at the time revealed central paresis of the VII cranial nerve and a slight distal strength impairment in the left arm (hand and fingers). He appeared fatuous and exhibited verbal perseverations, disinhibition, loss of insight, poor attention and hyperphagia. His MR scans showed a right frontal ischaemic lesion. Neuroangiography with selective catheterization demonstrated right internal carotid artery occlusion immediately after the ophthalmic artery, hypoplasia of tracts A1–A2 of the right anterior cerebral artery between the supraoptic and subcallosal portions, including the communicants anterior artery, as well as vertebro-basilar system dysmorphism consisting

**Table 1**  
Psychosensory integration.

Test (maximum score)	Lucio's score	Control cut-off
Stereognosis (10) [right hand]	10	<9
Stereognosis (10) [left hand]	10	<9
Double tactile stimulation (10)	10	<9
Double visual stimulation (10)	10	<9
Graphaesthesia (5) [right hand]	5	<4
Graphaesthesia (5) [left hand]	5	<4

of severe left vertebral artery hypoplasia and absence of the left posterior cerebral artery.

We examined Lucio 8 years after the stroke. Lucio is a nickname he chose in homage to his favourite singer, Lucio Battisti, which we felt would safeguard his identity better than his initials. Lucio gave his informed consent to be tested with an experimental neuropsychological battery and gave his written consent to the publication of the data collected.

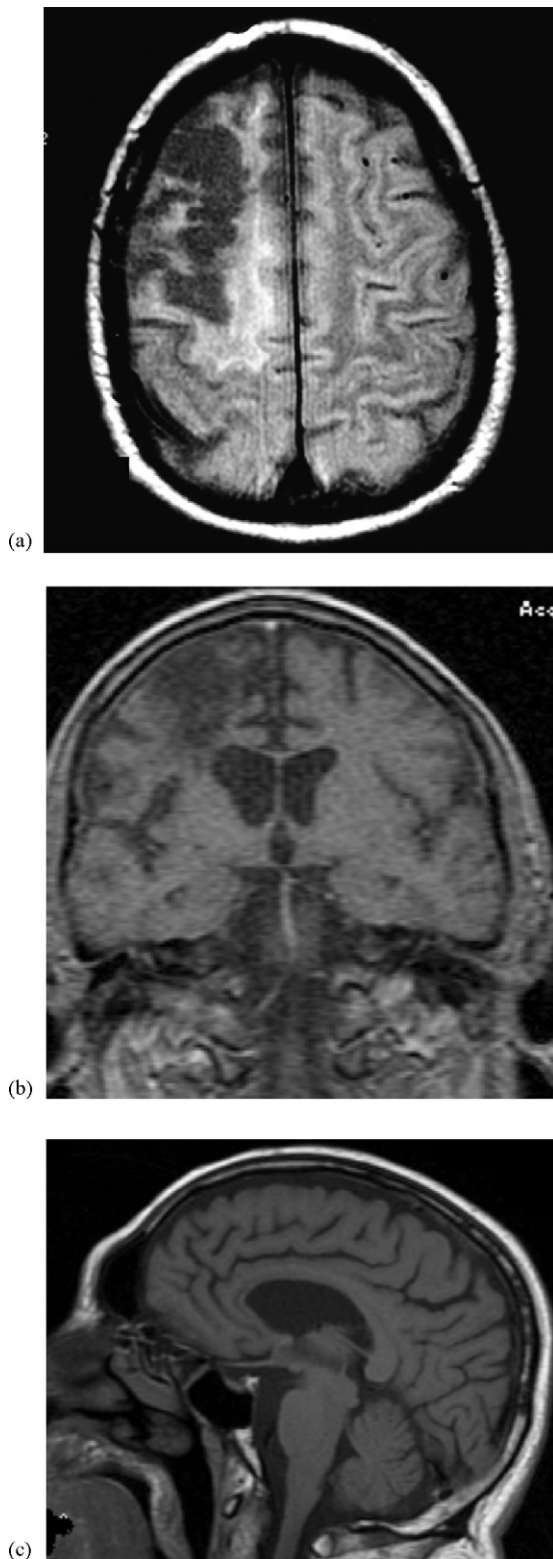Lucio was referred to us by his general practitioner for neurological evaluation. He looked healthy and affable, and none of the behavioural changes described in his records emerged in the course of the clinical interview. During the first interview he said he had become used to his “crazy” left arm, which sometimes executed actions properly and sometimes refused, particularly when he “willed” it to do something. He reported that when he was asked, or wanted to do an action with his left arm, he sometimes would be unable to coordinate his fingers, arm and shoulder, even though he had completely recovered his strength after the stroke, and found it odd that the more he concentrated the worse he did. A detailed interview excluded anarchic/alien limb and pathological movements (e.g. synkinesia). Lucio said that his hand never did any movements unless it was ordered to, and that it never moved around or assumed a fixed posture. When the arm was at rest the hand never moved spontaneously. Arm movements were not influenced by previous actions and the arm never repeated spontaneously a movement performed previously. Lucio denied any interference either from external objects (the hand never grasped objects unless requested) or from other body parts. He reported no episodes in keeping with intermanual conflict; his left hand did not interfere with the right and did not imitate the movements of that hand.

The general neurological examination was normal; neither pyramidal, nor sensory signs were detected, but Lucio had problems imitating left arm gestures shown by the examiner. Neither grasping nor groping was observed. No alien limb phenomenon was noted either in the clinical interview or during the neurological examination. A set of tasks (Table 1) was administered to investigate psychosensory integration. Lucio's performances were compared with those of 10 healthy volunteers (7 males and 3 females) with similar demographic characteristics, a mean age of 72.1 years (SD = 1.7; range 70–75), and mean education of 8 years (SD = 2.9; range 5–13).

Lucio's MR scans showed a right frontal cortico-subcortical malacic lesion (Fig. 1).

#### 2.1.1. Stereognosis

We used a set of 10 common objects small enough to be easily manipulated with one hand (e.g. ring, key, pen cap). Lucio was blindfolded and the objects were placed in the palm of his hand one at a time. He was asked to explore each item tactually and to name it. If he was unable to name it, he was to provide its description in terms of size, consistency (soft, hard), shape, and material (e.g. iron, plastic, wood). The same object set was presented in random order to each hand in two different sessions, to avoid interference from memory.



**Fig. 1.** MR scan: right frontal lesion extending to the lateral premotor cortex.

*Result:* Lucio's performance was quick and faultless; all objects were correctly named.

#### 2.1.2. Double tactile stimulation

Lucio, blindfolded, was informed that the examiner would touch with a finger the back of his right or left hand, or of both hands simultaneously. While explaining the procedure the examiner

touched Lucio's right or left hand or both as an example. After a six-item training set, a set of 30 stimuli (10 to the left hand, 10 to the right hand and 10 bilateral stimuli) was applied in a random order. Lucio's performance on the 10 bilateral stimuli and those of the 10 controls are shown in [Table 1](#).

*Result:* Lucio correctly identified all the bilateral stimuli.

#### 2.1.3. Double visual stimulation

To explore Lucio's ability to see a moving stimulus in the peripheral visual field the examiner sat in front of him, with his arms in a fixed posture so that his right hand would be seen in the left part of Lucio's visual field and vice versa. Lucio was told that the examiner would move the fingers of one hand, or of both hands simultaneously. He was asked to fix his gaze on the examiner's nose and to report which hand the examiner was moving. The test was started after a six-item training.

Again, 30 stimuli (20 unilateral and 10 bilateral) were applied, half (10+5) to the upper portion and half to the lower portion of the visual field, to explore all quadrants. Lucio's performance on the 10 bilateral stimuli and those of the 10 controls are reported in [Table 1](#).

*Result:* Lucio correctly identified all bilateral stimuli.

#### 2.1.4. Graphaesthesia

Lucio was blindfolded. The examiner, using a blunt-pointed object, drew a simple shape on the palm of his hand (e.g. a cross, a single digit number, a circle) and asked him to name it. The same set of five stimuli was applied in a random order to each hand in two separate sessions, to avoid interference.

*Result:* All stimuli applied to either hand were correctly identified.

*Comment:* There was no evidence of either primary motor or sensory disturbances; psychosensory integration was intact.

### 2.2. General neuropsychological evaluation

A broad neuropsychological battery was applied to examine cognitive functions. General abilities were explored with the Mini-Mental State Examination (MMSE) Test ([Folstein, Folstein, & McHugh, 1975](#)), and Raven's Coloured Progressive Matrices ([Raven, 1965](#)). Language comprehension was tested with the Token Test ([De Renzi & Vignolo, 1962](#)) and language production with category verbal fluency ([Spinnler & Tognoni, 1987](#)) and letter fluency ([Caltagirone, Gainotti, Masullo, & Miceli, 1979](#)) tests. Calculation skills were explored using subtests from Miceli and Capasso's test ([Miceli & Capasso, 1991](#)). Visuospatial and visuospatial abilities were investigated with the Visual Object and Spatial Perception Test (VOSP) ([Warrington & James, 1991](#)), Benton's Line Orientation ([Benton, Hamsher, Varney, & Spreen, 1983](#)) and the Behavioural Inattention Test ([Wilson, Cockburn, & Halligan, 1987](#)). Memory was explored in all its components: verbal short-term memory was investigated with the Bisyllabic Word Span ([Spinnler & Tognoni, 1987](#)), spatial short-term memory with Corsi Blocks ([Spinnler & Tognoni, 1987](#)), verbal long-term memory with the Rey Auditory Verbal Learning Test ([Caltagirone et al., 1979](#)), and spatial long-term memory with the Rey–Osterrieth Figure B ([Rey, 1959](#)). Executive functions were explored with Weigl's Sorting Test and the letter fluency test (FAS) ([Caltagirone et al., 1979](#)). Tasks and performances are reported in [Table 2](#). Normative values for the retrieval of the Rey–Osterrieth Complex Figure, test B, were obtained from healthy volunteers with the same demographic characteristics as Lucio.

*Results:* Lucio performed very well on all tasks. He was perfectly oriented in time and space. His memory worked well and he was able to retain information over time. Logical abilities and abstract thinking were well preserved. There was no evidence of

**Table 2**  
Background neuropsychology.

Test (maximum score)	Score	Control score (SD) or cut-off
<i>General abilities</i>		
MMSE (30)	30	<24
Raven's Coloured Progressive Matrices (36)	22	25.03 (4.62)
<i>Language</i>		
Token Test (36)	35	32.27 (2.93)
Category Verbal Fluency	14.25	13.86 (4.24)
<i>Calculation</i>		
Written Calculation (60)	60	<55
<i>Visuoperceptual and visuospatial abilities</i>		
VOSP		
Shape Detection Test	20	19.9 (0.3)
Incomplete Letters	19	18.8 (1.4)
Silhouettes	17	22.2 (1.0)
Real Object Decision Task	18	17.7 (1.9)
Progressive Silhouettes	10	10.8 (2.5)
Dot Counting	10	9.9 (0.2)
Number Location	10	9.4 (1.1)
Position Discrimination	20	19.6 (0.9)
Cube Analysis	10	9.2 (1.2)
Benton's Line Orientation (30)	26	26.2 (3.6)
<i>BIT (Behavioural Inattention Test)</i>		
A. Conventional Subtest Scores (146)	140	<129
B. Behavioural Subtest Scores (81)	78	<67
<i>Memory</i>		
Bisyllabic Word Span	4	4.12 (0.79)
Corsi Blocks	4	4.35 (0.84)
Rey AVLT Total Effect (75)	32	34.31 (6.71)
Rey AVLT Long-Term (15)	7	6.57 (2.29)
Rey Figure B Long-Term Retrieval	29	18.8 (5.49)
<i>Executive functions</i>		
FAS	25	27.37 (9.93)
Weigl's Sorting Test	11	10.14 (3.05)

language problems. His visuoperceptual and visuospatial abilities were spared. He showed none of the features of dysexecutive syndrome.

*Comment:* Because Lucio was referred to us several years after his stroke for symptoms consistent with apraxia, we first aimed to exclude incipient dementia, particularly Alzheimer's disease (McKhann et al., 1984), and corticobasal degeneration (Litvan et al., 2003). Several pieces of information argued against this hypothesis: (i) Lucio reported that he had had these symptoms ever since his stroke; (ii) nothing in what he or his family said suggested dementia; and (iii) Lucio's cognitive abilities as he supplied clinical history data appeared to be unimpaired. However, an objective measure of his general cognitive status and detailed information on the principal neuropsychological domains were needed. As expected, Lucio performed well on all tasks; in particular, there was no trace of the dysexecutive syndrome of 8 years previously, which was likely due to a temporary dysfunction of the frontal circuits.

**Table 3**  
Praxis system investigation.

Test (maximum score)	Lucio's score	Control score (SD) or cut-off
Gesture Recognition Test (20)	20	>17
Object Use Pantomime (120) [right hand]	120	<101
Object Use Pantomime (120) [left hand]	86	<101
Movement Imitation Test (72) [right upper limb]	70	<53
Movement Imitation Test (72) [left upper limb]	37	<53
Movement imitation Test (30) [left lower limb]	90	<81
Movement imitation Test (30) [right lower limb]	90	<81
Bucco-linguo-facial Praxis (24)	20	19.79 (0.58)
Constructional Praxis (31) [right hand]	30	28.8 (1.48)
Constructional Praxis (31) [left hand]	29	–

### 2.3. Praxis investigation

We applied a series of tasks exploring gesture comprehension and production.

Lucio's scores and the normative values are reported in Table 3, except those of the Multiple Object Test (see below). Normative values for the Gesture Recognition Test, Movement Imitation Test (lower limbs), Constructional Praxis and the tests reported in Table 3 (discussed below) were obtained from healthy volunteers with the same demographic characteristics as Lucio.

#### 2.3.1. Gesture Recognition Test

A series of 20 common objects was used. The examiner pantomimed the use of each item. A sheet of paper placed in front of the patient contained the pictures of four objects: the target and three distractors, one of which was semantically related to the target, another shared a similar type of action with it but had a different function, and the last was an unrelated item. The patient was asked to match the gesture pantomimed by the examiner with the corresponding object.

*Result:* Lucio's score was in the normal range. He performed the test quickly and never hesitated in matching gestures to objects.

#### 2.3.2. Object Use Pantomime

We applied the test devised by De Renzi and Lucchelli (1988), where the patient is asked to pantomime the use of 20 common objects and is awarded 3 points for a correct pantomime; 2 points for an imprecise performance clearly resembling the correct one; 1 point for a weak resemblance to the appropriate gestures; and 0 points for an unrecognizable (wrong or incomplete) pantomime.

*Result:* Lucio made no errors consistent with the classic concept of ideational apraxia (in particular, no omission, perplexity, mislocation, or misuse errors). However, his left arm movements were clumsy and demonstrated spatio-temporal alterations.

#### 2.3.3. Multiple Object Test

This test was as described by De Renzi and Lucchelli (1988). It is based on five actions that require a movement sequence involving more than one object placed on a table in front of the subject. (1) Lighting a candle: candle, candlestick and matchbox. (2) Opening and closing a padlock: key and padlock. (3) Drinking a glass of water: empty glass, bottle-opener and closed bottle of water. (4) Preparing a letter for posting: sheet of paper, envelope and sheet of stamps. (5) Making a cup of espresso coffee: coffee pot, canister of ground coffee and pitcher of water. A qualitative score is applied according to the errors made by the subject.

*Result:* All sequences were correctly executed, although left arm movements were clumsy. No other qualitative errors, e.g. perplexity, omission, mislocation, misuse or sequence errors, were noted.

#### 2.3.4. Movement Imitation Test

Lucio was asked to imitate a set of arm or leg gestures performed by the examiner. For the arms we used a 24-item battery of 12 sym-

**Table 4**  
Interhemispheric transfer of information.

Test (maximum score)	Lucio's score	Control cut-off
Tactile stimulus localization (right hemibody)	10	<9
Tactile stimulus localization (left hemibody)	10	<9
Copying a posture/gesture applied by the examiner to Lucio's contralateral arm [right → left]	20	<19
Copying a posture/gesture applied by the examiner to Lucio's contralateral arm [left → right]	20	<19
Drawing of objects explored with the contralateral hand (10) [right → left]	10	<9
Drawing of objects explored with the contralateral hand (10) [left → right]	10	<9
Finger localization test: right hand (uncrossed stimuli)	100	<100
Finger localization test: right hand (crossed stimuli)	97	<95
Finger localization test: left hand (uncrossed stimuli)	100	<97
Finger localization test: left hand (crossed stimuli)	98	<94

bolic and 12 non-symbolic gestures: 12 gestures involved single finger movements and 12 involved both hand and arm movements (De Renzi & Faglioni, 1996). A score of 3 was credited for a flawless performance; if the movement was partially or totally incorrect the item was presented again (2 points), and then a third time if the patient failed again (1 point); a score of 0 was assigned for three fails. For the lower limb we devised a series of movements and postures. Score attribution was as described above for the upper limb; the maximum score was 90.

**Result:** While right arm and both leg performances were correct, left arm movements were clumsy and awkward, despite a preserved general configuration of gestures. Motor conduite d'approche (where, in analogy to the linguistic conduite d'approche, the patient performs voluntarily a series of motor attempts, progressively correcting his incorrect posture to achieve the target posture), irregular amplitude and timing and sequencing errors were noted in left hand, arm and forearm movements.

### 2.3.5. Bucco-Linguo-Facial Praxis

We used De Renzi and Faglioni's battery (1996) of actions involving different muscle groups of the face, larynx, and pharynx. Two points were awarded for a faultless performance; the item was presented again if the movement was partially or totally incorrect; 1 point was given if the patient correctly imitated the movement, and a 0 score was awarded if the movement was not correctly executed after two attempts (Spinnler & Tognoni, 1987).

**Result:** Lucio made no errors.

### 2.3.6. Constructional Praxis

Lucio was asked to copy the Rey–Osterrieth Complex Figure, Test B, with both hands. The figure is composed of four partially overlapping geometrical shapes (a circle, a square, a rectangle, and a triangle). A total of seven details are found in discrete positions in the figures (e.g. two little black dots in the circle, a cross in the triangle, a little arch containing four parallel lines in the middle part of the bottom long side of the rectangle, etc.). The total score of 31 derives from a multidimensional score that takes into consideration: (1) the number of elements correctly reproduced; (2) the subject's ability to reproduce the correct size of the four main figures; (3) the ability to correctly superimpose the four figures on each other; (4) the ability to locate the details in their exact position.

**Result:** Lucio successfully copied the figure with both hands. Although the left hand drawing was less accurate, all the details were correctly located. Motor perseverations were not noted in the graphic reproduction made with the left hand. The spatial relationships within the geometrical figures were preserved, as were the sizes of both figures and details.

**Comment:** Lucio's conceptual knowledge of the gesture was preserved. In contrast, his gesture production was impaired. Apraxia selectively involved the left arm and all of its segments, i.e. hand, fingers, arm and forearm. The other limbs and the bucco-linguo-

facial area were spared. Qualitative analysis of left arm errors indicated clumsy and awkward movements, irregular amplitude, and timing and sequencing errors with motor conduite d'approche.

Automatic-voluntary dissociation was observed on two occasions. When asked which gesture he would naturally do at a bad-mannered driver overtaking where this was prohibited, Lucio promptly and spontaneously made the "horns" sign (second and last finger extended, the others flexed), a non-verbal Italian insult expressing disappointment or anger. On another occasion, during testing for ideational apraxia, he was given a soldier's cap and asked to wear it. After placing it on his head with the left arm he saluted as a joke, using that arm. On both occasions his movements were fluid and rapid, unlike those he made in the tests where he was asked to imitate the examiner's gestures.

Alien limb phenomenon was not noted during the neuropsychological evaluation. The left arm never moved involuntarily or randomly when at rest (e.g. floating in space), or towards an object or body part, and never assumed a fixed posture (e.g. levitation).

Intermanual conflict, synkinesis, or limb substitution were never observed, nor was interference from previous actions or from external stimuli.

## 2.4. Exploration of interhemispheric transfer

Because left arm apraxia is generally assumed to be an interhemispheric transfer disconnection syndrome (Heilman & Watson, 2008), we tested interhemispheric transfer of information.

Several of the tasks used to explore psychosensory integration provide relevant data. For example, stereognosis tasks highlight cortical sensory impairment and enable evaluation of intrahemispheric (the object is explored with the right hand) as well as interhemispheric transfer (the object is explored with the left hand). The same applies to graphaesthesia. Lucio's flawless performance on all these tasks indicated good interhemispheric transfer of verbal and sensory-motor information.

Additional tasks were administered to probe further the interhemispheric transfer of information. The results are shown in Table 4.

### 2.4.1. Tactile stimulus localization

Lucio was blindfolded. He was told that the examiner would touch his right or left hemibody. Lucio would then be required to tap the point touched by the examiner, using the contralateral hand (e.g. the left hand if the stimulus had been applied to his right hemibody). A total of 20 stimuli were applied, 10 to the right and 10 to the left hemibody, divided as follows: two stimuli to the face (upper and lower); three stimuli to the upper limb (arm, forearm, and hand); two stimuli to the trunk (upper and lower), and three stimuli to the leg (thigh, leg, and foot).

**Result:** Lucio correctly touched all points using his contralateral hand.

#### 2.4.2. Copying a posture/gesture applied by the examiner to the contralateral arm

Lucio was blindfolded. The task included 10 postures and 10 gestures that involved to the same extent finger, hand, elbow, and shoulder joints. The examiner placed Lucio's arm in each position (e.g. fingers flexed, wrist extended, elbow flexed), or guided his arm in performing the movements (elbow flexion-extension), then asked Lucio to copy them with his contralateral limb. The same 20 items were applied to each arm in two separate sessions.

*Result:* Lucio was able to imitate all postures and gestures with both arms, without left-right differences in motor performance.

#### 2.4.3. Drawing objects explored out of sight with the contralateral hand

Lucio was blindfolded. He was asked to explore tactually 10 small, common objects that the examiner placed in his palm one at a time. The blindfold was removed after each object. Lucio was then asked to draw the objects explored with his right hand using the left hand, and vice versa. A separate session was held for each hand.

*Result:* Lucio could draw all the objects explored with either hand. The drawings of a key explored out of sight with the contralateral hand are shown in Fig. 2. Being right-handed, he was unused to drawing with the left hand, so the shape drawn with the left hand is less precise. The same difficulties were experienced by the controls. Even though the left hand drawings were overall less precise, all objects were clearly recognizable. No motor perseverations were noted in the graphic reproductions made with the left hand.

#### 2.4.4. Finger localization test

In this test (Piccirilli, Finali, & Sciarma, 1989) Lucio, blindfolded, was asked to place his forearms on a table with the palms up. The experimenter touched the tip of one of the four fingers with the point of a pencil, asking him to touch the same fingertip with the ipsilateral thumb (same-hand or uncrossed-hand condition) or the corresponding finger on the other hand with the thumb of that hand (other-hand or crossed-hand condition). The test was first demonstrated in full sight of the patient. In all, 96 stimuli were applied in sets of 24 for each condition, all fingers being stimulated the same number of times.

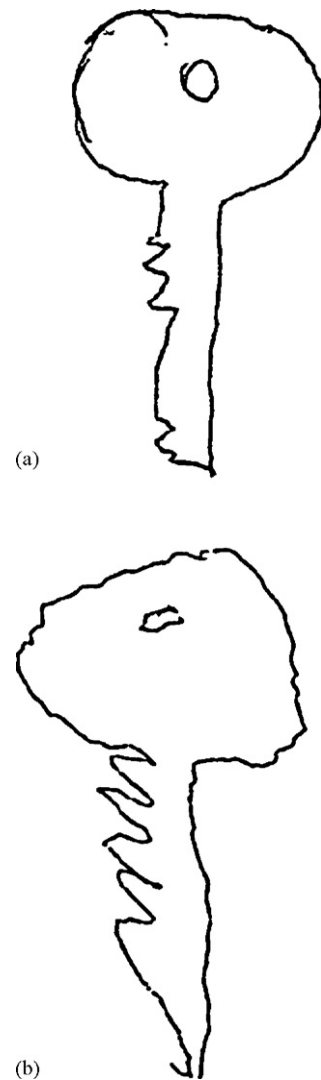
The experimental design entailed four conditions: (1) right hand receiving the stimulus and responding; (2) left hand receiving the stimulus and responding; (3) right hand receiving the stimulus and left hand responding; and (4) left hand receiving the stimulus and right hand responding.

*Result:* Lucio performed the task promptly and flawlessly.

*Comment:* Lucio's good performance on all tasks reflected a normally functioning corpus callosum and reinforced the conclusion suggested by his excellent performance on the psychosensory integration tasks.

#### 2.5. Exploration of the influence of stimulus modality on gesture performance

Examination of Lucio's performance on the tests involving left arm movements showed that even though he could not imitate gestures shown by the examiner, he could however carry out all motor tasks involving interhemispheric transfer of information, apparently without problems. Because neither sensory disturbances nor interhemispheric transfer syndrome were detected, we tested the hypothesis of a dissociation of motor performances as a function of stimulus modality, i.e. visual input in the gesture imitation test and proprioceptive input in copying a posture/action applied by the examiner to Lucio's contralateral limb. We also needed to exclude that Lucio's ability to copy passive movements of the right arm



**Fig. 2.** Object drawn after out of sight exploration with the contralateral hand. (A) Key explored with the left hand and drawn with the right hand and (B) key explored with the right hand and drawn with the left hand.

using his left arm and his inability to imitate visually presented movements depended on the different gestures involved in the two tests. If this were demonstrated, then the different performances could stem from different demands on motor difficulty.

It should be noted that the three conditions listed above (i.e. imitating a visually presented gesture, carrying out a gesture to auditory command, and transferring a posture of the right arm to the left arm) differ in terms of the mechanism and process involved in the input modality. As described in detail in Heilman's model (Heilman & Watson, 2008), the verbal modality involves the lexical-semantic network and the connections with the module where the movement representations are stored. The visual modality involves the objects recognition unit and the corresponding connections. A lesion in the regions described above determines verbal and visual dissociation apraxia.

The proprioceptive modality is not envisaged in Heilman and Watson's model (which the authors themselves do not consider definitive), but it likely involves the primary sensory cortex areas where proprioceptive stimuli are thought to be processed (Williams & Warwick, 1980), and the probable connections between these areas and the movement representation unit.

By contrast, the tasks proposed all require the same motor performance of the patient. Consequently, if the different perfor-

**Table 5**

Lucio's left upper limb performance in the pantomimes involving different input types.

Test (maximum score)	Lucio's score	Control cut-off
Pantomime to proprioceptive input	20	<19
Pantomime to visual input	12	<19
Pantomime to verbal input	13	<19

mances we noted in the different tasks depended on their different motor complexity, then the three performances should be comparable.

Lucio was therefore tested in imitation of meaningless gestures in three different conditions: to verbal, visual and proprioceptive input. In each condition he was required to perform an identical set of 10 gestures (5 postures and 5 actions). The list of 10 gestures (Luzzi et al., 2004) is reported in Appendix A.

Two points were awarded for a correct performance; 1 point for an incorrect performance resembling the appropriate gesture, and 0 points for an unrecognizable imitation. The maximum score was 20.

Lucio's performance and the scores of control subjects are shown in Table 5.

#### 2.5.1. Imitation of meaningless gestures to verbal input

The examiner asked Lucio to perform specific gestures and movements. Because these were non-symbolic, Lucio was first instructed on what movement he was expected to make in response to each command (e.g. flexion). To ensure that performance was not a consequence of verbal misunderstanding, a training task was run with Lucio executing the movements with his right arm.

*Result:* Lucio's performance was consistently poor compared with control scores, with problems in most movements and postures. Again, movements were awkward, with irregular amplitude and timing errors, and motor *conduite d'approche*.

#### 2.5.2. Imitation of meaningless gestures to visual input

Lucio was asked to imitate, using his left arm, a series of gestures made by the examiner with the left arm. The test was administered with the examiner standing in front of Lucio and then standing at his side. The two tests aimed at excluding impaired mental rotation of visual images.

*Result:* Lucio's motor performance was poor and similar in quality to that of the previous task.

#### 2.5.3. Imitation of meaningless gestures to proprioceptive input

Lucio was blindfolded. The examiner placed Lucio's right hand in a specific posture and asked him to imitate it with the left hand. This is a well-known method to explore proprioceptive functioning and can also be considered as a test of the interhemispheric transfer of kinaesthetic-motor information, because the sensory input from a limb needs to be transformed into movement and the order to be transferred to the muscles of the contralateral limb.

As a control, the reverse condition was tested, by placing Lucio's left hand in a specific posture and then asking him to imitate it with the right hand. He performed this task flawlessly.

*Result:* Lucio's performance was good in either condition; all movements were qualitatively fluid and precise.

*Comment:* A dissociation in Lucio's gesture performance was noted in the different conditions. Remarkably, Lucio responded correctly to a proprioceptive input, whereas he showed an impaired response with the features of apraxia in executing visual or verbal inputs.

### 2.6. Neurological and neuropsychological follow-up

We had the opportunity to examine Lucio again after 13 months. He still behaved as the nice person we remembered. His family reported no new cognitive problems. His neurological evaluation was still normal. The neuropsychological profile was unchanged. He showed no sign of cognitive decline (MMSE: 30/30) and his gesture performance was similar to his previous qualitative profile.

### 3. Discussion

We report on a patient with selective left arm apraxia whose condition fitted none of the traditional types of apraxia. Its most remarkable feature was that whereas Lucio performed poorly when asked to copy a gesture made by the examiner (visual input), or to execute a command (auditory input), he successfully imitated with his left arm the position in which the examiner had placed his right arm while he was blindfolded (proprioceptive input), reflecting a dissociation of motor performance based on input modality. To our knowledge, this type of dissociation has never been reported. Lucio successfully performed conceptual tasks and displayed a well-preserved conceptual knowledge of gestures and the use of objects, enabling both ideational and conceptual apraxia to be ruled out (Heilman & Watson, 2008); melokinetic apraxia was also excluded on the basis of clinical and neuropsychological observations. On the other hand Lucio's left arm motor disturbances were not consistent with other disorders, such as alien/anarchic hand. Ideomotor apraxia was ruled out, because it is usually a bilateral disorder (Goldenberg, 2008), and isolated left arm apraxia is a typical disconnection syndrome held to be due to callosal dysfunction (Heilman & Watson, 2008); however in Lucio's case interhemispheric transfer of information appeared to be wholly preserved. Lucio's performance was thus very puzzling.

Likely observed dissociation between proprioceptive modality preservation and visual and verbal impairment should be due to the focal right premotor damage but traditional models of apraxia envisage a brain circuitry involving mainly left hemisphere parietal–frontal structures (Goldenberg, 2008; Heilman & Watson, 2008). Even the recent exhaustive model of the praxis system proposed by Heilman and Watson (2008) and based on the list of brain lesions that have been documented to produce the different forms of apraxia, does not lay down a specific role for the right premotor cortex. A literature search for papers that could provide an anatomic-functional basis for Lucio's intriguing condition led us to the work of Sanides (1964, 1970, 1972), who hypothesized two movement-generating anatomic-functional systems with different phylogenetic origins and different functions in gesture organization. A very ancient circuit, which he called medial system, mainly centred on the supplementary motor area (SMA), receives internally generated somatosensory (mainly proprioceptive) inputs, and would be involved in the generation of actions in response to internal needs of the body (predictive behaviour), while an evolutionarily more recent system comprising a neural circuit and centred on the lateral premotor cortex (LPC) – the lateral system – which receives signals from association auditory and visual areas, would underpin responsive behaviour, i.e. motor output produced in response to environmental stimuli. The hypothesis is consistent with Lucio's condition, where transmission of internal proprioceptive information coming from the right arm was associated with a correct performance, whereas the response to an external stimulus (visual or verbal) resulted in apraxia (imitation of the gesture performed by the examiner and the pantomime to verbal command).

Lesion studies have demonstrated the functional independence of SMA and LPC in the monkey brain. The motor behaviour of a monkey with an SMA lesion is qualitatively different from that of

a monkey with an LPC lesion (Brinkman, 1981; Goldberg, 1985; Passingham, 1987; Rizzolatti, Matelli, & Pavesi, 1983).

Similar human studies are also available (Della Sala, Marchetti, & Spinnler, 1991, 1994; De Renzi & Barbieri, 1992; Halsband, Ito, Tanji, & Freund, 1993). In particular, there is evidence that LPC lesions can give rise to apraxia (Kunesch, Binkofski, Steinmetz, & Freund, 1995). Functional neuroimaging studies of LPC function (Picard & Strick, 2001) have shown several similarities in brain organization with the monkey brain. These data suggest that a selective lesion in Lucio's right LPC is responsible for his condition.

Finally, selective damage to the LPC would explain why Lucio's apraxia was confined to his left arm and did not involve the ipsilateral leg. In monkeys, premotor cortical areas are connected to the primary motor cortex in a topologically organized manner, with SMA projections to the entire primary motor cortex encompassing the full body and LPC projections directed only to the face and upper limb representation areas (Godshalck, Lemon, Kuypers, & Runday, 1984). Lucio's case may be interpreted as evidence for a similar organization of the human brain.

The main criticism to this interpretation is that the transmission of an externally positioned posture may also be considered as an externally triggered stimulus; indeed, the order to execute a distinct gesture was given by the examiner and likely does not entail internal untriggered self-generation by the subject, i.e. the action is not made spontaneously, without a command specifying its shape.

We surmised that the proprioceptive system processed information similarly both for internal and for external inputs. Therefore, even if the initial shape of the gesture is not self-generated, it is processed like any internal stimulus conveyed by the proprioceptive system. Consequently, if the afferent sensory information received through the proprioceptive system lies in a medial circuit that conveys afferent proprioceptive stimuli to the ventral motor system hinging on the SMA, it is conceivable that whenever the proprioceptive system is activated (by inner and external stimuli) the information will be transferred to the same motor area, i.e. the SMA.

Another possible interpretation involves the functional lateralization of movement representation. Liepmann's classic suggestion (1920) that many right-handed people have either right hemisphere or bihemispheric lateralization of the motor network may explain both the absence of apraxia in several aphasic patients with left hemisphere lesions (Papagno, Della Sala, & Basso, 1993) and the apraxia seen in patients with right hemisphere injury (Rapcsak, Gonzalez Rothi, & Heilman, 1987). Lucio might thus have a partial bihemispheric lateralization with motor representations linked to visual and verbal information contained in the left hemisphere, and representations linked to proprioceptive information contained in the right hemisphere. Such an asymmetry might explain his preserved ability to imitate gestures to proprioceptive information. While the reason for this supposed anatomo-functional organization remains to be discovered, the hypothesis of an atypical functional lateralization is consistent with Lucio's atypical vascular pattern, with severe hypoplasia of both the right anterior cerebral artery and the left vertebral artery (with absence of the posterior cerebral artery). Alternatively, it might be hypothesized that such uncommon distribution of the arterial branches might have resulted in a lesion that is not generally seen in patients with classic neurovascular anatomy, i.e. that the different anatomical distribution of the cerebral arteries might have involved damage to a region that is not usually injured selectively in stroke.

Regardless of any interpretation, Lucio's case, providing evidence for a possible role of the right premotor cortex in apraxia, underscores Heilman's statement that "description of disconnection apraxias is far from being definitive. There is still much to be learned".

#### 4. Conclusions

In conclusion, the present study provides a contribution to the understanding of the neuropsychological and anatomo-functional bases of apraxia. Dissociation apraxia lends support to the notion that different types of environmental (visual, verbal) or inner stimuli (proprioceptive) can influence action execution, and consequently gesture performance, in a relatively independent manner. This conceivably indicates the existence of independent modules capable of separate activation of the circuits devoted to gesture execution. Another consideration regards the anatomical region involved in the generation of Lucio's dissociation apraxia, suggesting that the right premotor cortex can play an active role in the cortical praxis system. The present case can also add information for the further development of models that account for a modular and multimodal organization of the human brain.

#### Appendix A. List of the 10 meaningless gestures (postures and movements) used in the tasks exploring the influence of stimulus modality on the gesture performance

##### Postures

1. first and second fingers forming a circle, the others extended,
2. fingers flexed (as in fist), thumb trapped between second and third fingers,
3. first and fifth finger extended, others flexed,
4. arm abduction (90°), forearm flexed (90°), hand flexed (90°),
5. arm flexion (180°), forearm flexion (90°), extrarotation (45°); the limb lies over the head, palm towards examiner.

##### Movements

1. repeated touching of first and second fingers,
2. fingers tap table in turn,
3. from fist position, each finger extends in turn, beginning with thumb,
4. the hand rests on the opposite shoulder, the palm close to the breast; the arm is moved across the midline until the arm and the forearm are extended in front of the subject,
5. The hand rests on the forehead with the ulnar side in a cutting position; the forearm is intra- and extrarotated (palm and cut movement on the forehead).

#### References

- Benton, A. L., Hamsher, K., Varney, N. R., & Spreen, O. (1983). *Contribution to neuropsychological assessment*. New York: Oxford University Press.
- Brinkman, C. (1981). Lesions in supplementary motor area interfere with a monkey's performance of a bimanual coordination task. *Neuroscience Letters*, *27*, 267–270.
- Buxbaum, L. J. (2001). Ideomotor apraxia: A call to action. *Neurocase*, *7*, 445–458.
- Caltagirone, C., Gainotti, G., Masullo, C., & Miceli, G. (1979). Validity of some neuropsychological tests in the assessment of mental deterioration. *Acta Psychiatrica Scandinavica*, *60*, 50–56.
- Della Sala, S., Faglioni, P., Motto, C., & Spinnler, H. (2006). Hemisphere asymmetry for imitation of hand and finger movements, Goldemberg's hypothesis reworked. *Neuropsychologia*, *44*, 1496–1500.
- Della Sala, S., Marchetti, C., & Spinnler, H. (1994). The anarchic hand: A frontomesial sign. In F. Boller, & J. Grafman (Eds.), *Handbook of neuropsychology*, vol. 9. Amsterdam: Elsevier Science BV, p. 233–255.
- Della Sala, S., Marchetti, C., & Spinnler, H. (1991). Right-sided anarchic (alien) hand: A longitudinal study. *Neuropsychologia*, *29*, 1113–1127.
- De Renzi, E., & Barbieri, C. (1992). The incidence of the grasp reflex following hemispheric lesion and its relation to frontal damage. *Brain*, *115*, 293–313.
- De Renzi, E., & Faglioni, P. (1996). L'apraxia. In G. Denes, & L. Pizzamiglio (Eds.), *Manuale di neuropsicologia*. Bologna: Zanichelli, pp. 557–593.
- De Renzi, E., Faglioni, P., & Sorgato, P. (1982). Modality-specific and supramodal mechanisms of apraxia. *Brain*, *105*, 301–312.
- De Renzi, E., & Lucchelli, F. (1988). Ideational apraxia. *Brain*, *111*, 1173–1185.
- De Renzi, E., Motti, F., & Nichelli, P. (1980). Imitating gestures: A quantitative approach to ideomotor apraxia. *Archives of Neurology*, *37*, 6–10.



- De Renzi, E., & Vignolo, L. A. (1962). The token test: A sensitive test to detect receptive disturbances in aphasia. *Brain*, 85, 665–678.
- Folstein, M. F., Folstein, J. E., & McHugh, P. R. (1975). Mini-Mental State. *Journal of Psychiatric Research*, 12, 189–198.
- Godshalck, M., Lemon, R. N., Kuypers, H. G. I. M., & Runday, H. K. (1984). Cortical afferent and efferents of monkey postarcuate area: An anatomical and electrophysiological study. *Experimental Brain Research*, 56, 410–424.
- Goldberg, G. (1985). Supplementary motor area structure and function: Review and hypotheses. *The Behavioural Brain Sciences*, 8, 567–616.
- Goldberg, G. (1996). Defective imitation of gestures in patients with damage in the left or right hemispheres. *Journal of Neurology, Neurosurgery and Psychiatry*, 61, 176–180.
- Goldberg, G. (2008). Apraxia and the parietal lobes. *Neuropsychologia*, doi:10.1016/j.neuropsychologia.2008.07.014
- Goldberg, G. (2003). Apraxia and beyond: Life and work of Hugo Liepmann. *Cortex*, 39(3), 509–524.
- Goldberg, G., & Strauss, S. (2002). Hemisphere asymmetries for imitation of novel gestures. *Neurology*, 59, 893–897.
- Halsband, U., Ito, N., Tanji, J., & Freund, H. I. (1993). The role of the premotor cortex and the supplementary motor area in the temporal control of movement in man. *Brain*, 116, 243–266.
- Hanna-Pladdy, B., Heilman, K. M., & Foundas, A. L. (2001). Cortical and subcortical contributions to ideomotor apraxia. *Analysis of task demands and error types*. *Brain*, 124, 2513–2527.
- Hartmann, K., Goldberg, G., Daumüller, M., & Hermsdrfer, J. (2005). It takes the wool brain to make a cup of coffee: The neuropsychology of naturalistic actions involving technical devices. *Neuropsychologia*, 43, 625–637.
- Heilman, K. M. (1973). Ideational apraxia—A re-definition. *Brain*, 96, 861–864.
- Heilman, K. M., & Watson, R. T. (2008). The disconnection apraxias. *Cortex*, 44(8), 975–982.
- Kunesch, E., Binkofski, F., Steinmetz, H. N., & Freund, H. J. (1995). The pattern of motor deficits in relation to the site of stroke lesions. *European Neurology*, 35, 20–26.
- Leiguarda, R. C., & Marsden, D. (2000). Limb apraxias. Higher-order disorders of sensorimotor integration. *Brain*, 123, 860–879.
- Liepmann, H. (1900). Das krankheitsbild der apraxie (motorische asymbolie) auf grund eines falles von einseitiger apraxie. *Monatsschrift für Psychiatrie und Neurologie*, 8(15–44), 102–132, 182–197.
- Liepmann, H. (1920). Apraxia. *Erbgn der ges Med*, 1, 516–543.
- Litvan, I., Bhatia, K. P., Burn, D., Goetz, C. G., Lang, A. E., McKeith, I., et al. (2003). SIC task force appraisal of clinical diagnostic criteria for parkinsonian disorders. *Movement Disorders*, 18, 467–486.
- McKhann, G., Drachman, D., Folstein, M., Katzman, R., Price, D., & Stadlan, E. M. (1984). Clinical diagnosis of Alzheimer's disease: Report of the NINCDS-ADRDA Work Group under the auspices of the Department of Health and Human Services Task Force on Alzheimer's Disease. *Neurology*, 34, 939–944.
- Luzzi, S., Snowden, J. S., Provinciali, L., & Neary, D. (2004). Analysis of movement disorder in corticobasal degeneration. *Neurological Sciences*, 25(Suppl. S71).
- Miceli, G., & Capasso, R. (1991). *I disturbi del calcolo*. Milano: Masson.
- Papagno, C., Della Sala, S., & Basso, A. (1993). Ideomotor apraxia without aphasia and aphasia without apraxia: The anatomical support for a double dissociation. *Journal of Neurology, Neurosurgery and Psychiatry*, 56, 286–289.
- Passingham, R. E. (1987). Two cortical systems for directing movements. In *Ciba Foundation symposium*, vol. 132.
- Picard, N., & Strick, P. (2001). Imaging the premotor areas. *Current Opinion in Neurobiology*, 11, 663–672.
- Piccirilli, M., Finali, G., & Sciarra, T. (1989). Negative evidence of differences between right- and left- handers in interhemispheric transfer of information. *Neuropsychologia*, 27, 1023–1026.
- Rapcsak, S. Z., Gonzalez Rothi, L. J., & Heilman, K. M. (1987). Apraxia in a patient with atypical cerebral dominance. *Brain and Cognition*, 450–463.
- Raven, J. C. (1965). *Guide to using the coloured progressive matrices*. London: H.K. Lewis.
- Rey, A. (1959). *Test de copie d'une figure complex*. Paris: Centre de Psychologie Appliquée.
- Rizzolatti, G., Matelli, M., & Pavesi, G. (1983). Deficit in attention and movement following the removal of postarcuate (area 6) and prearcuate (area 8) cortex in macaque monkeys. *Brain*, 106, 655–673.
- Roy, E., Health, M., Westwood, D., Schweizer, T. A., Dixon, M. J., Black, S. E., et al. (2000). Task demands and limb apraxia in stroke. *Brain and Cognition*, 44, 253–279.
- Sanides, F. (1972). Representation of the cerebral cortex and its areal lamination patterns. In G. F. Bourne (Ed.), *Structure and function of the nervous tissue*, vol. 5. New York: Academic Press, pp. 329–453.
- Sanides, F. (1970). Functional architecture of motor and sensory cortices in primates in the light of a new concept of neocortex evolution. In C. Noback, & W. Montagna (Eds.), *The primate brain: Advances in primatology*, vol. 2. New York: Appleton-Century-Crofts, pp.137–208.
- Sanides, F. (1964). The cyto-myeloarchitecture of the human frontal lobe and its relation to phylogenetic differentiation of the cerebral cortex. *Journal Für Hirnforschung*, 47, 269–282.
- Spinnler, H., & Tognoni, G. (1987). Standardizzazione e taratura italiana di test neuropsicologici. *Italian Journal of Neurological Sciences*, 6(Suppl 8), 9–120.
- Warrington, E. K., & James, M. (1991). *The visual object and space perception battery (VOSP)*. Bury St Edmunds (UK): Thames Calley Test Company.
- Williams, P. L., & Warwick, R. (1980). *Gray's anatomy* (36th ed.). Edinburgh: Longman Group Ltd.
- Wilson, B., Cockburn, Y., & Halligan, P. (1987). Development of a behavioural test of visuospatial neglect. *Archives of Physical Medicine and Rehabilitation*, 68, 98–102.