

Case report

Characteristics of dystonia in the 18p deletion syndrome, including a new case

Anna G. Postma^{a,*}, Corien C. Verschuuren-Bemelmans^b, Klaas Kok^b, Teus van Laar^{a,*}

^a Department of Neurology, University Medical Center Groningen, University of Groningen, Groningen, The Netherlands

^b Department of Genetics, University Medical Center Groningen, University of Groningen, Groningen, The Netherlands

ARTICLE INFO

Article history:

Received 8 December 2008

Received in revised form 3 June 2009

Accepted 22 July 2009

Available online 20 August 2009

Keywords:

Dystonia

18p Deletion syndrome

DYT7

DYT15

ABSTRACT

Objective of the present study was to evaluate the possible pathophysiology and clinical characteristics of dystonia in patients with the 18p deletion syndrome by describing a new case and reviewing the literature. Dystonia in patients with the 18p deletion syndrome seems to present heterogeneously with a variable age of onset and distribution of symptoms. It may be accompanied with white matter lesions on the MRI. Deletion of 2 known dystonia loci on chromosome 18p, *DYT7* and *DYT15*, or the deletion of another dystonia gene just above the centromere of chromosome 18p may be the cause of dystonia in patients with the 18p deletion syndrome. However, dystonia may also be secondary to structural brain changes often seen in patients with the 18p deletion syndrome.

© 2009 Elsevier B.V. All rights reserved.

1. Introduction

Deletion of the short (p) arm of chromosome 18 (MIM number 146390) is one of the most common autosomal chromosomal abnormalities [1]. More than 150 cases have been reported in the literature [2]. The most prominent manifestations of the 18p deletion syndrome are mild to moderate mental retardation and dysmorphic features, including ptosis, strabismus, hypertelorism, a broad flat nose, big and low set ears and micrognathia. Postnatal growth retardation and malformations of the heart and brain are common medical problems [2]. However, the phenotype of patients with a chromosome 18p deletion is very variable [2].

Dystonia has only been described in six patients with the 18p deletion syndrome [19–23] and we present the history of a seventh patient with both the 18p deletion syndrome and dystonia. Dystonia is both clinically and genetically a heterogeneous disorder and is classified according to etiology, age of onset, inheritance and anatomical distribution [3,4]. At least 15 loci for dystonia have been defined (*DYT1–DYT15*) and some of their corresponding genes have been cloned [5–9]. Two loci are located on the short arm of chromosome 18: *DYT7* (MIM number 602124) and *DYT15* (MIM number 607488). This paper describes a new case with 18p-related dystonia, which is followed by a review of the existing cases, with respect

to their clinical characteristics and genetic profiles in patients with the 18p deletion syndrome.

2. Case report

The patient was seen at the department of Neurology of the University Medical Center Groningen. She was a 42-year-old woman, born to healthy, non-consanguineous parents after a normal pregnancy with a delivery lasting more than 24 h. She had one healthy, younger brother. During the neonatal period she had feeding difficulties. Early developmental milestones were delayed and she visited a specialized school because of learning problems. At the age of 22, she developed an intentional tremor and ptosis. At the age of 30, cervical dystonia presented for the first time and she started to develop progressive gait disturbances due to dystonic contractions of both legs (right > left). Furthermore, fine myoclonic jerks in both arms and legs were seen. The following dysmorphic features were present: bilateral ptosis, downslanting palpebral fissures, micrognathia, posterior rotated and protruding ears, a broad neck, pectus excavatum and clinodactylia of the fifth fingers (Video 1). The torticollis was successfully treated with repeated injections of botulinum toxin. The gait disturbances improved during treatment with trihexyfenidyl. No response to levodopa was observed.

2.1. Imaging

T1-weighted and T2-weighted *magnetic resonance images* (MRI) of the brain showed extensive bilateral multifocal white matter

* Corresponding authors. Movement Disorder Unit, Department of Neurology, University Medical Center Groningen, Hanzeplein 1, P.O. Box 30 001, 9700 RB Groningen, The Netherlands. Tel.: +31 50 361 6161; fax: +31 50 361 1707.

E-mail addresses: a.g.postma@neuro.umcg.nl (A.G. Postma), t.van.laar@neuro.umcg.nl (T. van Laar).

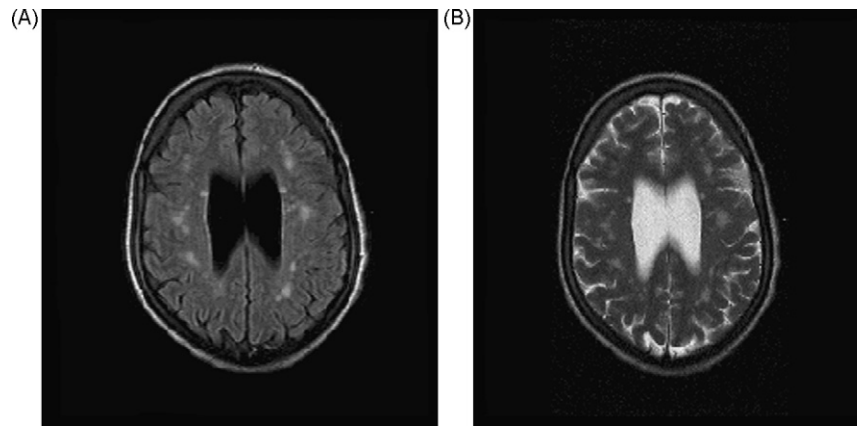


Fig. 1. White matter changes on MRI. (A) T1-weighted. (B) T2-weighted.

areas of increased signal and slight cortical atrophy. The basal ganglia did not show any abnormality (Fig. 1).

2.2. Cytogenetic analysis

Chromosome analysis revealed an abnormal female karyotype containing an unbalanced translocation between chromosome 18 and 21 with a monosomy of chromosome 18p: 45,XX,-18,-21,+der(18)t(18;21)(p11;q11). Parental karyotypes were normal, indicating a *de novo* origin for the translocation (18;21) in this patient.

2.3. Array-based comparative genomic hybridization

DNA of the patient was analyzed by array-based CGH, using a genome wide BAC array with an average density of one clone per 400 kb [10]. A deletion encompassing all clones but one from the short arm of chromosome 18 was the only copy number aberration detected for this patient. The retention of one clone just above the centromere was verified by FISH, localizing the breakpoint at 18p11.21 in a 600-kb genomic segment, ranging from 14.2 Mb until 14.8 Mb (NCBI build 36.1).

3. Discussion

DYT7 is located on the short arm of chromosome 18 and is a gene locus for adult-onset focal cervical dystonia. It has been localized in a German family and was reported to inherit in an autosomal dominant manner with reduced penetrance [11]. A founder mutation was suspected when analysis of other sporadic cases from the same area and central Europe with focal dystonia showed linkage disequilibrium for the marker D18S1098 (cytogenetic location 18p11.31–18p11.32) [12,13]. However, the authors were not able to confirm this finding by reanalysis of the original data [14]. Link-

age disequilibrium for these markers has not been found in other patients from northern Germany with focal dystonia either [15].

DYT15 is a gene locus of inherited myoclonus dystonia (IMD), which is a late-onset, autosomal dominant, non-progressive form of myoclonus, often seen in combination with dystonia [16,17]. *DYT15* has been mapped to 18p11 between the markers D18S1132 (18p11.31) and D18S843 (18p11.22) in a large Canadian family with IMD [9]. Recently this region has been reduced to 3.18Mb [18]. All known or predicted genes within this region were sequenced. No mutations in these genes could be identified, despite the existence of several candidate genes with potential roles within the CNS [18].

The presence of dystonia in seven patients with the 18p– syndrome, including the patient presented here, can be considered as additional evidence for the presence of one or more dystonia gene(s) on chromosome 18p (Table 1) [19–23].

Table 1 shows that the phenotype of dystonia in patients with the 18p– syndrome is heterogeneous. This variability is different from the well-defined complex of symptoms in patients with a probable mutation in *DYT7* or *DYT15*. It is therefore possible that the dystonia in 18p– patients results from different causes, like the combined loss of *DYT7* and *DYT15*, or from the loss of another gene closer to the centromere, possibly explaining the heterogenic clinical picture. Genetic evaluation in our patient revealed a breakpoint in 18p11.21 (Fig. 2), just above the centromere, which resembles all other published cases. Fig. 2 also shows an overlap in the mapped regions of *DYT7* and *DYT15* on 18p. Theoretically, this overlap region could contain a common gene related to dystonia, but this is not obligatory, because other regions of *DYT7* and *DYT15* may be causative as well.

A remaining question is why not every patient with the 18p– syndrome has dystonia? Reduced penetrance of the involved gene(s) may be the main reason, as has been suggested for mutations in *DYT7* and in cases of IMD [12,17]. It is not likely that the presence of dystonia in a patient with the 18p– syndrome is related

Table 1
Characteristics of patients with the 18p– syndrome and dystonia.

Patient ^a	Author(s)	Karyotype	Onset	Distribution
1	Kakinuma (1994) [20]	46,X,dic(Y;18)(p11;p11),inv(9)(p11q13)	?	Focal
2	Tezzon (1998) [23]	46,XY,18p–	?	Generalized
3	Awaad (1998) [19] Klein (1999) [21]	46,XY,del(18)(p11.1)	15 yrs	Segmental
4	Klein (1999) [21]	45,XX,-18,-21,+der(18q21q)t(18;21)mat.	12 yrs	Segmental
5	Klein (1999) [21]	18p deletion	17 yrs	Segmental
6	Nasir (2006) [22]	Complete deletion of 18p; unbalanced translocation between chrom. 14 and 18	Adolescent	Segmental
7	Postma (2009)	45,XX,-18,-21,+der(18)t(18;21)(p11;q11)	30 yrs	Generalized

^a In order of publication.

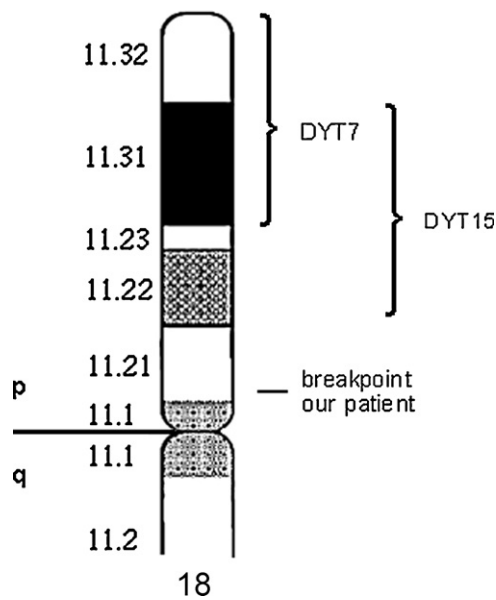


Fig. 2. Chromosome 18.

to the extent of the deletion, since a breakpoint close to the centromere has also been found in patients without dystonia [2].

Another interesting finding in our patient was the multiple unspecific foci of increased signal in the white matter on MRI. White matter changes on MRI have been observed in three other patients with 18p and dystonia as well [19,21]. One could speculate that the dystonia is related to white matter changes in the 18p deletion syndrome, however white matter changes are neither commonly found in the 18p– syndrome without dystonia [24], nor in idiopathic dystonia (ID) [25]. Publications of new patients with the 18p– syndrome and dystonia may provide further insight in this issue.

Although our patient showed distinct dysmorphic features, the appearance of an adult patient with a deletion of the short arm of chromosome 18 can also be nearly normal [26]. Karyotyping for 18p is therefore recommended in every patient presenting with dystonia, especially if the dystonia is accompanied by mental retardation and dysmorphic features.

Disclosure

Each author had full access to all of the data in the study and takes responsibility for the integrity of the data and the accuracy of the data analysis.

Conflict of interest

There are no conflicts of interest.

Funding

No funding was obtained for this paper.

Appendix A. Supplementary data

Supplementary data associated with this article can be found, in the online version, at doi:10.1016/j.clineuro.2009.07.013.

References

- [1] Schinzel A. Catalogue of unbalanced chromosome aberrations in man. Berlin, New York: De Gruyter; 2001.
- [2] Wester U, Bondeson ML, Edeby C, Anneren G. Clinical and molecular characterization of individuals with 18p deletion: a genotype–phenotype correlation. *Am J Med Genet A* 2006;140:1164–71.
- [3] Fahn S, Marsden CD, Calne DB. Classification and investigation of dystonia. In: Marsden CD, Fahn S, editors. *Movement disorders 2*. London: Butterworths; 1987. p. 332–58.
- [4] Fahn S, Bressman SB, Marsden CD. Classification of dystonia. *Adv Neurol* 1998;78:1–10.
- [5] Nemeth AH. The genetics of primary dystonias and related disorders. *Brain* 2002;125:695–721.
- [6] de Carvalho Aguiar PM, Ozelius LJ. Classification and genetics of dystonia. *Lancet Neurol* 2002;1:316–25.
- [7] Klein C, Ozelius LJ. Dystonia: clinical features, genetics, and treatment. *Curr Opin Neurol* 2002;15:491–7.
- [8] Grotzsch H, Pizzolato GP, Ghika J, et al. Neuropathology of a case of dopa-responsive dystonia associated with a new genetic locus, DYT14. *Neurology* 2002;58:1839–42.
- [9] Grimes DA, Han F, Lang AE, et al. A novel locus for inherited myoclonus-dystonia on 18p11. *Neurology* 2002;59:1183–6.
- [10] Kok K, Dijkhuizen T, Swart YE, et al. Application of a comprehensive subtelomere array in clinical diagnosis of mental retardation. *Eur J Med Genet* 2005;48:250–62.
- [11] Leube B, Rudnicki D, Ratzlaff T, et al. Idiopathic torsion dystonia: assignment of a gene to chromosome 18p in a German family with adult onset, autosomal dominant inheritance and purely focal distribution. *Hum Mol Genet* 1996;5:1673–7.
- [12] Leube B, Hendgen T, Kessler KR, et al. Sporadic focal dystonia in north-west Germany: molecular basis on chromosome 18p. *Ann Neurol* 1997;42:111–4.
- [13] Leube B, Hendgen T, Kessler KR, et al. Evidence for DYT7 being a common cause of cervical dystonia (torticollis) in Central Europe. *Am J Med Genet* 1997;74:529–32.
- [14] Leube B, Auburger G. Questionable role of adult-onset focal dystonia among sporadic dystonia patients. *Ann Neurol* 1998;44:984–5.
- [15] Klein C, Ozelius LJ, Hagenah J, et al. Search for a founder mutation in idiopathic focal dystonia from Northern Germany. *Am J Hum Genet* 1998;63:1777–82.
- [16] Mahloudji M, Pikielny RT. Hereditary essential myoclonus. *Brain* 1967;90:669–74.
- [17] Gasser T. Inherited myoclonus-dystonia syndrome. *Adv Neurol* 1998;78:325–34.
- [18] Han F, Racacho L, Lang AE, Bulman DE, Grimes DA. Refinement of the DYT15 locus in myoclonus dystonia. *Mov Disord* 2007;22:888–92.
- [19] Awaad Y, Munoz S, Nigro M. Progressive dystonia in a child with chromosome 18p deletion, treated with intrathecal baclofen. *J Child Neurol* 1999;14:75–7.
- [20] Kakinuma S, Sasabe F, Negoro K, Nogaki H, Morimatsu M. 18p-syndrome with bilateral pyramidal tract signs, dystonia of the lower extremities and concentric visual field defect. *Rinsho Shinkeigaku* 1994;34:474–8.
- [21] Klein C, Page CE, LeWitt P, et al. Genetic analysis of three patients with an 18p-syndrome and dystonia. *Neurology* 1999;52:649–51.
- [22] Nasir J, Frima N, Pickard B, et al. Unbalanced whole arm translocation resulting in loss of 18p in dystonia. *Mov Disord* 2006;21:859–63.
- [23] Tezzon F, Zanoni T, Passarin MG, Ferrari G. Dystonia in a patient with deletion of 18p. *Ital J Neurol Sci* 1998;19:90–3.
- [24] Kacinski M, Jaworek M, Skowronek-Bala B. Caudal regression syndrome associated with the white matter lesions and chromosome 18p11.2 deletion. *Brain Dev* 2007;29:164–6.
- [25] Draganski B, Thun-Hohenstein C, Bogdahn U, Winkler J, May A. Motor circuit gray matter changes in idiopathic cervical dystonia. *Neurology* 2003;61:1228–31.
- [26] Tonk V, Krishna J. Case report: de novo inherited 18p deletion in a mother-fetus pair with extremely variable expression, confirmed by fluorescence in situ hybridization (FISH) analysis. *Eur J Obstet Gynecol Reprod Biol* 1997;73:193–6.