

Panayiotopoulos syndrome with coincidental brain lesions

A. Destina Yalçın, Hülya Ertaşoğlu Toydemir, Lale Gündoğdu Çelebi, Hulki Forta

Neurology Clinic, Şişli Etfal Education and Research Hospital, Şişli-Istanbul, Turkey

Received January 11, 2009; Accepted July 16, 2009

ABSTRACT – Purpose. To describe the clinical and electroencephalographic features of three patients diagnosed with Panayiotopoulos syndrome with different lesions identified by cranial MRI investigation. **Methods.** Our study was based on patients from the Epilepsy Outpatient Clinic of Şişli Etfal Education Hospital in Istanbul, where a prospective study of Panayiotopoulos syndrome was initiated in 1995. Records of our Epilepsy Outpatient Clinic revealed 53 patients with Panayiotopoulos syndrome. Among them were three with cranial lesions identified by MRI. **Results.** The onset of the seizures in our patients ranged between five and eight years. The seizures included mainly autonomic symptoms such as nausea, vomiting, pallor, mydriasis, urinary and fecal incontinence, and rarely hypersalivation. Autonomic partial status was detected in one patient. The personal history of our patients revealed head trauma in two and difficult birth history in one patient. Two patients described simple febrile seizures. All patients had occipital spike or spike-wave complexes in their EEGs. The background activity was normal. From the cranial MRI, one patient had a neuroepithelial cyst, the second patient had a right occipital encephalomalacic lesion and the third patient had an arachnoid cyst located in the cisterna magna associated with colpocephaly. Seizure frequency was low in general. All patients except for one received carbamazepine treatment 450-600 mg/day. None of our patients had seizures under antiepileptic treatment. **Conclusions.** Children with Panayiotopoulos syndrome may have static MRI brain findings which are likely to be coincidental and do not affect prognosis.

Key words: autonomic seizures, occipital epilepsy, Panayiotopoulos syndrome, symptomatic epilepsy, cranial magnetic resonance imaging

An expert consensus has defined Panayiotopoulos syndrome (PS) as a benign age-related focal seizure disorder occurring in early and mid-childhood, characterized by seizures that are often prolonged, with predominantly autonomic symptoms, and by an EEG that shows shifting and/or multiple foci, often with occipital predominance (Ferrie *et al.*, 2006). PS is remarkably benign in terms of seizure frequency and evaluation (Covanis, 2006). It is the second most common benign childhood epi-

lepsy syndrome after Rolandic epilepsy. In this study, we describe the clinical and electroencephalographic features of three patients diagnosed with PS with different lesions detected by cranial MRI investigation.

Methods

Our study was based on patients from the Epilepsy Outpatient Clinic of Şişli Etfal Education Hospital (Istanbul, Turkey) where a prospective study of

Correspondence:

Dr A.D. Yalçın
Selçuklar Sokak,
Özlem Apt,
51/14, 34335 Akatlar,
Istanbul, Turkey
<destinayalcin@yahoo.com>

PS was initiated in 1995. Records of our Epilepsy Outpatient Clinic revealed 53 patients with PS, among them were three with cranial lesions identified by MRI who were included in the study.

The personal and family history, neurological state, age of onset, seizure type, duration and circadian distribution, EEGs, neuroimages and school performance were all reviewed. The parents and close relatives were asked whether they had experienced seizures during their childhood or not. The ictal symptomatology was assessed from the patients' own descriptions and their first-degree relatives. Seizures were classified according to the Commission of the International League Against Epilepsy (Commission on Classification and Terminology of the International League Against Epilepsy, 1989). All EEGs were performed in paperless EEG machines (Medelec DG compact 2000). Electrodes were placed according to the 10-20 International System. All records included three-minute long hyperventilation and intermittent photic stimulation in a selected stimulation range (0.5-30 Hz). Ictal recordings were not performed because of the difficulty in provoking seizures under laboratory conditions. Follow-up period for the three patients included regular visits every three months and many EEG recordings ranging between every four to six years.

Results

Patient 1

A five-year-old boy, had a simple febrile seizure at the age of two and a mild head trauma at the age of three. His parents described three episodes in one year, each lasting 30 to 45 minutes, when the boy was five years old. They

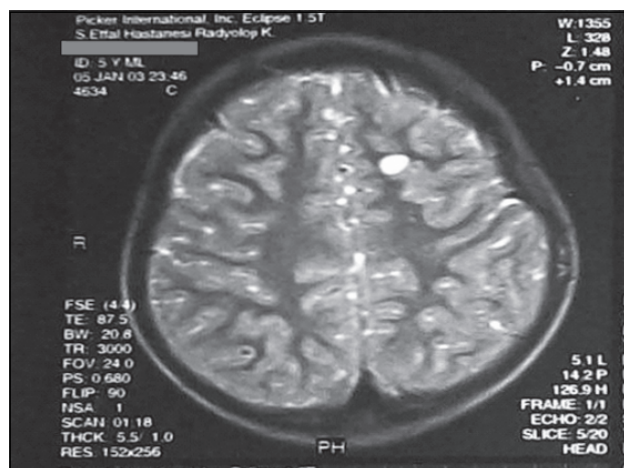


Figure 1. A small neuroepithelial cyst located in the left frontal lobe (Patient 1).

always started with stomach ache and nausea which caused the child to wake up, followed by pallor, mydriasis, vomiting and incontinence of urine and faeces. Afterwards he became flaccid and unresponsive and went to sleep. These episodes were interpreted as autonomic partial status. The cranial MRI revealed a neuroepithelial cyst located in the left frontal lobe (*figure 1*). The EEG recorded just immediately after an episode showed high amplitude spike-wave complexes on both occipital regions prominent on the left side (*figure 2*). Background activity was normal. The patient was followed without treatment for four and a half years, during which time the described episodes did not repeat. The subsequent EEGs in the follow-up period showed a shift of the abnormality located within the same regions. No difficulties were ever experienced at school. The patient is now nine years old.

Patient 2

A seven-year-old girl, was born after a prolonged and difficult delivery. She was not cyanotic at birth. She had a complicated head trauma at the age of three years. When she was seven years old, she had three seizures in six months; of which two were related to awakening. They occurred 30 minutes after awakening, started with a feeling of nausea and dizziness and were combined with pallor and mydriasis. As the patient ran towards the toilet, she fell down flaccidly. During the last seizure, the patient woke up in the middle of the night, complained of feeling unwell and was nauseous. She was pale, her pupils were markedly dilated and she vomited repeatedly. Walking towards the toilet, she again fell down flaccidly and slept for several hours. Based on cranial MRI, a right occipital encephalomalacic lesion was detected (*figure 3*). Her first EEG showed spikes on the right occipital region with a normal background activity which was prominent during sleep (*figure 4*). On further EEG recordings we also detected spikes on the left occipital region appearing mostly independent from the right side. Antiepileptic treatment of 600 mg/day of carbamazepine was started and no seizures were observed in the follow-up period of six years. The treatment was terminated last year when she was twelve years old and the patient is still seizure free. Her school performance was always good.

Patient 3

She suffered from a simple febrile seizure at the age of two. At the age of eight years she had three nearly identical diurnal seizures, each lasting 5-10 minutes. Seizures began with a feeling of nausea, followed by pallor, mydriasis, vomiting and hypersalivation. At the end of the seizure, the child became flaccid and unresponsive. Her cranial MRI showed an arachnoid cyst located in the cisterna magna associated with colpocephaly (*figures 5, 6*). Her

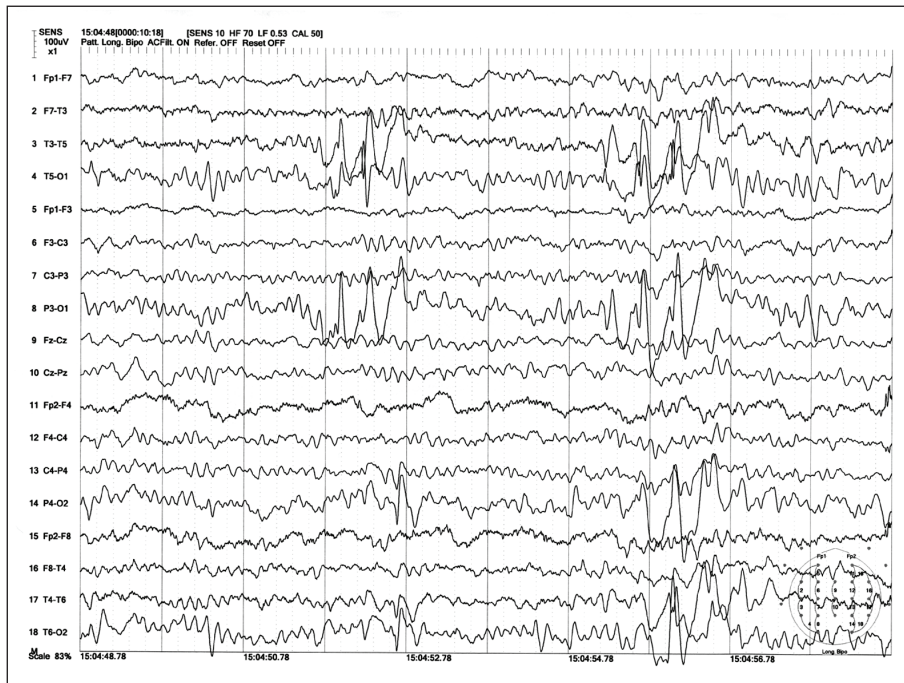


Figure 2. The interictal EEG recording shows high amplitude spike-wave complexes on both occipital regions more prominent on the left side (Patient 1).

repeated EEGs revealed occipital spike-wave complexes appearing almost always simultaneously on both sides (figure 7). Carbamazepine at a dose of 450 mg/day was administered after the third seizure and she had no other seizures in the follow-up period lasting four years. Her performance at school was above average.

Discussion

Panayiotopoulos syndrome was first described as “benign nocturnal childhood occipital epilepsy” in 1989 (Panayiotopoulos, 1989a, 1989b) and was cited in the new classification proposed by the ILAE in the group of idiopathic focal epilepsies of childhood together with benign Rolandic Epilepsy and occipital epilepsy, described by Gastaut (Engel, 2006). It can be best described as a childhood-related idiopathic susceptibility to partial seizures, mainly with autonomic ictal symptoms and electroencephalographically with occipital and extra-occipital spikes (Panayiotopoulos, 2005; Covanis, 2006; Ferrie et al., 2006; Koutroumanidis, 2007).

Age at onset varies between one and 12 years, but the first seizure generally presents at five years (Panayiotopoulos, 1988, 1999; Oguni et al., 1999; Caraballo et al., 2000). In our patients the seizures started between five and eight years in concordance with other studies.

In PS the seizures generally occur during sleep (Yalçın et al., 1997; Panayiotopoulos, 1999, 2005; Caraballo et al., 2007). In a typical seizure, the child is fully conscious, able to speak, wakes up with a feeling of sickness or nausea, looks pale and starts vomiting. Vomiting is the definite ictal symptom of PS, occurring in 70% of the cases (Kivity and Lerman, 1992; Beaumanoir, 1993; Dalla Bernardina et al., 1993; Vigeveno and Ricci, 1993; Maher et al., 1995; Fejerman, 1996; Ferrie et al., 1997; Panayiotopoulos, 2005). Two of our three patients woke up with initial symptoms of the seizure and in the

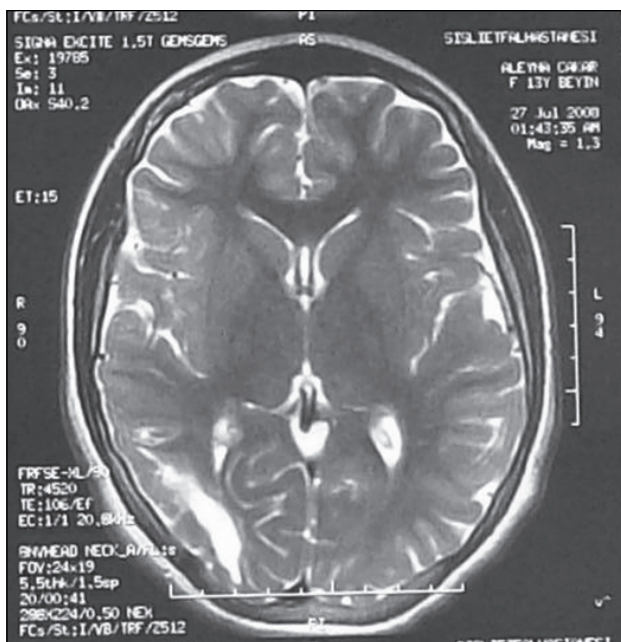


Figure 3. Right occipital encephalomalacic lesion (Patient 2).

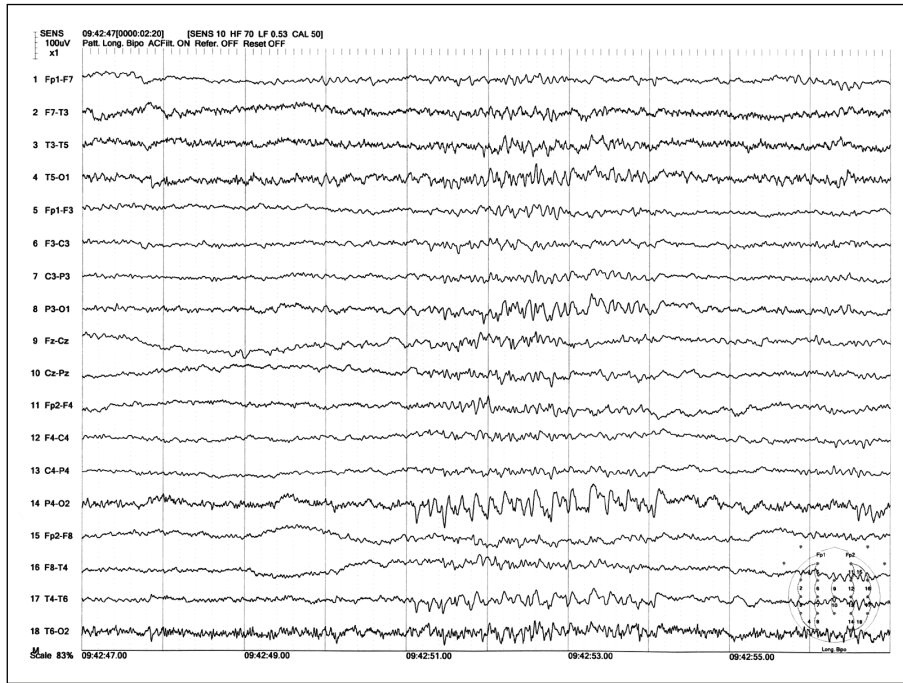


Figure 4. EEG recording during spontaneous sleep showing spikes on the right occipital region (Patient 2).

second patient two seizures occurred within 30 minutes after awakening. Vomiting was seen in all of our cases. Other ictal autonomic symptoms include mydriasis and less often miosis, cardiorespiratory and thermoregulatory alternations, urinary and fecal incontinence, coughing

and hypersalivation (Kivity and Lerman, 1992; Beaumanoir, 1993; Dalla Bernardina *et al.*, 1993; Vigeveno and Ricci, 1993; Maher *et al.*, 1995; Fejermann, 1996; Ferrie *et al.*, 1997; Yalçın *et al.*, 1997; Kivity *et al.*, 2000; Carballo *et al.*, 2007;

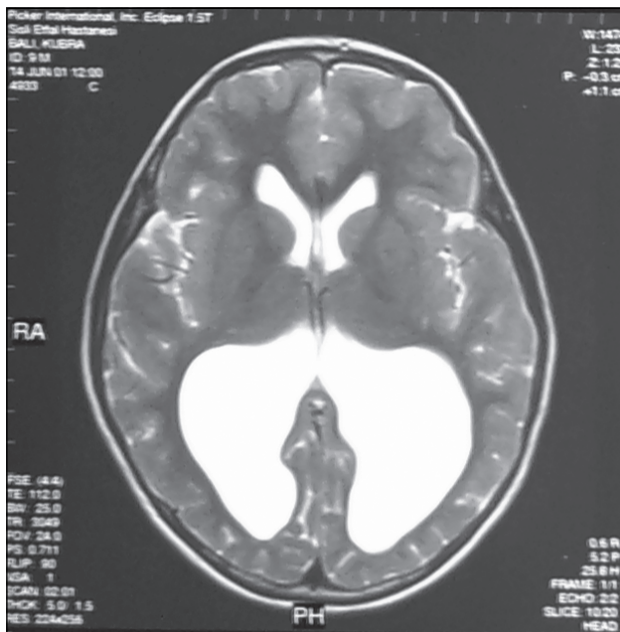

Figure 5. Enlargement of the occipital horns of the lateral ventricles (Patient 3).

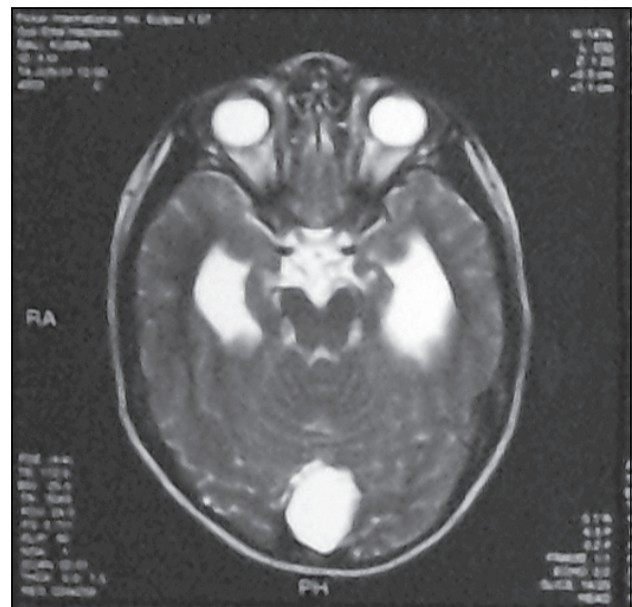


Figure 6. Arachnoid cyst located in the cisterna magna (Patient 3).

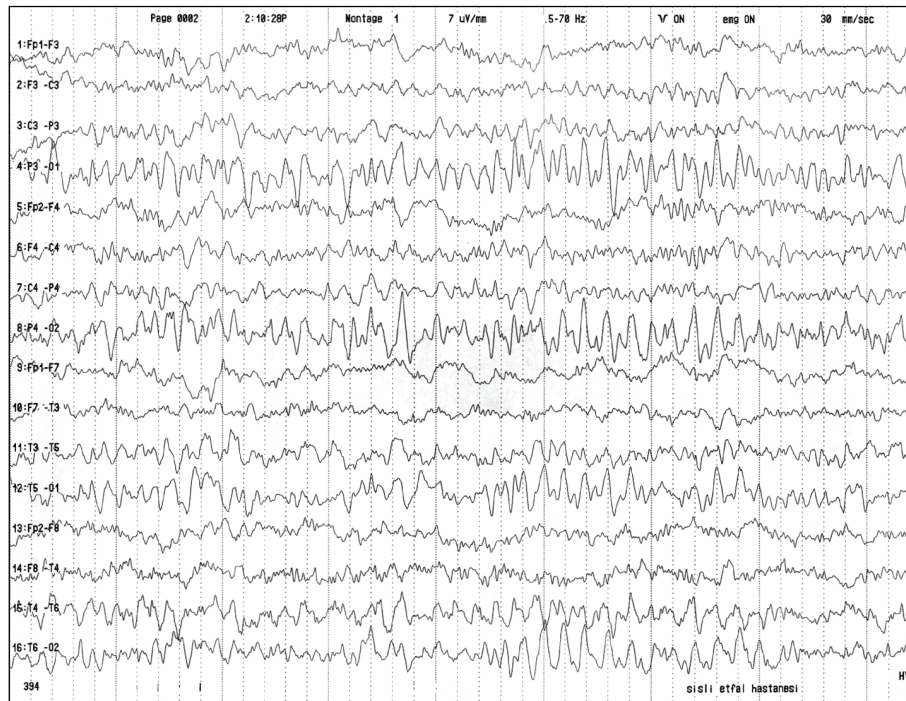

Figure 7. The interictal EEG recording illustrates occipital spikes, synchronously appearing on both sides (Patient 3).

Koutroumanidis, 2007). For PS, the whole seizure may be entirely autonomic, but commonly, other more conventional symptoms occur in the progress of the seizures. These mainly include deviation of the eyes and impairment of consciousness; visual hallucinations and illusions may occur, but these are not present at onset. Seizures of idiopathic childhood occipital epilepsy of Gastaut are exclusively occipital and onset predominantly consists of elementary visual hallucination (Panayiotopoulos, 2005; Covanis, 2008). None of our patients described a visual ictal symptom.

Another ictal symptom specific to PS is “ictal syncope”. This is defined as loss of postural tonus and consciousness and is detected in 20% of patients. During this episode, the child becomes unresponsive, appears pale with blue lips and falls down (Panayiotopoulos, 1992, 2005; Caraballo *et al.*, 2007; Koutroumanidis, 2007). In our group, ictal syncope was described in all patients.

An unusual and crucial feature of PS is partial status epilepticus reported in 44% of affected children (Panayiotopoulos, 2002, 2005; Koutroumanidis *et al.*, 2005). In our group it was diagnosed only in one patient. For PS, seizures infrequently recur and end after one or two years whether they are treated or not, as for Rolandic epilepsy (Panayiotopoulos, 1988, 1989a, 1989b, 1992; Kivity and Lerman, 1992; Vigeveno and Ricci, 1993; Maher *et al.*, 1995; Fejermann, 1996; Ferrie *et al.*, 1997). Frequency of the seizures or the presence of partial status epilepticus do not affect this progression.

The principle of a follow-up without treatment for Rolandic epilepsy is also valid for these cases (Yalçın *et al.*, 1997; Panayiotopoulos, 1999; Covanis, 2006; Koutroumanidis, 2007). An expert consensus statement concluded that a prophylactic treatment with antiepileptic drugs was probably best reserved for children whose seizures were unusually frequent, distressing, or otherwise significantly interfering with the child’s life (Ferrie *et al.*, 2006). In our group, seizure frequency was also low. Our first patient was followed without treatment. In two of our cases, under low dose carbamazepine treatment, seizures did not recur. For the second patient the treatment was discontinued and she remained seizure-free.

The EEG, the most useful diagnostic test for PS, shows functional spikes in many brain lesions predominantly in occipital and centro-temporal location (Oguni *et al.*, 1999; Covanis *et al.*, 2003; Lada *et al.*, 2003; Ohtsu *et al.*, 2003). As for Rolandic epilepsy, the spikes in PS tend to shift from one side to another. The EEGs of our cases displayed normal background activity with high-voltage spikes and spike-waves over the occipital area. Spikes located in regions other than the occipital area were not detected.

Autonomic ictal signs and symptoms typical for PS can also be observed in symptomatic cases. A comprehensive study evaluating autonomic symptoms and signs during partial epileptic seizures in 100 children with symptomatic focal epilepsies provides crucial differences between symptomatic and idiopathic epilepsies in

childhood (Fogarasi *et al.*, 2006). Regarding the most important ictal manifestations, in the symptomatic group, typical psychomotor or motor seizures predominate. In this group, vomiting, the cardinal ictal symptom of PS, usually occurs alone and seldomly with other autonomic ictal symptoms. Vomiting also appears in the late sequence of the seizure and frequently in the postictal period. In the idiopathic group, including mainly PS, in contrast, the autonomic signs or symptoms can be the sole ictal manifestation and vomiting occurs early in the seizure sequence.

Autonomic status epilepticus is described in 44% of affected children with PS but not detected in the symptomatic group. Ictal syncope, a highly specific ictal symptom of PS, was described as atonic seizure only in four children in the symptomatic group. The described autonomic ictal symptoms and signs in our patients were in concordance with the idiopathic group.

Most authors consider cognitive, neurological and anatomical findings as the basis for the diagnosis of idiopathic forms of epilepsy, especially for benign childhood focal epilepsies, however, because of their high prevalence they may incidentally occur in children with neurocognitive deficits or abnormal brain scans (Panayiotopoulos *et al.*, 2008). Since the appearance of modern neuroimaging procedures, abnormal findings have been reported in patients with benign Rolandic epilepsy (Gelisse *et al.*, 1999, 2003; Lundberg *et al.*, 1999). In our cases, the MRI documented a left frontal neuroepithelial cyst, a right occipital encephalomalasic lesion and an arachnoid cyst located in the cisterna magna associated with colpocephaly. We believe that the MRI lesions are unrelated to the seizures. The first patient's left frontal neuroepithelial cyst could be involved in epileptogenesis but the presence of exclusively occipital spikes in the repeated EEGs is strong evidence against this possibility. The seizure symptomatology of our second patient, who had a right occipital encephalomalasic lesion, was not found to be in concordance with seizures originating from the occipital lobe. These usually start with visual auras, commonly including elementary visual hallucinations or, rarely, ictal blindness. Contralateral head and eye deviation, blinking and nystagmoid eye movements are described, especially when the seizures progress (Panayiotopoulos, 2002). None of these ictal symptoms were observed or described in our patient. Despite discontinuation of antiepileptic treatment she remained seizure-free, which could be interpreted as strong evidence for the benignity of her seizures. Because of its nature and topography, the arachnoid cyst is unlikely to be epileptogenic. Most of the studies investigating the relationship between arachnoid cysts and epilepsy concluded that there is no association between them and arachnoid cysts can be incidentally discovered by conducting an MRI of epileptic patients, as in the case of our last patient (Yalçın *et al.*, 2002; Betting *et al.*, 2006; Ozisik *et al.*, 2008).

We believe that our patients show the typical electroclinical traits of PS, despite cerebral lesions. The three lesions reported here do not influence prognosis, thus supporting the idiopathic nature and the benign course of our patients. □

Disclosures.

None.

References

- Beaumanoir A. Semiology of occipital seizures in infants and children. In: Anderman F, Beaumanoir A, Mira L, Roger J, Tassinari CA, eds. *Occipital Seizures and Epilepsies in Children*. London: John Libbey and Company Ltd, 1993: 71-86.
- Betting LE, Mory SB, Lopes-Cendes I, *et al.* MRI reveals structural abnormalities in patients with idiopathic epilepsy. *Neurology* 2006; 67: 848-52.
- Carballo R, Cers'osimo R, Medina C, Fejerman N. Panayiotopoulos-type benign childhood occipital epilepsy: A prospective study. *Neurology* 2000; 55: 1096-100.
- Carballo RH, Cersosimo R, Fejerman N. Panayiotopoulos Syndrome: A prospective study of 192 patients. *Epilepsia* 2007; 48: 1054-106.
- Commission on Classification and Terminology of the International League Against Epilepsy. Proposal for revised classification of epilepsies and epileptic syndromes. *Epilepsia* 1989; 30: 389-99.
- Covanis A, Lada C, Skiadas K. Children with rolandic spikes and ictus emeticus: Rolandic epilepsy or Panayiotopoulos syndrome? *Epileptic Disord* 2003; 5: 139-43.
- Covanis A. A benign childhood autonomic epilepsy frequently imitating encephalitis, syncope, migraine, sleep disorder, or gastroenteritis. *Pediatrics* 2006; 118: 1237e-1243e.
- Covanis A. Correspondence on "Childhood epilepsy with occipital paroxysms: difficulties in distinct segregation into either the early-onset or late-onset subtypes". *J Child Neurol* 2008; 23: 1085-6.
- Dalla Bernardina B, Fontana E, Carballo R, Zullini E, Darra F, Collamaria V. The partial occipital epilepsies in childhood. In: Andermann F, Beaumanoir A, Mira L, Roger J, Tassinari CA, eds. *Occipital Seizures and Epilepsies in Children*. London: John Libbey and Company Ltd, 1993: 173-81.
- Engel Jr J. Report of the ILAE classification core group. *Epilepsia* 2006; 47: 1558-68.
- Fejerman N. Atypical evolutions of benign partial epilepsies in children. *Pediatr Int* 1996; 11: 351-6.
- Ferrie CD, Beaumanoir A, Guerrini R, *et al.* Early-onset benign occipital seizure susceptibility syndrome. *Epilepsia* 1997; 38: 285-93.
- Ferrie CD, Carballo R, Covanis A, *et al.* Panayiotopoulos syndrome: A consensus view. *Dev Med Child Neurol* 2006; 48: 236-40.
- Fogarasi A, Janszky J, Tuxhorn I. Autonomic symptoms during childhood partial epileptic seizures. *Epilepsia* 2006; 47: 584-8.

- Gelisse P, Corda D, Raybaud C, Dravet C, Bureau M, Genton P. Abnormal neuroimaging in patients with benign epilepsy with centrotemporal spikes. *Epilepsia* 2003; 44: 372-8.
- Gelisse P, Genton P, Raybaud C, Thiry A, Pincemaille O. Benign childhood epilepsy with centrotemporal spikes and hippocampal atrophy. *Epilepsia* 1999; 40: 1312-5.
- Kivity S, Lerman P. Stormy onset with prolonged loss of consciousness in benign childhood epilepsy with occipital paroxysms. *J Neurol Neurosurg Psychiatry* 1992; 55: 45-8.
- Kivity S, Ephraim T, Weitz R, Tamir A. Childhood epilepsy with occipital paroxysms: Clinical variants in 134 patients. *Epilepsia* 2000; 41: 1522-33.
- Koutroumanidis M, Rowlinson S, Sanders S. Recurrent autonomic status epilepticus in Panayiotopoulos syndrome: video/EEG studies. *Epilepsy Behav* 2005; 7: 543-7.
- Koutroumanidis M. Panayiotopoulos syndrome: an important electroclinical example of benign childhood system epilepsy. *Epilepsia* 2007; 48: 1044-53.
- Lada C, Skiadas K, Theodorou V, Covanis A. A study of 43 patients with Panayiotopoulos syndrome: A common and benign childhood seizure susceptibility. *Epilepsia* 2003; 44: 81-8.
- Lundberg S, Eeg-Olofsson O, Raininko R, Eeg-Olofsson KE. Hippocampal asymmetries and white matter abnormalities on MRI in benign childhood epilepsy with centro-temporal spikes. *Epilepsia* 1999; 40: 1808-15.
- Maher J, Ronen GM, Ogunyemi AO, Goulden KJ. Occipital paroxysmal discharges suppressed by eye opening: Variability in clinical and seizure manifestations in childhood. *Epilepsia* 1995; 36: 52-7.
- Oguni H, Hayashi K, Imai K, Muto K, Osawa M. Study on the early-onset variant of benign childhood epilepsy with occipital paroxysms otherwise described as early-onset benign occipital seizure susceptibility syndrome. *Epilepsia* 1999; 40: 1020-30.
- Ohtsu M, Oguni H, Hayashi K, Funatsuka M, Imai K, Osawa M. EEG in children with early-onset benign occipital seizure susceptibility syndrome: Panayiotopoulos syndrome. *Epilepsia* 2003; 44: 435-42.
- Ozisk HI, Sarac K, Ozcan C. Single-voxel magnetic resonance spectroscopy of brain tissue adjacent to arachnoid cysts of epileptic patients. *Neurologist* 2008; 14: 382-9.
- Panayiotopoulos CP. Vomiting as an ictal manifestation of epileptic seizures and syndromes. *J Neurol Neurosurg Psychiatry* 1988; 51: 1448-51.
- Panayiotopoulos CP. Benign nocturnal childhood occipital epilepsy: A new syndrome with nocturnal seizures, tonic deviation of the eyes, and vomiting. *J Child Neurol* 1989; 4: 43-9.
- Panayiotopoulos CP. Benign childhood epilepsy with occipital paroxysms: A 15-year prospective study. *Ann Neurol* 1989; 26: 51-6.
- Panayiotopoulos CP. Cerebral insult-like partial status epilepticus in the early-onset variant of benign childhood epilepsy with occipital paroxysms. *Seizure* 1992; 1: 99-102.
- Panayiotopoulos CP. *Benign Childhood Partial Seizures and Related Epileptic Syndromes*. London: John Libbey & Company Ltd, 1999.
- Panayiotopoulos CP. *Panayiotopoulos Syndrome; a Common and Benign Childhood Epileptic Syndrome*. London: John Libbey & Company Ltd, 2002.
- Panayiotopoulos CP. Benign childhood focal seizures and related epileptic syndromes. In: Panayiotopoulos CP, ed. *The Epilepsies: Seizures, Syndromes and Management*. Oxford: Bladon Medical Publishing, 2005: 223-69.
- Panayiotopoulos CP, Michael M, Sanders S, Valeta T, Koutroumanidis M. Benign childhood focal epilepsies: assesment of established and new recognized syndromes. *Brain* 2008; 131: 2264-86.
- Vigevano F, Ricci S. Benign occipital epilepsy of childhood with prolonged seizures and autonomic symptoms. In: Andermann F, Beaumanoir A, Mira L, Roger J, Tassinari CA, eds. *Occipital Seizures and Epilepsies in Children*. London: John Libbey and Company Ltd, 1993: 133-40.
- Yalçın AD, Kaymaz A, Forta H. Childhood occipital epilepsy: Seizure manifestations and electroencephalographic features. *Brain Dev* 1997; 19: 408-13.
- Yalçın AD, Öncel Ç, Kaymaz A, Kuloğlu N, Forta H. Evidence against association between arachnoid cysts and epilepsy. *Epilepsy Res* 2002; 49: 255-60.