

Recurrent Subacute In-stent Restenosis After Carotid Artery Stenting due to Plaque Protrusion

—Case Report—

Tomoji TAKIGAWA, Yuji MATSUMARU, Takeshi KUBO,
Noriaki FUKUHARA*, Mikito HAYAKAWA, and Masaaki USUI*

*Departments of Endovascular Neurosurgery and *Neurosurgery, Toranomon Hospital, Tokyo*

Abstract

A 70-year-old male presented with transient ischemic attacks manifesting as right hemiparesis and motor aphasia due to severe left cervical internal carotid artery stenosis. Carotid artery stenting (CAS) using a flow-reversal system was performed without complications. However, the patient exhibited transient right hemiparesis and motor aphasia 10 days after CAS. Emergent angiography demonstrated in-stent restenosis. In-stent percutaneous transluminal angioplasty and CAS were performed successfully using a distal protection system. However, duplex ultrasound scanning revealed progressive in-stent restenosis, 3 and 6 days after the re-treatment. Emergent angiography again demonstrated in-stent restenosis. Urgent stent removal and carotid endarterectomy were performed. Plaque had prolapsed through the stent. Histological examination revealed that the specimen was mainly plaque consisting of cholesterol crystals and macrophages. The patient was able to return to independent life without neurological deficit. Repeated endovascular surgery with appropriate antiplatelet and anticoagulation therapy should be attempted initially to treat in-stent restenosis. Endarterectomy with stent removal should be considered as a rescue option, especially if plaque protrusion is identified.

Key words: carotid artery stenting, in-stent restenosis, plaque protrusion, thromboendarterectomy, stent removal

Introduction

Carotid artery stenting (CAS) is widely used to treat severe carotid obstructive disease and prevent future ischemic stroke,^{5,10,12,18,20,22,23,27,34,36} and is a safe and effective alternative to carotid endarterectomy (CEA) to treat severe internal carotid artery (ICA) stenosis in patients with high risks for surgery.^{7,13,32,33,36,37} Various clinical trials are in progress to establish the indications for CAS.^{34,36} Acute or subacute in-stent restenosis, which is a potentially devastating complication of CAS, is a rare event that occurs in 0.04% to 2% of all cases, but can cause severe neurological deficits.^{4,6,10,11,18,22,23,27} Acute in-stent restenosis is usually caused by thrombosis. However, acute restenosis due to plaque protrusion has been reported, because the cause of restenosis is difficult to distinguish by angiography or duplex ultrasound scanning.^{8,15,35} No suitable strategy for the treatment of acute in-stent restenosis has been established.

We report a case of recurrent subacute in-stent restenosis after CAS that was ultimately resolved by CEA with stent removal, and histological examination confirmed that the stenosis was due to plaque protrusion.

Case Report

A 70-year-old man with a history of diabetes mellitus, hypertension, and atrial fibrillation presented with recurrent transient right hemiparesis and motor aphasia. He had already been treated with antiplatelet and anticoagulation therapy (aspirin 100 mg/day, warfarin 4 mg/day). On admission, diffusion-weighted magnetic resonance (MR) imaging did not reveal any abnormal high intensity area. Duplex ultrasound scanning demonstrated occlusion of the right ICA and severe left ICA stenosis with hypoechoic plaque. Cerebral angiography also demonstrated right ICA occlusion and very severe stenosis of the left cervical ICA with delayed filling of the distal portion (Fig. 1). The left anterior circulation was fed by the flow from posterior circulation via the posterior communicating artery and the external carotid artery via the ophthalmic artery. The patient was considered to have high risks for surgery because of the subtotal occlusion of the left cervical ICA and contralateral ICA occlusion.^{21,37} Therefore, CAS was planned. Cilostazol (200 mg/day) was administered and warfarin was changed to systemic heparinization to maintain the activated clotting time between 200 and 250 seconds 3 days prior to the procedure.

CAS was performed using the reversed-flow system for embolic protection.¹⁹ We selected a closed-cell stent design to prevent plaque shift and distal embolization because the stenosis was considered to be lipid-rich soft

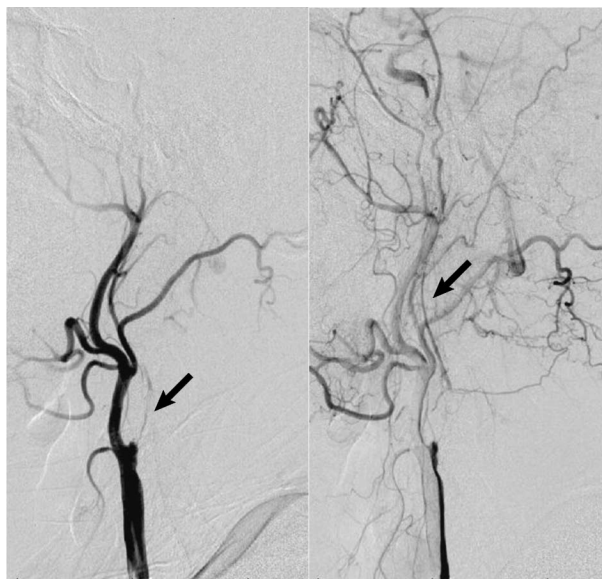


Fig. 1 Left carotid angiograms on admission, lateral view, revealing the nearly occluded left internal carotid artery (arrow).

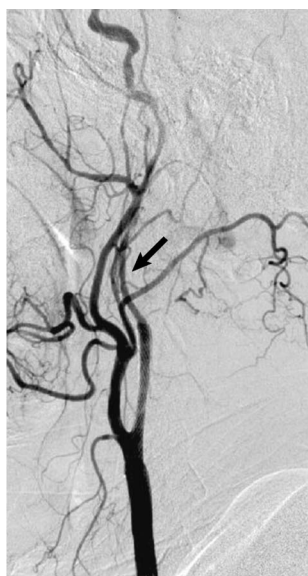

Fig. 2 Left carotid angiogram immediately after carotid artery stenting and percutaneous transluminal angioplasty revealing recanalization of the left internal carotid artery (arrow).

plaque. A Wallstent RP (9.0 × 18 mm; Boston Scientific, Natick, Mass., U.S.A.) was placed across the ICA stenosis after dilation using an Amiia balloon catheter (4.0 × 40 mm; Johnson & Johnson, New Brunswick, N.J., U.S.A.). Residual stenosis at the distal portion of the stent was dilated using a Gateway balloon catheter (Boston Scientific). Subsequent angiography showed resolution of the stenosis and excellent flow through the intracranial vessel (Fig. 2).

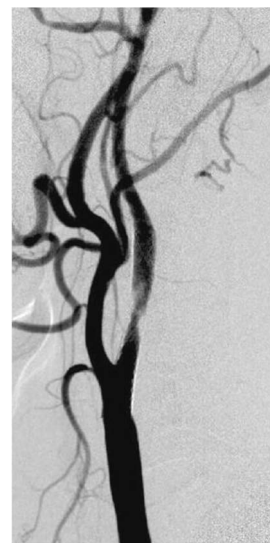

Fig. 3 Left carotid angiogram before in-stent carotid artery stenting and percutaneous transluminal angioplasty revealing stent restenosis.

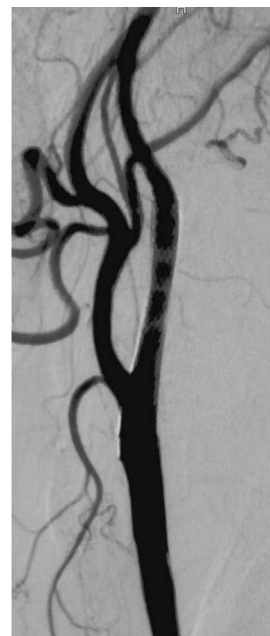

Fig. 4 Post procedure left carotid angiogram showing adequate dilation.

The patient's neurological status did not change during the procedure, and the post CAS course was uneventful until day 10 with medical treatment including aspirin, cilostazol, and warfarin.

Ten days after CAS, the patient suffered recurrence of the transient right hemiparesis. Diffusion-weighted MR imaging revealed a small high intensity area in the left frontal region. Emergent duplex ultrasound scanning and angiography demonstrated in-stent restenosis (Fig. 3). We

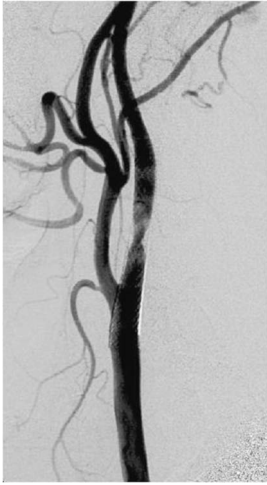

Fig. 5 Left carotid angiogram revealing recurrence of the in-stent restenosis.

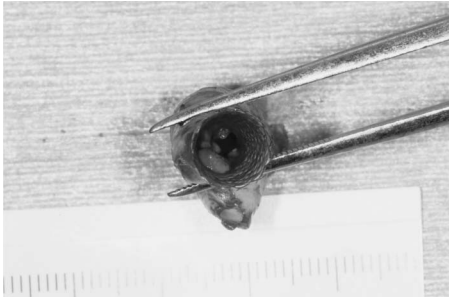


Fig. 6 Photograph showing plaque prolapsed through the cell stent.

placed another Wallstent RP (9 × 18 mm; Boston Scientific) in the stented ICA after angioplasty with the Amia balloon catheter (4.0 × 40 mm; Johnson & Johnson) using a distal protection system based on the PercuSurge Guardwire system (Medtronic AVE, Danvers, Mass., U.S.A.). Angiography performed immediately after the second CAS revealed sufficient dilation without thrombus (Fig. 4).

The postoperative course was uneventful. However, follow-up duplex ultrasound scanning 3 days after the second CAS showed 20% in-stent restenosis that worsened to 70% restenosis 6 days after CAS. Emergent angiography was performed and again demonstrated in-stent restenosis (Fig. 5). On the same day, the stent was removed and CEA was performed. During the procedure, plaque was found to have prolapsed through the struts of the stent (Fig. 6). Histological examination revealed that the tissue prolapsed into the vessel was mainly plaque consisting of cholesterol crystals and macrophages (Fig. 7).

Follow-up duplex ultrasound scanning and three-dimensional computed tomography did not show restenosis and MR imaging revealed no further cerebral infarction. On discharge, the patient had no neurological symptoms, and

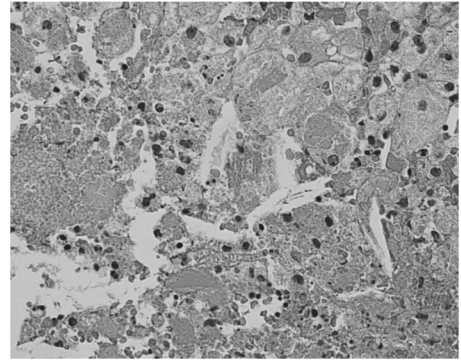


Fig. 7 Photomicrograph revealing that the specimen was mainly plaque consisting of cholesterol crystals and macrophages. Hematoxylin-eosin stain, × 100.

was able to resume his previous independent life.

Discussion

Restenosis due to plaque protrusion has recently been detected using intravascular ultrasound (IVUS).³¹⁾ IVUS may help to identify embolic material or plaque histologies. IVUS has documented intraluminal lesions, including ruptured plaques and thrombi in the coronary area.²⁹⁾ However, routine use to assess post-procedural stent dimensions remains limited because of the potential increase in thromboembolic risk and increased procedure time. In our case, IVUS was not available because of the emergent nature of the procedure.

Acute thrombosis after intervention is the result of aggregation of activated platelets.^{14,17)} Medication with aspirin and ticlopidine after coronary artery stenting prevents thrombus formation more effectively than medication with only heparin or with aspirin and warfarin.¹⁶⁾ Therefore, combination antiplatelet therapy is currently recommended as the standard periprocedural medication to prevent thrombosis. However, combined antiplatelet therapy may affect the thrombus attached to the prolapsed plaque, and not the plaque protrusion.

No standard strategy for the treatment of early carotid restenosis has been established. Recently, repeat angioplasty and even re-stenting have been used to treat in-stent restenosis after CAS.^{1,2,4,6,11,15,24,28)} Combination therapy using percutaneous mechanical thrombectomy and adjunctive intravenous abciximab has been successful for acute carotid stent thrombosis.^{4,28)} Patients who undergo CAS generally have high risks for surgical treatment. Endovascular treatment with appropriate medication may be effective for early restenosis as the first option.

In our case, medication and repeated endovascular treatment were not effective, possibly because the medication could not resolve the plaque protrusion. Furthermore, the plaque could not be removed by stenting. Soft and lipid-rich plaque could prolapse through the struts of the stent and repeat endovascular treatment might worsen the plaque protrusion.

Standard CEA with stent removal is effective.^{3,9,25,26,30} CEA was successful 6 months after CAS with a stainless steel stent.³⁰ Three patients were managed surgically for acute restenosis after CAS, but the operation was complicated by the length of ICA exposure required, difficulty in opening the stented artery, and the care necessary in removing the plaque and stent to avoid vessel wall penetration.²⁵ If restenosis occurs in the carotid artery after CAS, surgical options are limited as a first option. If repeat endovascular surgery fails, surgical removal may be an effective rescue option.

The present case illustrates the problems involved in the management of subacute in-stent restenosis due to plaque protrusion. Repeated endovascular surgery with appropriate antiplatelet and anticoagulation should be attempted initially. However, restenosis is due to plaque protrusion may prove refractory. IVUS is recommended to identify the plaque protrusion. Repeated duplex ultrasound scanning is a possible alternative if IVUS is not available. Endarterectomy with stent removal should be considered as a rescue option.

References

- 1) Ammar AD: Concerns regarding carotid artery angioplasty and stenting. *Stroke* 27: 2143-2144, 1996
- 2) Bergeron P, Rudondy P, Benichou H, Raybaud G, Pellati R, Guennaoui T, Courbier R: Transluminal angioplasty for recurrent stenosis after carotid endarterectomy. *Int Angiol* 12: 256-259, 1993
- 3) Brown KR, Desai TR, Schwartz LB, Gewertz BL: Operative intervention for recurrent stenosis after carotid stent angioplasty: a report. *Ann Vasc Surg* 16: 575-578, 2002
- 4) Bush RL, Bhama JK, Lin PH, Lumsden AB: Transient ischemic attack due to early carotid stent thrombosis: successful rescue with rheolytic thrombectomy and systemic abciximab. *J Endovasc Ther* 10: 870-874, 2003
- 5) CAVATAS investigators: Endovascular versus surgical treatment in patients with carotid stenosis in the Carotid and Vertebral Artery Transluminal Angioplasty Study (CAVATAS): a randomized trial. *Lancet* 357: 1729-1737, 2001
- 6) Chaturvedi S, Sohrab S, Tselis A: Carotid stent thrombosis: report of 2 fatal cases. *Stroke* 32: 2700-2702, 2001
- 7) Clark DJ, Lessio S, O'Donoghue M, Schainfeld R, Rosenfield K: Safety and utility of intravascular ultrasound-guided carotid artery stenting. *Catheter Cardiovasc Interv* 63: 355-362, 2004
- 8) Clark DJ, Lessio S, O'Donoghue M, Tsalamandris C, Schainfeld R, Rosenfield K: Mechanisms and predictors of carotid artery stent restenosis: a serial intravascular ultrasound study. *J Am Coll Cardiol* 47: 2390-2396, 2006
- 9) de Borst GJ, Ackerstaff RG, Mauser HW, Moll FL: Operative management of carotid artery in-stent restenosis: first experiences and duplex follow-up. *Eur J Vasc Endovasc Surg* 26: 137-140, 2003
- 10) Diethrich EB, Ndiaye M, Reid DB: Stenting in the carotid artery: initial experience in 110 patients. *J Endovasc Surg* 3: 42-62, 1996
- 11) Hamann GF, Liebetau M, Pfefferkorn T, Heiss MM: Successful systemic thrombolysis for carotid stent thrombosis. *Eur Neurol* 48: 37-39, 2002
- 12) Henry M, Polydorou A, Henry I, Polydorou A, Hugel M: Carotid angioplasty under cerebral protection with the PercuSurge GuardWire System. *Catheter Cardiovasc Interv* 61: 293-305, 2004
- 13) Hopkins LN: for the BEACH Investigators: Universal Cerebral Protection: BEACH trial results with the carotid wallstent for carotid artery stenting in high surgical risk patients. *Vascular* 12 [Suppl 2]: S181-182, 2004 (abstract)
- 14) Jeong MH, Owen WG, Staab ME, Srivastava SS, Sangiorgi G, Stewart M, Holmes DR Jr, Schwartz RS: Porcine model of stent thrombosis: platelets are the primary component of acute stent closure. *Cathet Cardiovasc Diagn* 38: 38-43, 1996
- 15) Kurisu K, Manabe H, Ihara T: [Case of symptomatic subacute in-stent thrombosis after carotid angioplasty and stenting for severe carotid stenosis]. *No Shinkei Geka* 35: 1001-1005, 2007 (Jpn, with Eng abstract)
- 16) Leon MB, Baim DS, Popma JJ, Gordon PC, Cutlip DE, Ho KK, Giambartolomei A, Driver DJ, Lasorda DM, Williams DO, Pocock SJ, Kuntz RE: A clinical trial comparing three antithrombotic-drug regimens after coronary-artery stenting. Stent Anticoagulation Restenosis Study Investigators. *N Engl J Med* 3: 1665-1671, 1998
- 17) Moussa I, Oetgen M, Roubin G, Colombo A, Wang X, Iyer S, Maida R, Collins M, Kreps E, Moses JW: Effectiveness of clopidogrel and aspirin versus ticlopidine and aspirin in preventing stent thrombosis after coronary stent implantation. *Circulation* 99: 2364-2366, 1996
- 18) New G, Roubin GS, Iyer SS, Vitek JJ: Carotid artery stenting: rationale, indications, and results. *Compr Ther* 25: 438-445, 1999
- 19) Parodi JC, Rubin BG, Azizzadeh A, Bartoli M, Sicard GA: Endovascular treatment of an internal carotid artery thrombus using reversal of flow: a case report. *J Vasc Surg* 41: 146-150, 2005
- 20) Reimers B, Schluter M, Castriota F, Tubler T, Corvaja N, Cernetti C, Manetti R, Picciolo A, Liistro F, Di Mario C, Cremonesi A, Schofer J, Colombo A: Routine use of cerebral protection during carotid artery stenting: results of a multicenter registry of 753 patients. *Am J Med* 116: 217-222, 2004
- 21) Rothwell PM, Gutnikov SA, Warlow CP; European Carotid Surgery Trialists' Collaboration: Reanalysis of the final results of the European Carotid Surgery Trial. *Stroke* 34: 514-523, 2003
- 22) Roubin GS, New G, Iyer SS, Vitek JJ, Al-Mubarak N, Liu MW, Yadav J, Gomez C, Kuntz RE: Immediate and late clinical outcomes of carotid artery stenting in patients with symptomatic and asymptomatic carotid artery stenosis: a 5-year prospective analysis. *Circulation* 103: 532-537, 2001
- 23) Roubin GS, Yadav S, Iyer SS, Vitek J: Carotid stent-supported angioplasty: a neurovascular intervention to prevent stroke. *Am J Cardiol* 78: 8-12, 1996
- 24) Schneiderman J, Morag B, Gerniak A, Rimon U, Varon D, Seligsohn U, Shotan A, Adar R: Abciximab in carotid stenting for postsurgical carotid restenosis: intermediate results. *J Endovasc Ther* 7: 263-272, 2000
- 25) Setacci C, de Donato G, Setacci F, Chisci E, Cappelli A, Pieraccini M, Castriota F, Cremonesi A: Surgical management of acute carotid thrombosis after carotid stenting: a report of three cases. *J Vasc Surg* 42: 993-996, 2005
- 26) Setacci C, de Donato G, Setacci F, Pieraccini M, Cappelli A, Trovato RA, Benevento D: In-stent restenosis after carotid angioplasty and stenting: a challenge for the vascular surgeon. *Eur J Vasc Endovasc Surg* 29: 601-607, 2005
- 27) Terada T, Tsuura M, Matsumoto H, Masuo O, Yamaga H, Tsumoto T, Itakura T: Results of endovascular treatment of

- internal carotid artery stenosis with a newly developed balloon protection catheter. *Neurosurgery* 53: 617–625, 2003
- 28) Tong FC, Cloft HJ, Joseph GJ, Samuels OB, Dion JE: Abciximab rescue in acute carotid stent thrombosis. *AJNR Am J Neuroradiol* 21: 1750–1752, 2000
- 29) Uren NG, Schwarzscher SP, Metz JA, Lee DP, Honda Y, Yeung AC, Fitzgerald PJ, Yock PG; POST Registry Investigators: Predictors and outcomes of stent thrombosis: an intravascular ultrasound registry. *Eur Heart J* 23: 124–132, 2002
- 30) Vale FL, Fisher WS 3rd, Jordan WD Jr, Palmer CA, Vitek J: Carotid endarterectomy performed after progressive carotid stenosis following angioplasty and stent placement. Case report. *J Neurosurg* 87: 940–943, 1997
- 31) Wehman JC, Holmes DR Jr, Ecker RD, Sauvageau E, Fahrback J, Hanel RA, Hopkins LN: Intravascular ultrasound identification of intraluminal embolic plaque material during carotid angioplasty with stenting. *Catheter Cardiovasc Interv* 68: 853–857, 2006
- 32) White CJ, Iyer SS, Hopkins LN, Katzen BT, Russell ME; BEACH Trial Investigators: Carotid stenting with distal protection in high surgical risk patients: the BEACH trial 30 day results. *Catheter Cardiovasc Interv* 67: 503–512, 2006
- 33) Wholey MH, Wholey M, Bergeron P, Diethrich EB, Henry M, Laborde JC, Mathias K, Myla S, Roubin GS, Shawl F, Theron JG, Yadav JS, Dorros G, Guimaraens J, Higashida R, Kumar V, Leon M, Lim M, Londero H, Mesa J, Ramee S, Rodriguez A, Rosenfield K, Teitelbaum G, Vozzi C: Current global status of carotid artery stent placement. *Catheter Cardiovasc Diagn* 44: 1–6, 1998
- 34) Wholey MH, Wholey M, Mathias K, Roubin GS, Diethrich EB, Henry M, Bailey S, Bergeron P, Dorros G, Eles G, Gaines P, Gomez CR, Gray B, Guimaraens J, Higashida R, Ho DS, Katzen B, Kambara A, Kumar V, Laborde JC, Leon M, Lim M, Londero H, Mesa J, Musacchio A, Myla S, Ramee S, Rodriguez A, Rosenfield K, Sakai N, Shawl F, Sievert H, Teitelbaum G, Theron JG, Vaclav P, Vozzi C, Yadav JS, Yoshimura SI: Global experience in cervical carotid artery stent placement. *Catheter Cardiovasc Interv* 50: 160–167, 2000
- 35) Willfort-Ehringer A, Ahmadi R, Gruber D, Gschwandtner ME, Haumer A, Haumer M, Ehringer H: Arterial remodeling and hemodynamics in carotid stents: a prospective duplex ultrasound study over 2 years. *J Vasc Surg* 39: 728–734, 2004
- 36) Yadav JS, Roubin GS, Iyer S, Vitek J, King P, Jordan WD, Fisher WS: Elective stenting of the extracranial carotid arteries. *Circulation* 95: 376–381, 1997
- 37) Yadav JS, Wholey MH, Kuntz RE, Fayad P, Katzen BT, Mishkel GJ, Bajwa TK, Whitlow P, Strickman NE, Jaff MR, Popma JJ, Snead DB, Cutlip DE, Firth BG, Ouriel K; Stenting and Angioplasty with Protection in Patients at High Risk for Endarterectomy Investigators: Protected carotid-artery stenting versus endarterectomy in high-risk patients. *N Engl J Med* 351: 1493–1501, 2004

Address reprint requests to: Tomoji Takigawa, M.D., Department of Endovascular Neurosurgery, Toranomon Hospital, 2-2-2 Toranomon, Minato-ku, Tokyo 105-8470, Japan.
e-mail: t-tomojy@mx2.harmonix.ne.jp