




Available online at
 ScienceDirect
www.sciencedirect.com

Elsevier Masson France
 EM|consulte
www.em-consulte.com



CASE REPORT

Post-embolization perianeurysmal edema revealed by temporal lobe epilepsy in a case of unruptured internal carotid artery aneurysm treated with bare platinum coils

Œdème périanévrial postembolisation révélé par une épilepsie temporelle dans un cas d'anévrisme carotidien interne non rompu traité par des coils nus : à propos d'un cas et revue de la littérature

L. Vu Dang^a, M. Aggour^a, A. Thiriaux^b, K. Kadziolka^a, L. Pierot^{a,*}

^a Service de radiologie, hôpital Maison-Blanche, CHU de Reims, 45, rue Cognacq-Jay, 51092 Reims cedex, France

^b Service de neurologie, hôpital Maison-Blanche, CHU de Reims, 45, rue Cognacq-Jay, 51092 Reims cedex, France

Available online 24 September 2009

KEYWORDS

Perianeurysmal edema;
Internal carotid artery aneurysm;
Platinum coils;
Embolization

Summary We report the case of a patient with an unruptured internal carotid artery (ICA) aneurysm treated with bare platinum coils. The patient had seizures 1 month after treatment. Postoperative imaging showed perianeurysmal edema and enhancement of the aneurysmal wall. After aneurysm coiling, perianeurysmal edema is an unusual complication that can be asymptomatic or cause symptoms depending on its location. Epilepsy as a clinical presentation of perianeurysmal edema has not previously been reported. Literature about post-embolization perianeurysmal edema is reviewed.

© 2009 Published by Elsevier Masson SAS.

Introduction

In the past decade, endovascular placement of platinum coils into the sac of unruptured aneurysms has become the first-line treatment for prevention of aneurysm rupture [1–3] but it is still a matter of debates [4]. Perianeurysmal edema is a complication following treatment of aneurysms with both bare and modified platinum coils. Fanning et

al. reported an incidence of perianeurysmal edema of 14.3% in unruptured aneurysms [5]. The diagnosis should be considered when neurological symptoms (e.g., visual loss, headache, malaise, dysesthesia, hemiparesis) occur in the days or weeks following embolization [5–15]. We present the first report of a patient who developed epileptic symptoms in relation to perianeurysmal edema.

Case report

A 46-year-old female presented with dysesthesia of the chin. MRI showed two incidental aneurysms, one on the supracli-

* Corresponding author.

E-mail address: lpierot@gmail.com (L. Pierot).

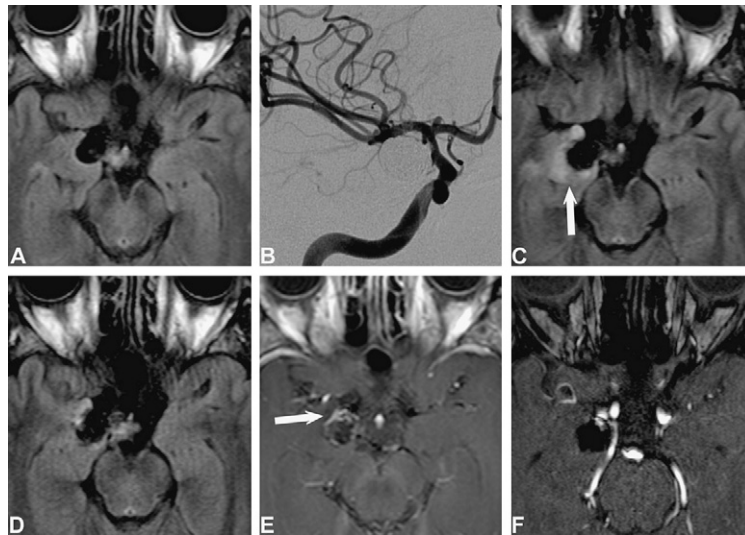


Figure 1 Magnetic resonance imaging and Digital subtraction angiography (DSA). A. FLAIR sequence, before embolization, shows no perianeurysmal edema. B. Angiographic control at the end of the procedure, after placing 12 bare platinum coils, shows complete occlusion of the aneurysm. C. FLAIR sequence, 3 months after embolization, demonstrating the perianeurysmal edema (arrow). D and E. FLAIR sequence and T1 with gadolinium injection, 6 months after embolization, demonstrate marked improvement of perianeurysmal edema but thin wall enhancement (arrow). F. TOF sequence 6 months after embolization reveals a small neck remnant, which is stable compared to the 3-month control.

noid portion of the right ICA (12 mm maximum diameter) and another on the A1 segment of the right anterior cerebral artery (ACA, 2.5 mm maximum diameter). Neither perianeurysmal edema nor spontaneous aneurysmal thrombosis were observed at either location. Due to the aneurysm's size, the right ICA aneurysm was treated by endovascular approach. The aneurysm was occluded with 12 bare platinum coils: five Axiom coils (EV3-Micro Therapeutics, Inc, Irvine, California), five Guglielmi detachable coils (GDC, Boston Scientific Target) and two Microplex coils (Microvention, Inc, Columbia). The final result was complete occlusion with packing of 28.1% (calculated using AngiCalc). During embolization, a thrombus was noted at the aneurysmal neck, and was treated completely by an intra-arterial bolus of 5 mg of abciximab with no neurologic modification. The postoperative period was uneventful.

One month after the procedure, the patient began to experience unpleasant olfactory hallucinations with fear and an ascending thoracic hot flush lasting one to two minutes, several times per week. She once lost consciousness after those sensations, and once experienced an "out of body experience" (autoscopy). A 3T MRI without gadolinium injection, performed 3 months post-embolization, revealed a high signal area on fluid-attenuated inversion recovery (FLAIR) sequence adjacent to the aneurysm in the internal temporal lobe, suggestive of perianeurysmal edema with no significant modification of aneurysmal occlusion (Fig. 1). The patient was referred for neurologic consultation. A 24-hour scalp EEG-video showed right anterior temporal spikes during sleep, confirming right temporal seizures associated with right temporal edema. Treatment with corticoids and antiepileptic drugs (Levetiracetam 1000 mg/day) was started. A follow-up MRI with gadolinium injection performed, 6 months post-embolization showed a significant decrease of the perianeurysmal edema and a thin enhance-

ment of the aneurysmal wall (Fig. 1). Clinical evolution was favorable.

Discussion

Twenty-five cases of de novo perianeurysmal edema after endovascular treatment have been reported, including our case [5–15]. Analysis of these cases shows that perianeurysmal edema is more often observed in patients older than 40 years (19/22). Surprisingly, most aneurysms associated with perianeurysmal edema are unruptured (23/25). The most frequent aneurysmal location associated with post-embolization edema is the ICA (19/24); in most cases, aneurysms are greater than 10 mm (21/24). Finally, post-embolization perianeurysmal edema can be observed after endovascular treatment whether bare platinum coils (10/25) or modified platinum coils (15/25) — including hydrocoils, matrix or cerecyte coils — are used. Perianeurysmal edema can occur from a few hours to several months after treatment and is asymptomatic in approximately one-third of cases. When present, symptoms often have little specificity (e.g., headache, malaise, paresis, dysesthesia). The most frequent symptom, visual loss, is encountered after the treatment of supraclinoid ICA aneurysms. Our case is the first report of epilepsy as the clinical presentation of perianeurysmal edema. Steroid therapy is used in 13/25 cases with near-complete resolution of the patients' symptoms and marked improvement of the perianeurysmal edema on MRI in most cases. Hydrocephalus and aseptic meningitis are not frequently associated with perianeurysmal edema (4/25 and 1/25 cases, respectively).

Several mechanisms have been proposed to explain perianeurysmal edema. As it is frequently associated with aneurysm wall enhancement, which is quite frequent (31.5%), it may represent a normal healing response and is

probably explained by the inflammatory changes detailed in histological reports [5]. This inflammatory response can be exaggerated in some cases, leading to perianeurysmal edema. The improvement of clinical symptoms and MR images under steroid therapy is in favor of this hypothesis. In other cases, perianeurysmal is observed several months after aneurysm treatment, and is generally associated with massive recurrence [5,8]. In these cases, edema is probably related to the water-hammer effect transmitted to the brain parenchyma through the coil mesh and the aneurysmal wall. Finally, coiling may lead to an acute, slight increase of aneurysm diameter, and mechanical irritation of adjacent structures by increasing the mass effect [11,13]. Immediately after endovascular treatment with coils, thrombus formation begins within the aneurysm due to absent or turbulent flow and can be associated with secondary expansion of the aneurysm sac [6]. The facts that edemas occur mostly in aneurysms greater than 10 mm and that perianeurysmal edema is sometimes not modified by steroid therapy support the likelihood of this mechanism [9,10,14].

The treatment options for post-embolization perianeurysmal edema depend on symptoms and pathogenesis. Corticoid therapy is useful in case of inflammation. Endovascular coiling or surgical clipping are indicated if the edema developed due to regrowth of the aneurysm recanalization. Conservative management is proposed if the patient's symptoms are tolerable and not progressive. In our case, epilepsy was successfully treated with antiepileptic drugs.

Conclusion

Our case shows that epilepsy can be the revealing symptom of perianeurysmal edema after aneurysmal coiling. This case also confirms that bare platinum coils can be responsible for perianeurysmal edema as surface-modified coils.

References

- [1] Pierot L, Spelle L, Vitry F. Immediate clinical outcome of patients harboring unruptured intracranial aneurysms treated by endovascular approach, results of the ATENA study. *Stroke* 2008;39:2497–504.
- [2] Anxionnat R, Bracard S, Lebedinsky A, Iancu D, Roca F, Picard L. A survey of the management of unruptured intracranial aneurysms as practised by French neuroradiological and neurosurgical teams. *J Neuroradiol* 2008;35:90–8.
- [3] Spelle L, Pierot L. Endovascular treatment of non-ruptured intracranial aneurysms: critical analysis of the literature. *J Neuroradiol* 2008;35:116–20.
- [4] Raymond J, Roy D, Weill A, Guilbert F, Nguyen T, Molyneux AJ, et al. Unruptured intracranial aneurysms: their illusive natural history and why subgroup statistics cannot provide normative criteria for clinical decisions or selection criteria for a randomized trial. *J Neuroradiol* 2008;35:210–6.
- [5] Fanning NF, Willingsky RA, ter Brugge KG. Wall enhancement, edema, and hydrocephalus after endovascular coil occlusion of intradural cerebral aneurysms. *J Neurosurg* 2008;108:1074–86.
- [6] White JB, Cloft HJ, Kallmes DF. But did you use Hydrocoil? Perianeurysmal edema and hydrocephalus with bare platinum coils. *AJNR Am J Neuroradiol* 2008;29:299–300.
- [7] Pickett GE, Laitt RD, Herwadkar A, Hughes DG. Visual pathway compromise after hydrocoil treatment of large ophthalmic aneurysms. *Neurosurgery* 2007;61:873–4.
- [8] Horie N, Kitagawa N, Morikawa M, Tsutsumi K, Kaminogo M, Nagata I. Progressive perianeurysmal edema induced after endovascular coil embolization. Report of three cases and review of the literature. *J Neurosurg* 2007;106:916–20.
- [9] Turner RD, et al. Delayed visual deficits and monocular blindness after endovascular treatment of large and giant paraophthalmic aneurysms. *Neurosurgery* 2007;61:873–4.
- [10] Schmidt GW, Oster SF, Golnik KC, et al. Isolated progressive visual loss after coiling of paraclinoid aneurysms. *AJNR Am J Neuroradiol* 2007;28:1882–9.
- [11] Stracke CP, Krings T, Moller-Harmann W, Mahdavi A, Klug N. Severe inflammatory reaction system after endovascular treatment of a supraophthalmic aneurysm with bioactive coils. *AJNR Am J Neuroradiol* 2007;28:1401–2.
- [12] Meyers PM, Lavine SD, Fitzsimmons BF, et al. Chemical meningitis after cerebral aneurysm treatment using two-second generation aneurysm coils: report of two cases. *Neurosurgery* 2004;55:1222.
- [13] Marden FA, Putman CM. Perianeurysm edema with second generation bioactive coils. *Surg Neurol* 2008;69:627–32.
- [14] Bendszus M, Solymosi L. Cerecye coils in the treatment of intracranial aneurysms: a preliminary clinical study. *AJNR Am J Neuroradiol* 2006;27:2053–7.
- [15] Craven I, Patel UJ, Gibson A, Coley SC. Symptomatic perianeurysmal edema following bare platinum embolization of a small unruptured cerebral aneurysm. *AJNR Am J Neuroradiol* 2009, doi:10.3174/ajnr.A1643.