

# Multiple Traumatic Intracranial Aneurysms Presenting as a Subacute Hemorrhagic Mass Lesion 14 Years After Trauma

Jose E. Cohen, MD, PhD, Savvas Grigoriadis, MD, PhD, and John Moshe Gomori, MD, PhD

**T**raumatic intracranial aneurysms (TICA) are rare and constitute <1% of all intracranial aneurysms.<sup>1</sup> However, the real incidence of these lesions is uncertain. Early angiography may miss delayed aneurysm formation, and repeat angiography is indicated in selected cases.<sup>2-4</sup> Because unenhanced computed tomography (CT) has replaced cerebral angiography as the neuroradiological procedure of choice in the setting of acute head injury, the early diagnosis of this entity may have become less common.

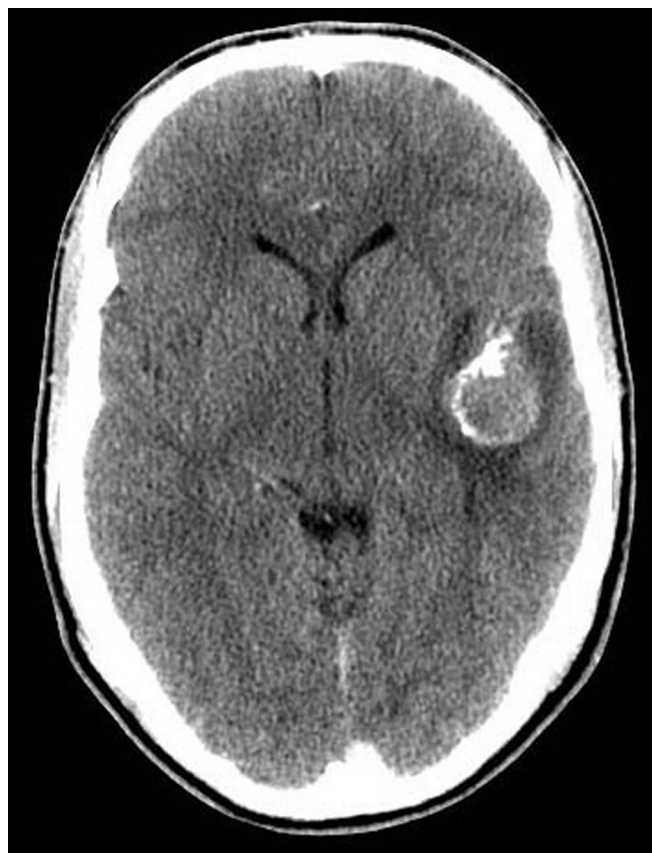Most of the aneurysms are associated to closed head injury and penetrating head injury, but they can also be caused by iatrogenic arterial injury during a variety of surgical procedures.<sup>5-7</sup>

Such aneurysms are usually located distally in small-calibered arteries, at nonbranching points, and have a fragile wall that is prone to rupture.<sup>8,9</sup> They usually present with subarachnoid, intraparenchymal, subdural, or intraventricular hemorrhage.<sup>3,4,8</sup> Infrequently, they may be diagnosed at routine head examinations for penetrating trauma close to major intracranial arteries. We present a case of adjacent TICA secondary to a penetrating injury, presenting with a subacute pseudotumoral mass effect lesion, 14 years after the trauma. The occurrence of adjacent TICA has not been reported previously, and a subacute presentation is exceptional.

## CASE REPORT

A 22-year-old man with no history of drug abuse was admitted to an outside institution with a history of two recent episodes of tonic-clonic generalized seizures. At admission to our institution, the patient was alert and oriented, presenting a moderate oppressing headache and a slight motor dysphasia. CT showed a hyperdense left opercular mass with surrounding edema and partial peripheral ring of calcification (Fig. 1). The patient received glucocorticoids, analgesics, and prophylactic diphenylhydantoin with improvement of the dysphasia. He admitted having minor difficulties in intellectual

tasks in the last 3 months, which he attributed to excess of work. MRI disclosed an onion-like layered hemorrhagic collection with a dilated branch of the middle cerebral artery anterior to it and with a peripheral rim of enhancement and significant surrounding edema (Fig. 2, A–D). Selective angiography revealed the presence of two adjacent pseudoaneurysms located at the opercular segment of the precentral and angular branches of the middle cerebral artery (Fig. 3, A and B). Both lesions were irregular, without a definite neck, and had contrast media stagnation and showed complete involvement of the parent vessel. The patient underwent neurosurgical aneurysmal trapping. On careful questioning, the patient recalled hitting his left head against the sharp corner of the



**Figure 1.** Unenhanced axial brain CT reveals a heterogeneous intraaxial mass effect, with multiple calcified and bleeding foci, surrounded by digitiform edema.

Submitted for publication August 13, 2006.

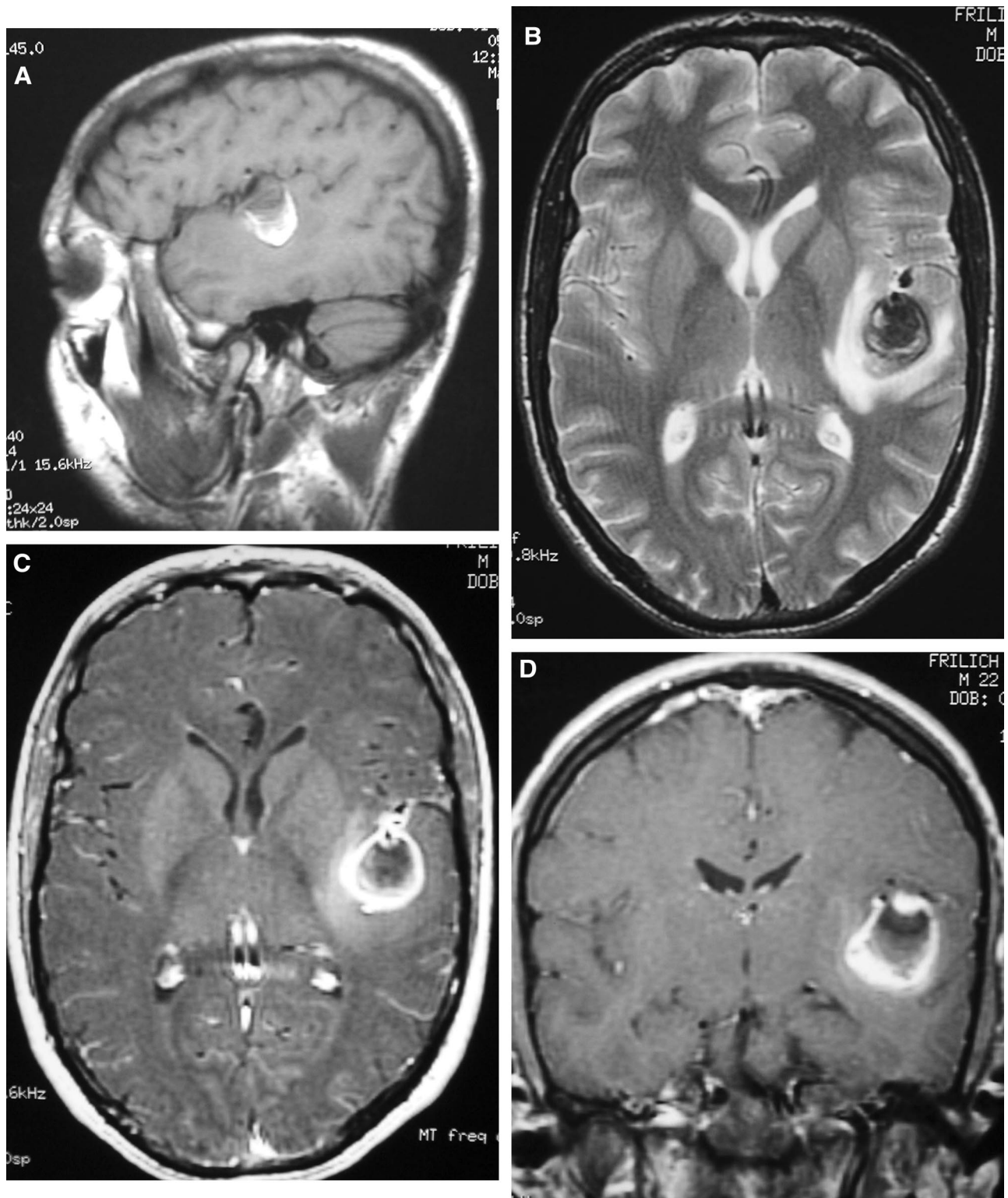
Accepted for publication December 14, 2006.

Copyright © 2009 by Lippincott Williams & Wilkins

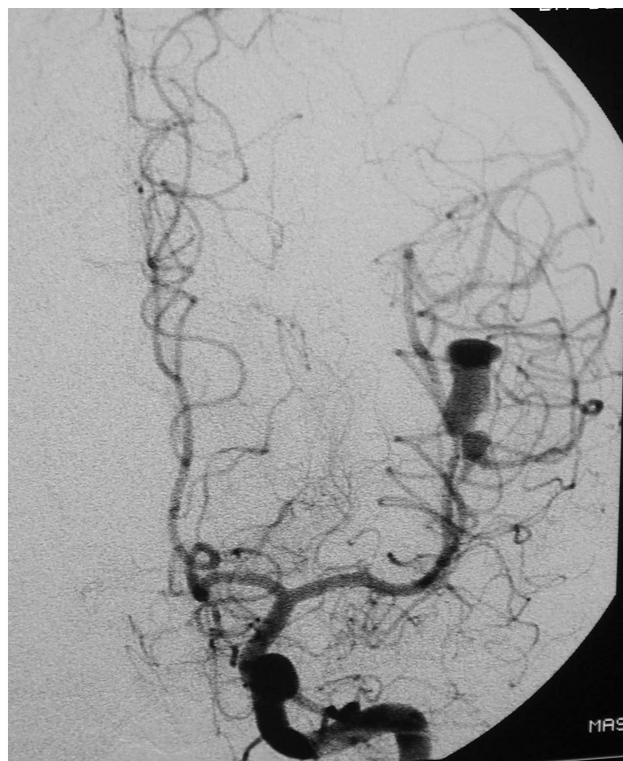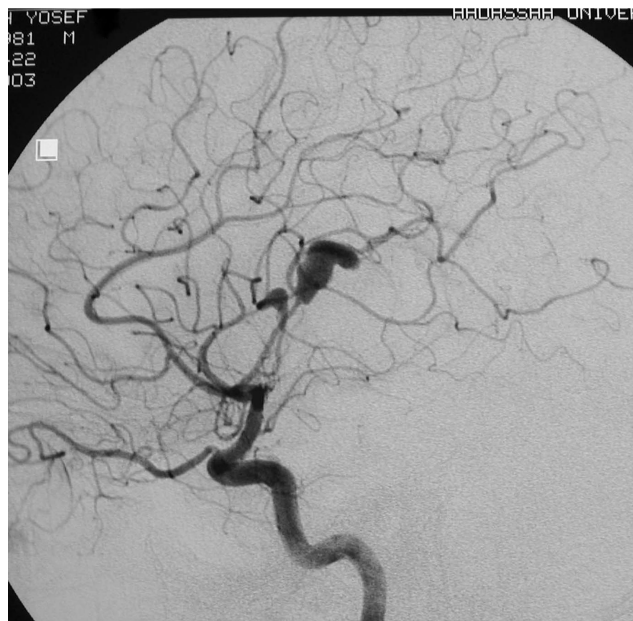From the Hadassah Stroke Center (J.E.C., S.G., J.M.G.), Hadassah University Hospital; Department of Neurosurgery (J.E.C., S.G.), Hadassah University Hospital; Department of Radiology (J.M.G.), Hadassah University Hospital; and Division of Endovascular Neurosurgery and Interventional Neuroradiology (J.E.C., S.G., J.M.G.), Hadassah University Hospital, Jerusalem, Israel.

Address for reprints: Savvas Grigoriadis, MD, PhD, Kiryat Hadassah, Jerusalem, 91120, Israel; email: neurosavvas@yahoo.gr.

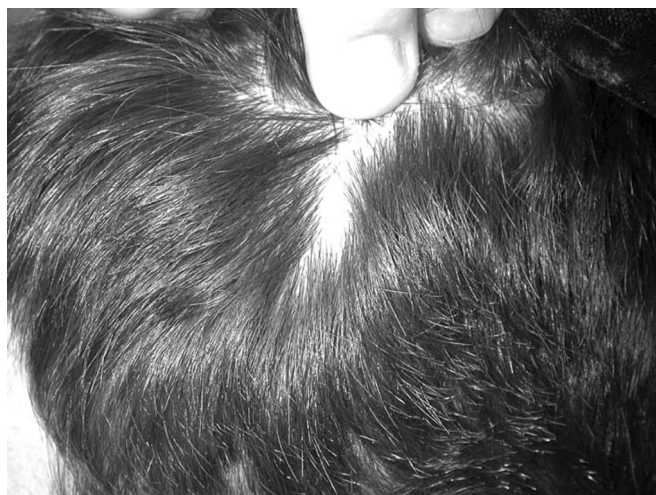DOI: 10.1097/TA.0b013e318034205e



**Figure 2.** Parasagittal unenhanced T1-weighted MRI shows layered peripheral hyperintensity of methemoglobin in a left temporal hematoma. (B) Axial T2-weighted image shows acute and subacute intracellular deoxyhemoglobin and methemoglobin layers of the hematoma with a fusiform enlargement of a middle cerebral artery branch anteriorly. (C and D) Corresponding axial and coronal enhanced T1-weighted MRI shows peripheral enhancement of the hematoma and of the fusiform arterial enlargement.



**Figure 3.** Anteroposterior and lateral left internal carotid angiographic views demonstrate pseudoaneurysms arising from adjacent MCA opercular branches.



**Figure 4.** Photograph of the scalp scar with a hairless spot.

living room table before 14 years, which was not treated medically. Examination of the scalp overlying the aneurysms and the site of previous trauma revealed a focal alopecic scar (Fig. 4). Reexamination of the head CT with bone windows, did not reveal any residual bony abnormality.

### DISCUSSION

TICA are a rare clinical entity, frequently presenting with rupture, often with fatal hemorrhage.<sup>2,3</sup> They present

between a few hours to as long as 10 years after the trauma, with a mean time to presentation of 2 to 3 weeks.<sup>9–12</sup> The trauma-diagnosis interval of 14 years in the presented case is exceptional, and so is the presence of multiple adjacent located TICA presenting as a subacute pseudotumoral lesion.

Because CT has largely replaced angiography in the initial evaluation of penetrating brain injury, early diagnosis of TICA may have become less frequent. TICA should be suspected in head injured and postoperative patients with delayed intracranial hemorrhage, unexplained major arterial bleeding during hematoma evacuation, significant posttraumatic subarachnoid hemorrhage, facio-orbito-pterional injuries, and the presence of penetrating fragments, especially if they cross midline or transverse into another dural compartment.<sup>3,9–11,13</sup> In this case, the patient referred an episode of nonhospitalized head trauma against a sharp table corner. The “minor scalp bleeding” was not evaluated by any doctors and no radiologic evaluation was performed. The site of the scalp wound is still visible as a hairless left temporal scar as shown in Figure 4. The sharp table corner most probably damaged two or more of the opercular middle cerebral artery branches, leading to the formation of the traumatic aneurysms. It has been suggested that dissection is the underlying cause of spontaneous fusiform aneurysms of the middle cerebral artery,<sup>14</sup> which may be the case in our patient as well.

Although angiography remains the best diagnostic procedure to detect TICA, a single negative angiogram does not rule out the possibility of a delayed aneurysmatic appearance. This is explained by the fact that traumatic aneurysms may

heal spontaneously, change in size over time or rupture. The CT and MRI in this case disclosed a subacute intra-axial hemorrhagic pseudotumoral mass with chronic calcifications and significant perilesional edema.

Magnetic resonance angiography has been found valuable in screening patients at risk for cerebral aneurysms, such as those with polycystic kidney disease and close relatives with aneurysms. However, this noninvasive tool may not be adequate for patients with traumatic intracranial changes that may mask the detection of TICA, e.g., with metallic foreign bodies and hemorrhages.

Multidetector helical CT scanners are a promising alternative for the screening of traumatic penetrating head injuries.<sup>14–16</sup> However, its definite role in TICA detection has yet to be established.

### CONCLUSION

TICA may present as a subacute hemorrhagic mass long after “inconsequential” trauma. One must view hemorrhagic “mass” lesions with suspicion before exploration. If in doubt, angiography should be considered.

### REFERENCES

1. Benoit BG, Wortzman G. Traumatic cerebral aneurysms clinical features and natural history. *J Neurol Neurosurg Psychiatry*. 1973;36:127–138.
2. Haddad FS, Haddad GF, Taha J. Traumatic intracranial aneurysms caused by missiles: their presentation and management. *Neurosurgery*. 1997;28:1–7.
3. Aarabi B. Management of traumatic aneurysms caused by high velocity missile head wounds. *Neurosurg Clin North Am*. 1995;6:775–797.
4. Amirjamshidi A, Rahmat H, Abbassioun K. Traumatic aneurysms and arteriovenous fistulas of intracranial vessels associated with penetrating head injuries occurring during war: principles and pitfalls in diagnosis and management—a survey of 31 cases and review of the literature. *J Neurosurg*. 1996;84:769–780.
5. Horowitz MB, Kopitnik TA, Landreneau F, et al. Multidisciplinary approach to traumatic intracranial aneurysms secondary to shotgun and handgun wounds. *Surg Neurol*. 1999;51:31–41.
6. Uzan M, Cantasdemir M, Seckin MS, et al. Traumatic intracranial carotid tree aneurysms. *Neurosurgery*. 1998;43:1314–1320.
7. Raymond J, Hardy R, Czepko R, Roy D. Arterial injuries in transsphe-noidal surgery for pituitary adenoma: the role of angiography and endovascular treatment. *AJNR Am J Neuroradiol*. 1997;18:655–665.
8. Holmes B, Harbaugh RE. Traumatic intracranial aneurysms: a contemporary review. *J Trauma*. 1993;35:855–860.
9. Vascular complications of penetrating head injury. *J Trauma*. 2001;51: S26–S28.
10. Buckingham M, Crone KR, Ball WS, Tomsick TA, Berger TS, Tew JM Jr. Traumatic intracranial aneurysms in childhood: two cases and a review of the literature. *Neurosurgery*. 1988;22:398–408.
11. Fleisher AS, Patton JM, Tindall GT. Cerebral aneurysms of traumatic origin. *Surg Neurol*. 1975;4:233–239.
12. Lath R, Vaniprasad A, Kat E, Brophy BP. Traumatic aneurysm of the callosomarginal artery. *J Clin Neurosci*. 2002;9:466–468.
13. Ventureyra EC, Higgins MJ. Traumatic intracranial aneurysms in childhood and adolescence, case reports and review of the literature. *Childs Nerv Syst*. 1994;10:361–379.
14. Day AL, Gaposchkin CG, Yu CJ, Rivet DJ, Dacey RG Jr. Spontaneous fusiform middle cerebral artery aneurysms: characteristics and a proposed mechanism of formation. *J Neurosurg*. 2003;99:228–240.
15. Forbes K, Pitt A, Walker MT, et al. CT angiography: a tool for managing cerebral aneurysms? *BNI Q*. 2001;17:28–36.
16. White PM, Wardlaw JM, Easton V. Can noninvasive imaging accurately depict intracranial aneurysms? A systematic review. *Radiology*. 2000; 217:361–370.