



Images in Neuroscience: Question

Rapidly resolving pure motor hemiparesis in a healthy young male

Gyanendra Kumar *, Chetan Rasiklal Soni, Pradeep Kumar Sahota

Department of Neurology, University of Missouri, D047 1 Hospital Drive, Columbia, Missouri 65212, USA

1. Clinical background

A 45-year-old, right handed Caucasian farmer who did not smoke, or have hypertension or diabetes, developed left-sided arm and leg weakness during strenuous physical activity. He had been working in the field on a hot day.

His blood pressure was 144/89 mm Hg, heart rate 100 beats per minute, and respiratory rate, 17 per minute. Neurologically, a pure motor left hemiparesis was present. Other systemic examination was unremarkable.

His hematological and complete metabolic profiles were within normal limits. His drug screen was positive for amphetamines and caffeine. The vasculitic and hypercoagulability work-up were negative, and his electrocardiogram, transthoracic and transesophageal echocardiograms were normal.

The pure motor hemiparesis rapidly improved and resolved within the following 2 days. His MRI (diffusion-weighted and apparent diffusion coefficient), magnetic resonance (MR) angiogram, and MR venogram are shown in Fig. 1.

2. What is the diagnosis?

- A. Dural venous sinus thrombosis
- B. Embolic infarct
- C. Amphetamine-related stroke

Answer on page 1513.

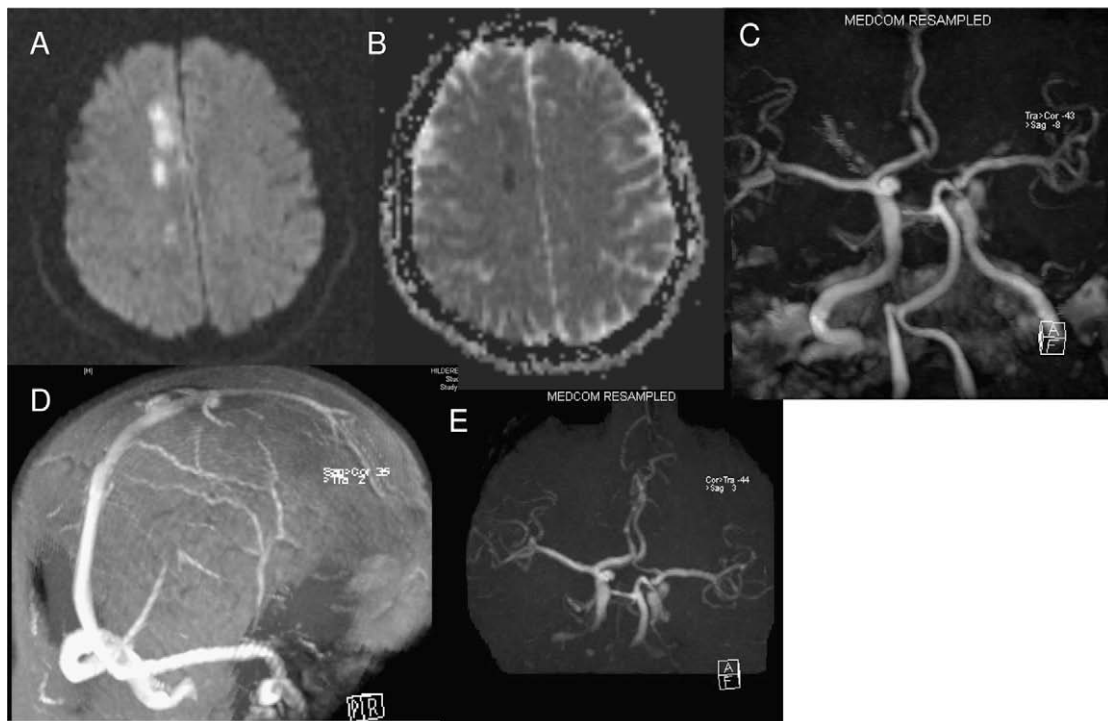


Fig. 1. (A) An axial MRI diffusion-weighted image. (B) An apparent diffusion coefficient MRI. (C) A magnetic resonance (MR) angiogram of the brain. (D) An MR venogram. (E) A follow-up MR angiogram.

* Corresponding author. Tel.: +1 573 823 2915; fax: +1 573 884 4249.
E-mail address: kumargy@health.missouri.edu (G. Kumar).