

Delayed cerebral thrombosis after initial good recovery from pneumococcal meningitis



E.S. Schut, MD
M.C. Brouwer, MD
J. de Gans, PhD
S. Florquin, PhD
D. Troost, PhD
D. van de Beek, PhD

Address correspondence and reprint requests to Dr. Diederik van de Beek, Department of Neurology, Center of Infection and Immunity Amsterdam (CINIMA), Academic Medical Center, University of Amsterdam, PO Box 22660, 1100 DD Amsterdam, the Netherlands
d.vandebeek@amc.uva.nl

ABSTRACT

Objective: To report an unusual clinical course in 6 patients with community-acquired acute bacterial meningitis and to compare clinical features with cases reported in the literature.

Methods: Case series from Dutch hospitals from 2003 to 2008.

Results: Five out of six patients were male, age ranged from 30 to 73 years (mean age, 47 years). All patients had pneumococcal meningitis, received adjunctive dexamethasone treatment on admission, and made a good or excellent initial recovery. After 7 to 19 days, patients suddenly deteriorated, developing headache, fever, a decreased level of consciousness, brainstem signs, or hemiparesis. Imaging studies showed infarctions involving the thalamus or brainstem in all patients. Repeated lumbar puncture showed a pleocytosis, but CSF cultures were sterile. Five patients were treated with high-dose steroids on deterioration. Outcome was poor: 4 patients died and 2 remained disabled. Autopsies, performed in 2 patients, showed infarctions predominantly involving the posterior circulation territory, thrombosis in penetrating arteries, but no evidence of vasculitis. We identified 5 meningitis cases with delayed vasculopathy in the literature, but these patients did not exactly resemble the clinical course of our patients.

Conclusions: Delayed cerebral thrombosis may occur in patients with excellent recovery from pneumococcal meningitis. All patients were treated initially with adjunctive dexamethasone therapy, suggesting a dexamethasone-associated effect. Pathology suggests an immunologic reaction targeting cerebral blood vessels. *Neurology*® 2009;73:1988-1995

GLOSSARY

GCS = Glasgow Coma Scale; **ICU** = intensive care unit; **TGF- β RII** = transforming growth factor beta receptor II.

Cerebrovascular complications are common in bacterial meningitis.^{1,2} Cerebral infarction is especially common in patients with pneumococcal meningitis and typically develops in the first few days of disease when CNS inflammation is most severe.^{3,4} In a retrospective analysis of 87 patients with pneumococcal meningitis admitted in a neurologic intensive care unit (ICU) between 1984 and 2002, arterial cerebrovascular complications were detected in 19 patients (22%); CT-, magnetic resonance-, or digital subtraction angiography was performed in 17 of these patients and were compatible with vasculitis in 11 patients.³ A rare cerebrovascular complication of meningitis is delayed cerebral vasculitis or vasculopathy. The etiology is unknown and few cases have been described.⁵⁻⁹ We recently encountered 6 patients with a devastating delayed vasculopathy complicating bacterial meningitis, which we will refer to as delayed cerebral thrombosis. Herein, we describe these cases with this new type of vasculopathy complicating bacterial meningitis, review the literature, and discuss the possible underlying mechanism and treatment options.

CASE REPORTS **Case 1.** A 38-year-old man with otitis presented with headache, fever, and altered consciousness. Neurologic examination showed neck stiffness and decreased level of consciousness (Glasgow Coma Scale

Editorial, page 1945

e-Pub ahead of print on November 4, 2009, at www.neurology.org.

From the Departments of Neurology (E.S.S., M.C.B., J.d.G., D.v.d.B.), Pathology (S.F.), and Neuropathology (D.T.), Center of Infection and Immunity Amsterdam (CINIMA), Academic Medical Center, Amsterdam, the Netherlands.

Supported by the Netherlands Organization for Health Research and Development (NWO-Veni grant 2006 to D.v.d.B.) and the Academic Medical Center (AMC fellowship to D.v.d.B.).

Disclosure: The authors report no disclosures.

Table 1 Characteristics of 6 patients with delayed cerebral thrombosis complicating bacterial meningitis

	Case 1 (2003)	Case 2 (2004)	Case 3 (2004)	Case 4 (2008)	Case 5 (2008)	Case 6 (2008)
Sex, age, y	M, 38	M, 46	M, 55	M, 73	F, 30	M, 40
Admission GCS	E4M4V1	E4M6V4	E2M5V2	E3M5V1	E4M6V4	E1M3V1
Neurologic deficits	Aphasia	No	No	Aphasia, gaze deviation	No	No
CSF WBC, cells/mm ³	1,787	87	NP	17,700	2,000	80
CSF protein, mg/dL	101	610	NP	526	290	600
CSF glucose, mg/dL	61	<1.8	NP	<1.8	<1.8	<1.8
Causative organism	<i>S pneumoniae</i>	<i>S pneumoniae</i>	<i>S pneumoniae</i>	<i>S pneumoniae</i>	<i>S pneumoniae</i>	<i>S pneumoniae</i>
Dexamethasone	10 mg every 4 h, day 1 through 4	10 mg every 4 h, day 1 through 4	10 mg every 4 h, day 1 through 4	10 mg every 4 h, day 1 through 4	10 mg every 4 h, day 1 through 4	10 mg every 4 h, day 1 through 4
Cranial CT	Otitis	Normal	Normal	Normal	Normal	Normal
Status after first week	Good recovery	Excellent recovery	Excellent recovery	Good recovery	Excellent recovery	Good recovery
Deterioration second week	Day 11: fever, headache, coma	Day 10: fever, headache, coma	Day 11: fever, hemiparesis, coma	Day 7: fever, seizures, brainstem signs, coma	Day 13: fever, headache, coma, hemiparesis	Day 19: fever, coma
CSF WBC 2nd LP, cells/mm ³	5,933	NP	166	500	1,100	1,080
CSF protein 2nd LP, mg/dL	774	NP	170	296	130	239
CSF glucose 2nd LP, mg/dL	<1.8	NP	25	72	29	59
CSF culture, 2nd LP	Negative	NP	Negative	Negative	Negative	Negative
MRI	Infarction left parietal lobe, bilateral thalamus, brainstem	Infarction thalamus bilaterally	Infarction basal ganglia, brainstem	Infarction left frontal lobe, brainstem	Infarction left corona radiata, right thalamus, brainstem	Infarction left basal ganglia, medulla, cerebellum
Treatment	Ceftriaxone, metronidazole, dexamethasone	Ceftriaxone, prednisolone	Cefotaxime	Ceftriaxone, prednisolone	Penicillin, dexamethasone	Ceftriaxone, prednisolone
Outcome	Death, day 32	Survival, moderately disabled	Death, day 19	Death, day 25	Death, day 22	Survived, severely disabled

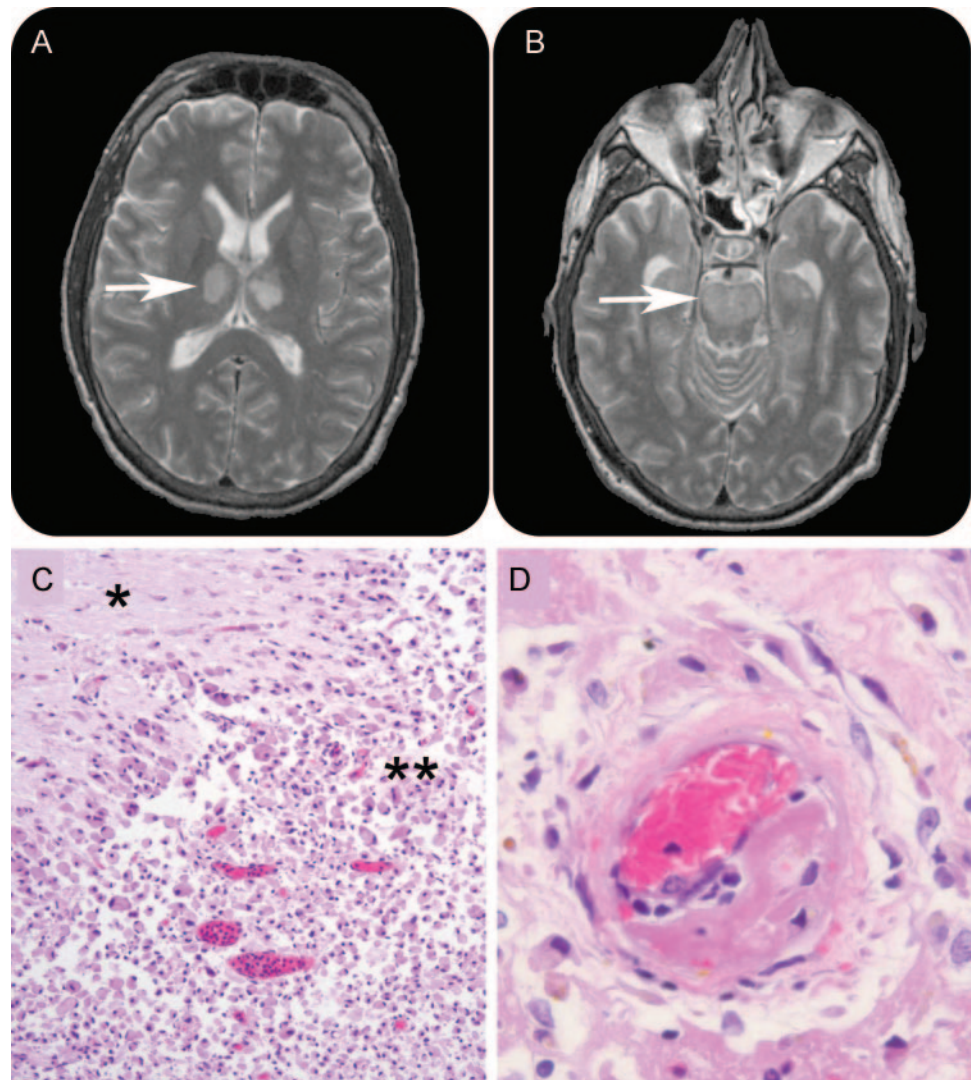
Second CSF of patient 1 was obtained from an external ventricular catheter.

GCS = Glasgow Coma Scale; WBC = white blood cells; NP = not performed; LP = lumbar puncture.

[GCS] score, E4M5V1). Treatment with penicillin and dexamethasone was started and cranial CT showed no abnormalities. Subsequent CSF examination yielded 1,787 leukocytes/mm³ and a high protein and low glucose level (table 1). CSF gram stain showed gram-positive diplococci. Cultures of blood and CSF yielded *Streptococcus pneumoniae* sensitive to penicillin. On day 2, aphasia and a mild right hemiparesis were noted. Cranial MRI showed a left parietal T2 hyperintense lesion with restricted diffusion consistent with infarction. He showed excellent recovery. On day 10, he was fit for discharge. However, on day 11, he developed progressive headache and deteriorated into coma within hours. Cranial CT now showed slight communicating hydrocephalus and the previously identified left parietal infarct. An external lumbar drain was placed and CSF examination showed 5,933 leukocytes/mm³ (100% granulocytes). CSF gram stain and cultures yielded no bacteria. Therapy was restarted with ceftriaxone, metro-

nidazole, and dexamethasone. Cranial MRI showed infarction of the thalamus bilaterally (figure 1A), midbrain, pons (figure 1B), and medulla oblongata. Despite supportive care, no neurologic improvement occurred. Care was withdrawn on day 32 and the patient died. Autopsy showed areas of infarction involving the left parietal lobe, and thalamus, midbrain, pons (figure 1C), and medulla oblongata bilaterally. Macroscopically, the basilar artery was normal, but perforating arteries supplying the brainstem showed focal thrombi, without evidence of vasculitis (figure 1D).

Case 2. A 46-year-old man presented with headache and a temperature of 38.6 °C. Neurologic examination showed neck stiffness, decreased attention span, and disorientation. No other neurologic abnormalities were found. Cranial CT was normal. Community-acquired bacterial meningitis was suspected and treatment with ceftriaxone and dexa-

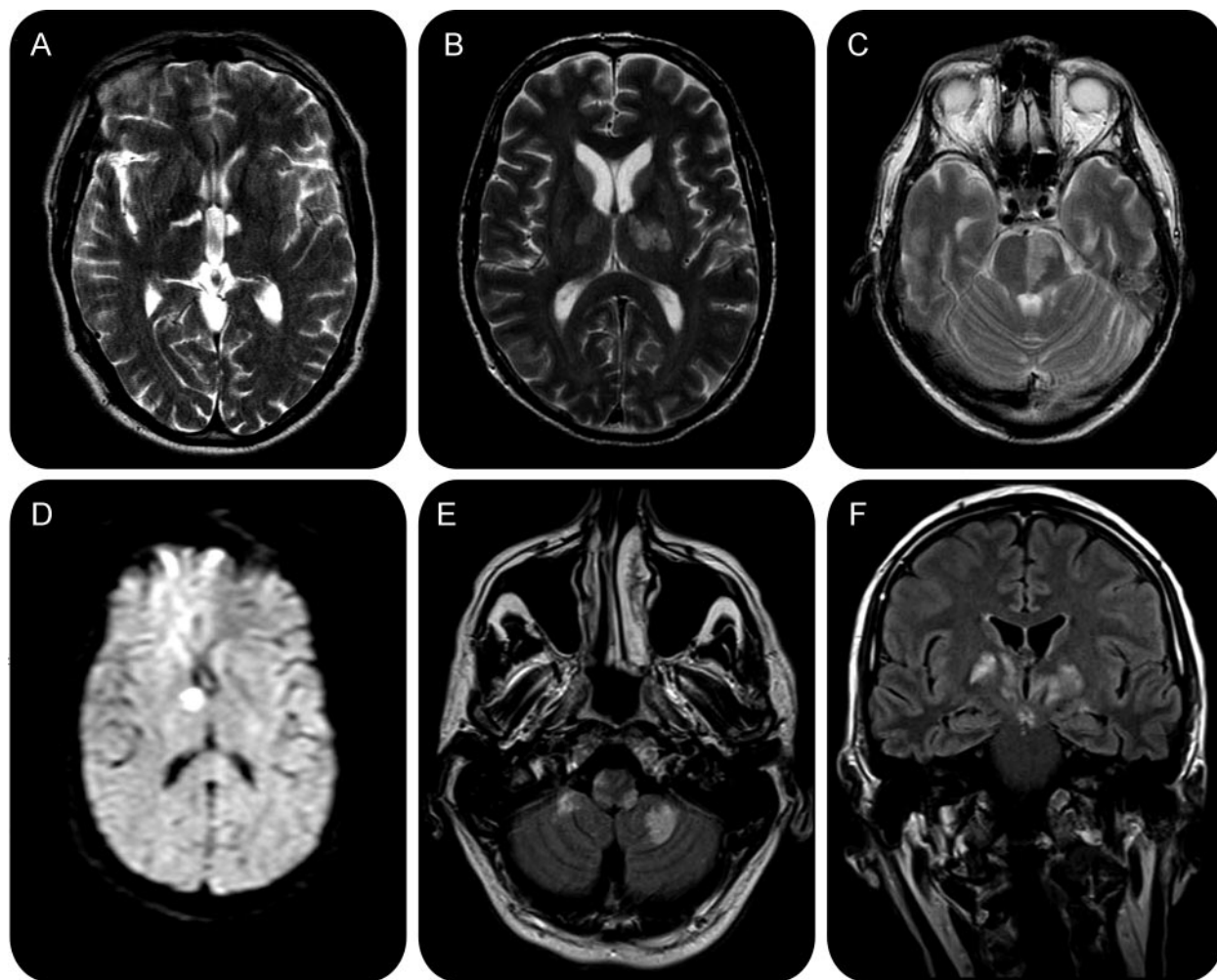


Axial T2-weighted MRI showing bilateral thalamic (A, arrow) and pontine (B, arrow) infarcts in case 1. Recent pontine infarction (C, hematoxylin and eosin, magnification 100 \times). A single asterisk indicates normal transverse pontine fibers; a double asterisk indicates infarction. Perforating brainstem artery with subtotal stenosis caused by thrombus (D, hematoxylin and eosin, magnification 400 \times). Vessel wall shows no evidence of vasculitis.

methasone was started. CSF examinations showed 87 leukocytes/mm³ (91% monocytes) and high protein and low glucose levels. CSF gram stain revealed gram-positive diplococci and culture of blood and CSF yielded *S pneumoniae*, sensitive to penicillin. The patient made a full recovery in the next few days. However, on day 10, his level of consciousness suddenly decreased and he developed a left hemiplegia. Cranial MRI showed bilateral thalamic infarctions (figure 2A). He was immediately treated with prednisone 60 mg daily and ceftriaxone. His condition stabilized and his level of consciousness slowly improved. On day 84, he was discharged to a rehabilitation facility. On discharge, he had marked abulia and left hemiparesis. After several months of rehabilitation, he was able to return home. Cur-

rently, he is ambulating but unable to resume his previous occupation.

Case 3. A 55-year-old man with a history of idiopathic epilepsy presented with fever, diarrhea, and altered consciousness following 1 week of cough and general malaise. He had a temperature of 41.3 °C and was disorientated. Pneumonia was diagnosed and he was intubated because of respiratory failure. Treatment with ceftriaxone was initiated and blood cultures yielded *S pneumoniae*. On day 2, a neurology consultation was requested. He had a GCS score of E4M5Vtub and there was neck stiffness. Cranial CT showed no abnormalities. Nevertheless, lumbar puncture was deferred and dexamethasone was started for 4 days. On day 10, he was awake, alert,

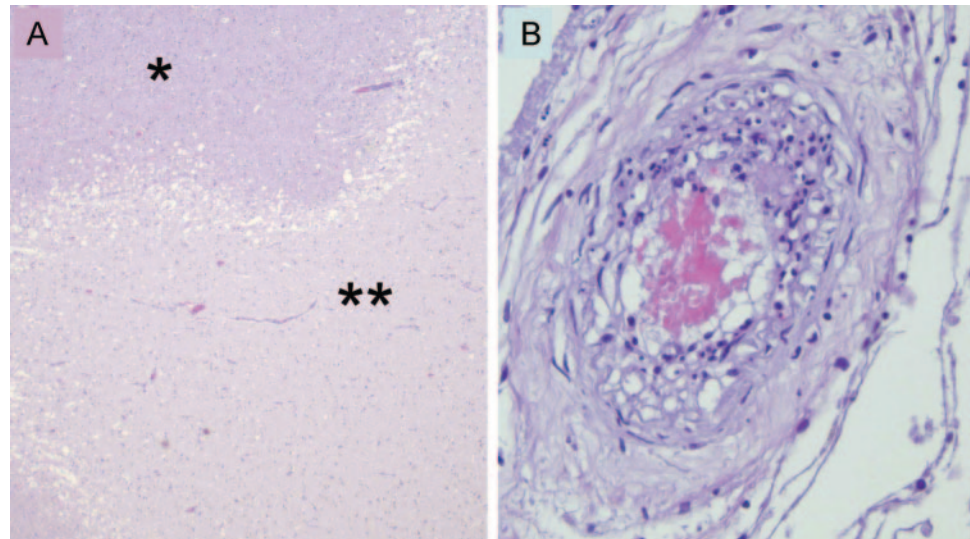


Axial T2-weighted MRI showing bilateral thalamic infarcts in case 2 (A). Axial T2-weighted MRI showing infarction of both thalami, left internal capsule (B), and left pons (C) in case 3. Axial diffusion-weighted MRI showing infarct of the right thalamus in case 5 (D). Axial (E) and coronal (F) fluid-attenuated inversion recovery images showing infarction of medulla oblongata, cerebellum (E), and basal ganglia bilaterally (F) in case 6.

and oriented, and ready for discharge. However, on day 11, fever recurred and the patient rapidly became unresponsive. A cranial CT showed no abnormalities. A lumbar puncture revealed 166 leukocytes/mm³ (98% granulocytes), elevated protein, and normal glucose levels, and ceftriaxone was restarted. CSF gram stain and cultures of blood and CSF revealed no bacteria. Cranial MRI showed widespread infarcts, involving the thalamus bilaterally, left internal capsule (figure 2B), and left pons (figure 2C). Transesophageal echocardiography was unremarkable. On day 19, care was withdrawn and the patient died. No autopsy was performed.

Case 4. A 73-year-old man with a 2-day history of otitis presented with headache, altered consciousness, and a temperature of 39 °C. Neurologic examination showed neck stiffness, global aphasia, and gaze deviation to the left. Treatment with penicillin and dexamethasone was started. CSF examination yielded

17,700 leukocytes/mm³ (100% granulocytes), high protein, and low glucose levels. CSF gram stain showed gram-positive diplococci and cultures of blood and CSF yielded *S pneumoniae*, sensitive to penicillin. Cranial CT scan showed no abnormalities. Over the next few days the patient improved. On day 6, he was awake, alert, and ambulating. However, on day 7, fever recurred and he developed gait impairment. A urinary tract infection was diagnosed and treatment with ciprofloxacin was started. On day 8, his level of consciousness started to fluctuate, with intermittent dysconjugate eye movements. Cranial CT scans again showed no abnormalities. A second lumbar puncture yielded 500 leukocytes/mm³ (90% granulocytes); CSF gram stain and cultures remained negative. On day 12, cranial MRI showed multiple areas of cerebral infarction in brainstem and hemispheres. Transesophageal echocardiography was unremarkable. On day 18, he became



Cortical wedge-shaped infarct in case 4 (A, hematoxylin and eosin, magnification 20×). A single asterisk indicates normal brain parenchyma; a double asterisk indicates infarction. Perforating artery with subtotal stenosis caused by thrombus (B, hematoxylin and eosin, magnification 400×). Vessel wall shows no evidence of vasculitis.

comatose. A third lumbar puncture was performed; CSF cultures remained sterile. On day 25, supportive care was withdrawn and the patient died. Autopsy showed areas of granulocyte infiltration of brain parenchyma along the convexity and widespread areas of infarction and gliosis involving the cerebral hemispheres (figure 3A), brainstem, and cerebellum. Microscopically, vessel walls showed minor infiltration by granulocytes, thickening and fibrosis of the intima, but the main findings were thrombi inside vessel lumina, resulting in subtotal stenosis (figure 3B).

Case 5. A 30-year-old woman presented with fever, malaise, and headache. She had a temperature of 41 °C. Neurologic examination showed neck stiffness and disorientation, but was otherwise normal. Treatment with ceftriaxone and dexamethasone was started. A lumbar puncture yielded 2,000 leukocytes/mm³ (90% granulocytes), high protein, and low glucose levels. CSF gram stain showed gram-positive diplococci and culture of blood and CSF yielded *S pneumoniae*, sensitive to penicillin. The patient improved and was ready for discharge on day 12. However, on day 13, fever, headache, and neck pain recurred. A lumbar puncture revealed 1,100 leukocytes/mm³ and CSF gram stain showed no bacteria. Penicillin was restarted but cultures of blood and CSF remained sterile. Subsequently, she developed a hemiparesis and impaired level of consciousness. On day 17, cranial MRI showed multiple infarctions in the pons, right thalamus (figure 2D), and left corona radiata. Transesophageal echocardiography was unremarkable. Dexamethasone was restarted but no

clinical improvement occurred. On day 22, care was withdrawn and the patient died. No autopsy was performed.

Case 6. A 40-year-old man presented with fever, headache, and a decreased level of consciousness (GCS score E1M3V1). Cranial CT showed no abnormalities and lumbar puncture yielded 80 leukocytes/mm³ (90% granulocytes), high protein, and low glucose levels. CSF gram stain showed gram-positive diplococci and culture of blood and CSF yielded *S pneumoniae*, sensitive to penicillin. He was treated with penicillin and dexamethasone, made a good recovery, and was discharged on day 17. However, on day 19, he was readmitted because of fever and developed a coma within hours. Cranial CT showed a hypodense lesion in the left basal ganglia. Transesophageal echocardiography was unremarkable. Cranial MRI showed evidence of infarcts in the medulla oblongata and cerebellum bilaterally (figure 2E), and basal ganglia bilaterally (figure 2F). Reexamination of CSF was not performed. The patient was treated with prednisolone 30 mg twice daily. His condition stabilized and his level of consciousness slowly improved. On day 92, he was discharged to a rehabilitation facility. On discharge he had marked abulia and was wheelchair-bound. Currently, he uses a walker, but still has severe cognitive defects.

REVIEW OF THE LITERATURE PubMed was searched through May 2009 using search terms “meningitis,” “vasculitis,” “vasculopathy,” “stroke,” and “cerebral infarction” in the English, French, and

Table 2 Patients reported in the literature with delayed vasculopathy complicating bacterial meningitis

	Case 1 (1992)	Case 2 (2005)	Case 3 (2006)	Case 4 (2007)	Case 5 (2007)
Sex, age, y	M, 34	F, 20	M, 53	M, 19	M, 49
Causative organism	<i>S milleri</i>	<i>S pneumoniae</i>	<i>S pneumoniae</i>	<i>S aureus</i>	<i>S pneumoniae</i>
Dexamethasone	Yes	Unknown	No	No	Yes
Status after first week	Hemiparesis	Out of ICU	ICU: intubated, awake, hemiplegia	ICU: intubated, awake	ICU: intubated, awake
Secondary deterioration	Day 8: coma, fixed pupils	Day 9: 3rd nerve palsy, hemiparesis	Day 10: coma, hemiplegia	Day 5: 3rd nerve palsy, hemiparesis	Day 9: coma
CSF WBC on deterioration, cells/mm ³	NP	400	57	NP	NP
Repeat CSF culture	NP	Negative	Negative	NP	NP
Neuroimaging	Subarachnoid hemorrhage	Moyamoya syndrome, infarction hemispheres, brainstem	Infarction hemispheres, basal ganglia, brainstem	Infarction basal ganglia	Hemorrhagic infarction both hemispheres
Treatment	Supportive care	Dexamethasone	Methylprednisolone	Dexamethasone	Supportive care, antibiotics
Outcome	Death	Death (day 260)	Severe disability	Moderate disability	Death

ICU = intensive care unit; WBC = white blood cells; NP = not performed.

German language. We only included adult cases with secondary deterioration after 5 days. We did not evaluate cases with early deterioration and vasculitis or vasculopathy. Five patients were reported between 1992 and 2007 (table 2); age varied from 19 to 53 years.^{5-7,9,10} Four patients had streptococcal meningitis (*S pneumoniae* in 3, *S milleri* in 1); 1 patient had meningitis due to *Staphylococcus aureus*. Empirical treatment consisted of third-generation cephalosporin-based regimens in 4 patients and penicillin monotherapy in 1 patient. Two patients were initially treated with adjunctive dexamethasone therapy. All cases were admitted with severe illness. Secondary deterioration occurred after 5 to 9 days after admission. Importantly, at time of deterioration, 3 of 5 patients were severely ill and still admitted to the ICU. One patient was admitted to the ward and suddenly became unresponsive due to a subarachnoid hemorrhage. One patient developed gait impairment on day 9, while out of the ICU. It is unknown whether this patient initially received dexamethasone. She developed a vasculopathy resembling moyamoya syndrome. CSF examination was repeated in 2 patients; CSF leukocyte counts were up to 500 mm³ (65% to 74% neutrophils); CSF cultures remained sterile. Neuroimaging showed multiple areas of infarction in the posterior circulation territory in 4 patients; 1 patient also had infarction in the MCA territory. Three patients were treated with steroids after clinical deterioration occurred. Three patients died and the remaining 2 patients had poor outcomes. The patient with moyamoya syndrome died after 260 days. Autopsy revealed no systemic vasculitis or

arteriopathy. The proximal cerebral vasculature exhibited severe luminal narrowing. Autopsy of patient 1 showed an angi destructive inflammatory process in all wall layers; arteritis was a prominent feature. Interestingly, intracellular gram-positive cocci were present, indicating suboptimal antibiotic therapy. Both surviving patients were treated with high-dose steroids after clinical deterioration.

DISCUSSION We present 6 patients with delayed cerebral thrombosis complicating bacterial meningitis. All had pneumococcal meningitis and made a good or excellent recovery in the first week of admission. After 7 to 19 days they suddenly deteriorated and developed multiple infarctions primarily located in the posterior circulation territory. We have not come across similar reports describing this devastating phenomenon in patients with initial excellent recovery from bacterial meningitis. Autopsy showed thrombosis mainly involving penetrating arteries supplying the thalamus and brainstem, indicating an immunologic reaction specifically targeting cerebral blood vessels. There were no inflammatory cells in any of the vessel wall layers. These findings are consistent with cerebral thrombosis. We estimate that this complication occurs in approximately 1 out of 100 cases with pneumococcal meningitis.

Very few patients reported in the literature resemble our patients: we did not identify patients with a similar degree of initial recovery or severity of clinical deterioration. One case has been published with mild

secondary deterioration after initial recovery. This patient developed a moyamoya-like syndrome, most likely immune-mediated since symptoms reappeared after tapering immunosuppressive therapy. This patient died after cerebral hemorrhage more than 250 days after developing meningitis. Autopsy showed no vasculitis. It is unknown whether this patient was initially treated with dexamethasone.

We did not encounter cases with delayed cerebral thrombosis in our prospective nationwide cohort evaluating 696 cases with community-acquired bacterial meningitis (1998–2002, D. van de Beek).¹¹ This cohort study was performed in the period before routine use of adjunctive dexamethasone therapy. Adjunctive dexamethasone treatment has been shown to decrease mortality in community-acquired bacterial meningitis in adults in a randomized clinical trial and meta-analysis.^{12,13} In this trial, the effect on mortality was most apparent in the subgroup of patients with pneumococcal meningitis.¹² A post hoc analysis showed that mortality in this group was decreased by prevention of systemic complications rather than neurologic complications.¹³

In patients with bacterial meningitis, significant reduction in cerebrospinal white blood cell counts is usually found by day 3 of therapy and glucose levels usually return to normal more rapidly.¹⁴ In our case series, 3 out of 4 patients with repeated examination of CSF had no substantial reduction of white blood cell counts and 3 out of 5 patients had persisting low glucose levels. All had negative CSF cultures. This suggests a mechanism of persisting or recurrent inflammation without persistent bacterial infection.

Dexamethasone is a glucocorticoid, which has been shown to attenuate the inflammatory response and coagulation caused by the release of bacterial endotoxins in the acute phase of disease.¹⁵ An interesting parallel to that of thrombosis in bacterial meningitis is found in the field of renal transplantation. OKT3, an anti-CD3 monoclonal antibody used to prevent allograft rejection, is associated with a massive release of proinflammatory cytokines and carries an increased risk of intragraft thrombosis.¹⁶ Although few patients develop thrombosis after OKT3, those patients who had been pretreated with high-dose methylprednisolone had a significantly higher risk of thrombosis compared to those who had received lower doses of methylprednisolone. It has been suggested that high-dose glucocorticoids can tip the balance toward sustained coagulation and platelet aggregation by influencing the tissue factor/factor VII pathway.¹⁷ Another study showed that in subjects who were pretreated with glucocorticoids 12 to 144 hours before endotoxin exposure, signifi-

cantly higher levels of proinflammatory cytokines and coagulation were found.¹⁸

Dexamethasone stimulates macrophages by up-regulation of endocytic receptors and increases their phagocytic potential. In a recent in vitro study, macrophages stimulated by dexamethasone and interleukin-4 for 4 days were compared to those stimulated by interleukin-4 only. Stimulation by dexamethasone enhanced the surface expression of transforming growth factor beta receptor II (TGF- β RII) in a time-dependent manner by 700% over 4 days.¹⁹ TGF- β plays an important role in the development of cerebral necrotizing vasculitis in pneumococcal meningitis. Deletion of the TGF- β RII gene in polymorphonuclear leukocytes enhances polymorphonuclear leukocytes recruitment into the CNS of mice with *S pneumoniae* meningitis. This was associated with more efficient clearance of bacteria, and almost complete prevention of cerebral necrotizing vasculitis.²⁰ An additional explanation could be a rebound effect of the primary inflammatory reaction initially suppressed by dexamethasone. Adjunctive dexamethasone may not cause deterioration but merely delays it.

All our patients were initially treated with adjunctive dexamethasone therapy, suggesting an association with this newly introduced adjunctive therapy in bacterial meningitis. Nevertheless, a causal relation between delayed cerebral thrombosis and dexamethasone remains difficult to establish. Delayed cerebral thrombosis may occur in patients with pneumococcal meningitis irrespective of steroid therapy.

The outcome of delayed cerebral thrombosis in our patients was devastating. Four patients died and 2 remained disabled. Combining our patients and those reported, all who survived received prolonged treatment with high-dose steroids. This supports the hypothesis of an immunologic basis of this disease. Patients with bacterial meningitis with clinical deterioration after initial improvement should undergo further investigations without delay, including MRI, and repeated CSF examination. If delayed cerebral thrombosis is suspected, immediate high-dose steroids should be started. These patients typically have multiple infarctions on MRI, predominantly in the posterior circulation territory. Lumbar puncture may reveal substantially elevated leukocyte counts. Although no relapse of bacterial meningitis was proven in our cases, antibiotic therapy should be prolonged or restarted until CSF cultures remain negative. Once cerebral infarctions have been demonstrated by MRI, a cardioembolic cause should be ruled out by echocardiography, since bacterial meningitis and endocarditis may coexist.²¹ Tapering of steroids may lead to new clinical deterioration. Although based on

speculation, we suggest prompt reinitiation of immunosuppressive therapy. Future case series are needed to determine whether this will improve the outcome of this devastating complication.

ACKNOWLEDGMENT

The authors thank the following physicians for referring patients and sharing clinical information on the patients presented in this article: Dr. H.P. Bienfait, neurologist, Gelre Hospital, Apeldoorn, the Netherlands; Dr. A.E. Bollen, neurologist, Wilhelmina Hospital, Assen, the Netherlands; Dr. M. Hanse, neurologist, Catharina Hospital, Eindhoven, the Netherlands; Dr. A.C. Kappelle, neurologist, University Medical Center Nijmegen, Nijmegen, the Netherlands; and Dr. H.T.J. Niekus, neurologist, Reinier de Graaf Gasthuis, Delft, the Netherlands. The authors also thank Dr. N. Lefebvre, Department of Infectious Diseases, University Hospital of Strassbourg, Strassbourg, France, and Dr. K. Becker, Department of Neurology, Harborview Medical Center, Seattle, WA, for sharing additional clinical information on the patients they described in their case reports.

Received June 18, 2009. Accepted in final form August 18, 2009.

REFERENCES

1. Pfister HW, Borasio GD, Dirnagl U, Bauer M, Einhaupl KM. Cerebrovascular complications of bacterial meningitis in adults. *Neurology* 1992;42:1497–1504.
2. van de Beek D, de Gans J, Tunkel AR, Wijdicks EF. Community-acquired bacterial meningitis in adults. *N Engl J Med* 2006;354:44–53.
3. Kastenbauer S, Pfister HW. Pneumococcal meningitis in adults: spectrum of complications and prognostic factors in a series of 87 cases. *Brain* 2003;126:1015–1025.
4. Weisfelt M, de Gans J, van der Poll T, van de Beek D. Pneumococcal meningitis in adults: new approaches to management and prevention. *Lancet Neurol* 2006;5:332–342.
5. Bentley P, Qadri F, Wild EJ, Hirsch NP, Howard RS. Vasculitic presentation of staphylococcal meningitis. *Arch Neurol* 2007;64:1788–1789.
6. Czartoski T, Hallam D, Lacy JM, Chun MR, Becker K. Postinfectious vasculopathy with evolution to moyamoya syndrome. *J Neurol Neurosurg Psychiatry* 2005;76:256–259.
7. Lefebvre N, Carre AC, Delabranche X, Guiot P, Mootien Y. [Implication of dexamethasone adjunctive therapy after the onset of cerebral vasculitis in *Streptococcus pneumoniae* meningitis.] *Med Mal Infect* 2007;37:118–120.
8. Palacio S, Hart RG, Vollmer DG, Kagan-Hallet K. Late-developing cerebral arteriopathy after pyogenic meningitis. *Arch Neurol* 2003;60:431–433.
9. Pugin D, Copin JC, Goodyear MC, Landis T, Gasche Y. Persisting vasculitis after pneumococcal meningitis. *Neurocrit Care* 2006;4:237–240.
10. Perry JR, Bilbao JM, Gray T. Fatal basilar vasculopathy complicating bacterial meningitis. *Stroke* 1992;23:1175–1178.
11. van de Beek D, de Gans J, Spanjaard L, Weisfelt M, Reitsma JB, Vermeulen M. Clinical features and prognostic factors in adults with bacterial meningitis. *N Engl J Med* 2004;351:1849–1859.
12. de Gans J, van de Beek D. Dexamethasone in adults with bacterial meningitis. *N Engl J Med* 2002;347:1549–1556.
13. van de Beek D, de Gans J, McIntyre P, Prasad K. Steroids in adults with acute bacterial meningitis: a systematic review. *Lancet Infect Dis* 2004;4:139–143.
14. Fishman RA. *Cerebrospinal Fluid in Diseases of the Nervous System*, 2nd ed. Philadelphia: Saunders; 1992.
15. van der Poll T. Coagulation and inflammation. *J Endotoxin Res* 2001;7:301–304.
16. Abramowicz D, Pradier O, Marchant A, et al. Induction of thromboses within renal grafts by high-dose prophylactic OKT3. *Lancet* 1992;339:777–778.
17. Abramowicz D, Pradier O, de Pauw L, et al. High-dose glucocorticosteroids increase the procoagulant effects of OKT3. *Kidney Int* 1994;46:1596–1602.
18. Barber AE, Coyle SM, Marano MA, et al. Glucocorticoid therapy alters hormonal and cytokine responses to endotoxin in man. *J Immunol* 1993;150:1999–2006.
19. Gratchev A, Kzhyshkowska J, Kannookadan S, et al. Activation of a TGF-beta-specific multistep gene expression program in mature macrophages requires glucocorticoid-mediated surface expression of TGF-beta receptor II. *J Immunol* 2008;180:6553–6565.
20. Malipiero U, Koedel U, Pfister HW, et al. TGFbeta receptor II gene deletion in leucocytes prevents cerebral vasculitis in bacterial meningitis. *Brain* 2006;129:2404–2415.
21. Salgado AV. Central nervous system complications of infective endocarditis. *Stroke* 1991;22:1461–1463.

Neurology®

Delayed cerebral thrombosis after initial good recovery from pneumococcal meningitis

E. S. Schut, M. C. Brouwer, J. de Gans, et al.

Neurology 2009;73;1988-1995 Published Online before print November 4, 2009

DOI 10.1212/WNL.0b013e3181c55d2e

This information is current as of November 4, 2009

Updated Information & Services

including high resolution figures, can be found at:
<http://www.neurology.org/content/73/23/1988.full.html>

References

This article cites 20 articles, 8 of which you can access for free at:
<http://www.neurology.org/content/73/23/1988.full.html##ref-list-1>

Citations

This article has been cited by 6 HighWire-hosted articles:
<http://www.neurology.org/content/73/23/1988.full.html##otherarticles>

Subspecialty Collections

This article, along with others on similar topics, appears in the following collection(s):

All Immunology

http://www.neurology.org/cgi/collection/all_immunology

Infarction

<http://www.neurology.org/cgi/collection/infarction>

Meningitis

<http://www.neurology.org/cgi/collection/meningitis>

MRI

<http://www.neurology.org/cgi/collection/mri>

Permissions & Licensing

Information about reproducing this article in parts (figures, tables) or in its entirety can be found online at:

<http://www.neurology.org/misc/about.xhtml#permissions>

Reprints

Information about ordering reprints can be found online:

<http://www.neurology.org/misc/addir.xhtml#reprintsus>

Neurology® is the official journal of the American Academy of Neurology. Published continuously since 1951, it is now a weekly with 48 issues per year. Copyright . All rights reserved. Print ISSN: 0028-3878. Online ISSN: 1526-632X.

