

Is Postoperative CT Scanning Predictive of Subdural Electrode Placement Complications in Pediatric Epileptic Patients?

Carlo Giussani^{a,c} Tanya Filardi^a Krishnapundha Bunyaratavej^{a,d}
Jeffrey C. Mai^a Masahiro Ogino^{a,e} Stephanie Greene^{a,b} Samuel R. Browd^a
Anthony M. Avellino^a Richard G. Ellenbogen^a Jeffrey G. Ojemann^a

^aDepartment of Neurological Surgery, Seattle Children's Hospital, University of Washington School of Medicine, Seattle, Wash., and ^bNeurosurgery, University of Pittsburgh, Pittsburgh, Pa., USA; ^cNeurochirurgia, Dipartimento di Neuroscienze e Tecnologie Biomediche, Università degli Studi Milano-Bicocca, Ospedale San Gerardo, Monza, Italia; ^dDivision of Neurosurgery, Department of Surgery, Chulalongkorn University, Bangkok, Thailand; ^eDepartment of Neurosurgery, Dokkyo University School of Medicine, Tochigi, Japan

Key Words

Intractable seizures · Subdural electrodes · Hemorrhagic complications · Midline shift

Abstract

Aims: To understand the reliability of postoperative CT scans to predict the development of intracranial hemorrhagic complications associated with subdural electrode implants for monitoring intractable seizure, we reviewed the data of a consecutive series of children treated at our institution.

Methods: Forty children (mean age: 11.4 years) with subdural electrode implants were reviewed. The immediate postoperative CT scans were evaluated for the presence of hemorrhagic complications and/or brain swelling resulting in a midline shift. **Results:** Twenty-six patients (65%) presented a postoperative midline shift (range = 2–10 mm; mean shift = 4.0 mm). Two children had a midline shift of >5 mm. Two patients with a shift of <5 mm at the first CT scan required a repeat craniotomy. These patients experienced worsening neurologic symptoms in a delayed fashion on postoperative

days 1 and 4, respectively. This was correlated to an increase in midline shift of >5 mm. **Conclusions:** Subdural electrode implants in children are safe. The presence of a midline shift of <5 mm is common postoperatively. The presence and extension of the midline shift at the first CT scan does not seem to be predictive of the development of symptomatic complications with a mass effect. Complications happened in a delayed fashion.

Copyright © 2009 S. Karger AG, Basel

Introduction

The efficacy of epilepsy surgery depends on the capability to demarcate the epileptic zone that is defined as 'the area necessary and sufficient for initiating seizures

The authors dedicate this report to the memory of Dr. Ted Roberts who directly cared for many of the patients in this series. His vision and dedication remain an inspiration to all of us.

and whose removal or disconnection is necessary for abolition of seizures' [1]. Although scalp EEG, along with other neuroimaging techniques, helps to effectively identify the general area of a seizure focus [2, 3], invasive techniques have proven to be a far superior method for accurate localization [4]. Unfortunately, several reports described complications related to the placement of subdural electrodes both in the adult and in the pediatric population [5–14]. Frequently, reported complications include infection of the wound and bone flap (2–15%), CSF leaks through the skin insertion sites of the electrode cables (30%) and formation of acute symptomatic epidural (1.8–2.5%) and, particularly, subdural hematomas (2–14%) along with symptomatic brain swelling (8%) [5–14]. While the implantation of subdural electrodes is generally a safe procedure in children with a low rate of clinically relevant hemorrhagic complications [10–13], the development of acute hemorrhagic complications and brain swelling can be life-threatening conditions that present mostly in the immediate postoperative period. The performance of postoperative CT scanning after craniotomies for subdural grid implants has become routine. The majority of patients with implanted subdural electrodes develop postoperative subacute extra-axial collections (EAC) with a common midline shift. EAC are composed of serosanguinous fluid and CSF. It has been hypothesized that the electrodes may slide over the cerebral cortex, especially during seizures, and damage bridging veins [8]. However, EAC are regularly seen on CT scans performed in the early postoperative time period before any seizures develop. Another possible explanation is that the implanted electrodes do not completely conform to the shape of the brain surface, creating spaces between the electrodes and the dura, and between the dura and the cranium, in which CSF or blood products can collect [15]. Even if the usual nature of EAC is benign, the formation of delayed intracranial hemorrhagic complications and/or brain swelling has been reported [8, 9]. Mocco et al. [15] demonstrated in a patient population composed mainly of adults that there is no significant radiographic difference between symptomatic and asymptomatic EAC. Therefore, the authors concluded that 'the presence of an EAC is not a specific indication ... for decompression'.

To understand the correlation between EAC, midline shift and clinically evident complications after the implantation of subdural electrodes, along with the safety of this invasive diagnostic technique in pediatric patients, we reviewed the radiological and clinical postoperative data of a consecutive group of children with intractable epilepsy treated at our institution.

Material and Methods

Patient Population

From October 1997 to May 2004, 40 consecutive patients with intractable epilepsy underwent a craniotomy for the placement of subdural electrodes (subdural grids and subdural strips). All the patients underwent the placement of a combination of subdural grids and strips. All the patients who had been submitted to the placement of subdural strips by the use of simple burr holes without craniotomy were excluded from the analysis.

The patient population age ranged from 2 to 17 years (mean age at the time of surgery was 11.4 years). In our series there were 21 males and 19 females.

Surgical Technique

The aim of our subdural electrode implant is to cover the cerebral cortex with grids and strips as completely as possible, including the lateral, basal and medial surface of the brain. To achieve this goal, we usually perform a large frontotemporoparietal craniotomy, recently with an osteoplastic bone flap, leaving the bone flap attached to the temporal muscle. Our aim is to decrease the risk of infection and resorption of the bone flap by maintaining intact the vascularization coming from the deep temporalis fascia. In fact, as previously reported by our team, the risk of cranial bone resorption after a decompressive craniotomy in children is very high, reaching 50% of cases [16].

The dura is opened, and several grids and strips are positioned to cover the cortical surface. In particular, subtemporal, orbitofrontal and interhemispheric strips are always placed along with a 64-electrode convexity grid. We secure the convexity grid to the dura with a suture to reduce the risk of the grid sliding over the surface of the brain in case of seizures. After adequate hemostasis has been obtained, we perform a watertight closure of the dura. The bone flap is secured to the edges of the craniotomy with a single-point fixation by the use of 1 plate with screws. In this way the pressure of the bone flap on the brain covered by the grids is reduced, at the same time avoiding that the bone flap floats over the dura. In the experience of our group, it is important to resecure the bone flap to avoid the patients injuring themselves in case of seizures. Nonetheless, we try to reduce the mass effect produced by the grids using a single-point fixation with a single straight plate in order to allow the bone flap to be slightly displaced in case of EAC with mass effect. A musculocutaneous closure is performed in multiple layers to reduce the risk of CSF leaking through the skin and around the exit sites of the electrode cables. In fact, CSF leaks around electrode exit sites have been proposed as one of the possible mechanisms of subdural hematoma development [8].

The leads are usually continuously connected to an EEG monitoring device in the intensive care unit immediately after a full recovery from anesthesia to the baseline neurologic condition. The patients spend the first 12–24 h in the intensive care unit.

Postoperative CT Scan Review

The postoperative CT scans of the patients were reviewed to evaluate the development of postoperative complications. At our institution, all the patients undergoing craniotomies are submitted to a postoperative CT scan within 1 h of the completion of surgery to check for the presence of acute epidural, subdural or intraparenchymal hemorrhagic complications. In the case of craniotomies for

subdural electrode placement, we look for complications of iatrogenic origin, for instance the damage to a midline or base-of-skull bridging vein during the positioning of the electrodes.

Attention was paid during the review to the development of postoperative hemorrhagic complications and/or brain swelling. In particular, all the immediate postoperative CT scans were reviewed, evaluating the presence of EAC, epidural and subdural hematomas, or brain swelling causing a midline shift. A midline shift of >5 mm was considered significant [17–19], but managed conservatively if asymptomatic.

Results

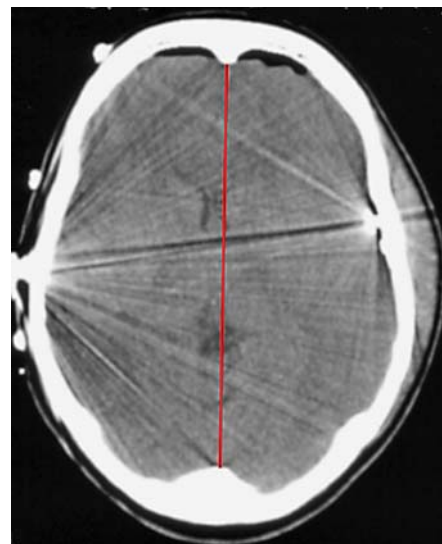
Forty consecutive patients were reviewed. A midline shift was recognizable in 26 patients. In these patients, the midline shift ranged from 2 to 10 mm with a mean midline shift of 4.0 mm. Only 2 patients showed a midline shift of >5 mm (6 and 10 mm). They did not require a revision surgery due to the absence of related symptoms (fig. 1). If the 14 patients with no shift are considered as well, the median shift was 2 mm.

Of the 24 patients with a recognizable midline shift of <5 mm, 2 patients required repeat craniotomy due to the development of increased subdural fluid collections/hemorrhage, with a progressive shift to >5 mm and symptoms of increased intracranial pressure. In both cases, the patients developed worsening neurologic symptoms in a delayed fashion (after 1 and 4 days, respectively). Both patients underwent evacuation of the collection: 1 patient with a reimplantation of the electrodes and 1 with a definitive epilepsy surgery. They both recovered completely.

The 2 symptomatic cases that required a postimplant revision surgery will be discussed.

Case 1

The first case was a 13-year-old boy with a history of intractable partial seizures since he was 18 months old. The first CT scan after the right subdural electrode implant showed the presence of right EAC with a maximal thickness of 8 mm and a midline shift of 4 mm (fig. 2a). However, on postoperative day 4, the patient developed a severe headache with worsening lethargy. A new CT scan showed an acute subdural hematoma with a maximal thickness of 15 mm and a midline shift of 7 mm (fig. 2b). Due to the worsening of the headache, the patient underwent a new operation through the same skin incision and bone flap. Under the dura that was reopened using the same incision, an organized subdural hematoma was evacuated. The brain was soft and pulsating after the he-



Color version available online

Fig. 1. Initial postoperative CT scan of a patient with left subdural electrodes, demonstrating a midline shift of >5 mm. This patient was neurologically intact and did not require a reoperation.

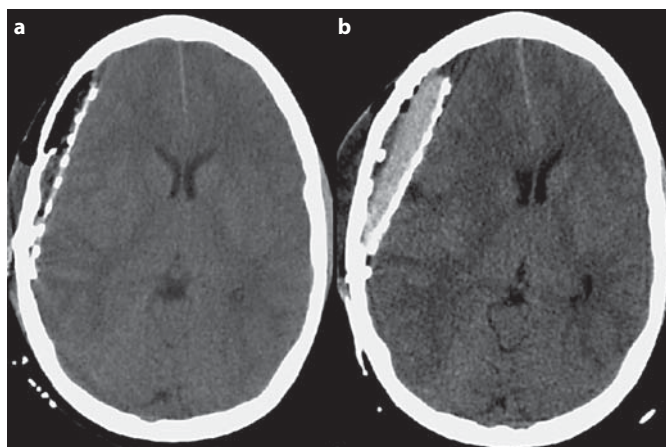


Fig. 2. a Initial postoperative CT scan of a 13-year-old male with intractable partial seizures who underwent right subdural electrode implantation. It demonstrates the presence of right EAC with a maximal thickness of 8 mm and a midline shift of 4 mm. **b** Repeat postoperative CT scan performed on day 4 after surgery due to the development of a worsening headache and lethargy. It shows an acute subdural hematoma with a maximal thickness of 15 mm and a midline shift of 7 mm that required a reoperation.

matoma evacuation. The patient did not receive a new electrode implant even though the monitoring had not been a contributory factor. He directly underwent definitive epilepsy surgery based on MRI anatomical data and on previous EEG data.

Case 2

The second case was a 17-year-old boy with a history of intractable complex partial seizures with secondary generalization who had previously undergone a partial right frontal lobectomy for intractable seizures. His seizures recurred, and grids, strips and depth electrodes were implanted. He developed a worsening headache on postoperative day 1. The first CT scan after surgery showed the presence of right frontal EAC with a maximal thickness of 6 mm near the midline border of the craniotomy and a midline shift of 4 mm with no related symptoms. A new CT scan performed the following day showed the presence of a minimal evolution of the EAC that measured a maximum of 8 mm with a midline shift of 6 mm. The second CT scan did not show a new acute subdural hematoma, but there was an increase in serosanguinous fluid over the grids. Due to the worsening of the headache and the development of lethargy, the patient underwent repeat craniotomy through the same skin incision and bone flap. Under the dura that was reopened using the same incision, a fluid serosanguinous collection was rapidly evacuated. The brain was soft and pulsating after the evacuation of the serosanguinous collection. The electrodes were replaced due to the lack of conclusive electrocorticographic data. He underwent definitive epilepsy surgery after 1 week of monitoring.

In both cases requiring reoperations, it was not possible to find a clear source of the bleeding during the revision surgery.

Discussion

The need to submit a pediatric patient with intractable epilepsy to an invasive monitoring procedure by the use of subdural electrodes requires a careful balance of the risks and benefits [5–14].

The review of the pediatric patients with intractable epilepsy who underwent placement of subdural electrodes at our hospital for invasive monitoring demonstrated that it is common to see a midline shift of <5 mm on an immediate postoperative CT scan. The majority of our pediatric patients (26) presented at the first postoperative CT scan a midline shift of <5 mm with a mean of 4 mm. Nevertheless, only 2 patients out of 40 required a revision craniotomy due to the development of neurologic symptoms in the postoperative period.

Our findings are in agreement with other studies conducted on pediatric patients demonstrating that the placement of subdural grids and strips performed via cra-

niotomy is generally a safe procedure in children with intractable epilepsy who require invasive seizure monitoring [10–13]. One explanation advocated for the relative safety of subdural electrode implants in pediatric patients is the greater plasticity of pediatric brain parenchyma and vascular structures compared to adults [13].

The 2 patients who required a revision surgery both presented with a midline shift of <5 mm at the first postoperative CT scan. Neither patient in the present series with an initial shift of >5 mm (6 and 10 mm, respectively) developed related postoperative symptoms. These 2 opposite findings suggest that the presence of a postoperative midline shift as well as its extent are not predictive of the development of symptomatic hemorrhagic complications with a mass effect. In agreement with other authors [15], we think that signs of EAC with a mass effect are commonly seen on the first postoperative CT scan and, by themselves, do not represent a concern.

The 2 cases that were complicated by the development of voluminous EAC and subdural hematoma developed symptoms related to increased intracranial pressure in a delayed fashion 1 day and 4 days after the subdural electrode implants, respectively. As previously reported, this timing pattern could be related to the slow and continuous CSF leakage around the electrode exit sites. The leaking could lead to a unilateral alteration of the CSF dynamic and the production of an ex vacuo shift toward the side of the subdural electrode with subsequent brain shift and tearing of bridging veins [8, 14]. The leakage of CSF through the cable exit sites is a well-known event related to subdural electrode implants [8, 14], with an occurrence rate of 30% in pediatric patients [13]. Nevertheless, other factors likely play a role in symptomatic extra-axial hemorrhagic complications, given the low rate of reoperations [10–13].

Conclusion

The present series reviews pediatric patients who underwent placement of subdural electrodes for seizure monitoring. Subdural electrode implants performed in children by craniotomy are a safe procedure. The operation is characterized by a low percentage of symptomatic hemorrhagic complications that usually present in a delayed fashion. It is a common finding at the initial postoperative CT scan to see a midline shift of <5 mm with EAC; importantly, the presence and the extent of the midline shift at the initial CT scan are not predictive of the development of delayed complications.

References

- 1 Luders HO, Engel J Jr, Munari C: General principles; in Engel J Jr (ed): *Surgical Treatment of the Epilepsies*, ed 2. New York, Raven Press, 1993, pp 137–153.
- 2 Won HJ, Chang KH, Cheon JE, Kim HD, Lee DS, Han MH, Kim IO, Lee SK, Chung CK: Comparison of MR imaging with PET and ictal SPECT in 118 patients with intractable epilepsy. *AJNR Am J Neuroradiol* 1999;20:593–599.
- 3 Lee DS, Lee SK, Lee MC: Functional neuroimaging in epilepsy: FDG PET and ictal SPECT. *J Korean Med Sci* 2001;16:689–696.
- 4 Jayakar P, Duchowny M, Resnick TJ: Subdural monitoring in the evaluation of children for epilepsy surgery. *J Child Neurol* 1994;9(suppl 2):61–66.
- 5 Wiggins GC, Elisevich K, Smith BJ: Morbidity and infection in combined subdural grid and strip electrode investigation for intractable epilepsy. *Epilepsy Res* 1999;37:73–80.
- 6 Zaccariotti VA, Pannek HW, Holthausen H, Oppel F: Evaluation with subdural plates in children and adolescents. *Neurol Res* 1999;21:463–474.
- 7 Bruce DA, Bizzi JW: Surgical technique for the insertion of grids and strips for invasive monitoring in children with intractable epilepsy. *Childs Nerv Syst* 2000;16:724–730.
- 8 Lee WS, Lee JK, Lee SA, Kang JK, Ko TS: Complications and results of subdural grid electrode implantation in epilepsy surgery. *Surg Neurol* 2000;54:346–351.
- 9 Hamer HM, Morris HH, Mascha EJ, Karafa MT, Bingaman WE, Bej MD, Burgess RC, Dinner DS, Foldvary NR, Hahn JF, Kotagal P, Najm I, Wyllie E, Lüders HO: Complications of invasive video-EEG monitoring with subdural grid electrodes. *Neurology* 2002;58:97–103.
- 10 Onal C, Otsubo H, Araki T, Chitoku S, Ochi A, Weiss S, Elliott I, Snead OC 3rd, Rutka JT, Logan W: Complications of invasive subdural grid monitoring in children with epilepsy. *J Neurosurg* 2003;98:1017–1026.
- 11 Simon SL, Telfeian A, Duhaime AC: Complications of invasive monitoring used in intractable pediatric epilepsy. *Pediatr Neurosurg* 2003;38:47–52.
- 12 Johnston JM Jr, Mangano FT, Ojemann JG, Park TS, Trevathan E, Smyth MDJ: Complications of invasive subdural electrode monitoring at St. Louis Children's Hospital, 1994–2005. *Neurosurgery* 2006;105:343–347.
- 13 Musleh W, Yassari R, Hecox K, Kohrman M, Chico M, Frim D: Low incidence of subdural grid-related complications in prolonged pediatric EEG monitoring. *Pediatr Neurosurg* 2006;42:284–287.
- 14 Fountas KN, Smith JR: Subdural electrode-associated complications: a 20-year experience. *Stereotact Funct Neurosurg* 2007;85:264–272.
- 15 Mocco J, Komotar RJ, Ladouceur AK, Zacharia BE, Goodman RR, McKhann GM 2nd: Radiographic characteristics fail to predict clinical course after subdural electrode placement. *Neurosurgery* 2006;58:120–125.
- 16 Grant GA, Jolley M, Ellenbogen RG, Roberts TS, Gruss JR, Loeser JD: Failure of autologous bone-assisted cranioplasty following decompressive craniectomy in children and adolescents. *J Neurosurg* 2004;100:163–168.
- 17 Marshall LF, Marshall SB, Klauber MR, Clark MvB, Eisenberg HM, Jane JA, Luerssen TG, Marmarou A, Foulkes MA: A new classification of head injury based on computerized tomography. *J Neurosurg* 1991;75(suppl):S14–S20.
- 18 Marshall LF, Marshall SB, Klauber MR, van Berkum Clark M, Eisenberg H, Jane JA, Luerssen TG, Marmarou A, Foulkes MA: The diagnosis of head injury requires a classification based on computed axial tomography. *J Neurotrauma* 1992;9:287–292.
- 19 Yuh EL, Gean AD, Manley GT, Callen AL, Wintermark M: Computer-aided assessment of head computed tomography (CT) studies in patients with suspected traumatic brain injury. *J Neurotrauma* 2008;25:1163–1172.

Copyright: S. Karger AG, Basel 2009. Reproduced with the permission of S. Karger AG, Basel. Further reproduction or distribution (electronic or otherwise) is prohibited without permission from the copyright holder.